

Use of a 970 nm laser for removal of a retromolar mucous membrane change

Prof. Dr Andreas Braun
Dr Matthias Johannes Roggendorf
Prof. Dr Roland Frankenberger

ABSTRACT

Depending on the laser parameter setting, a 970 nm diode laser can be used for coagulating cutting and the removal of oral soft tissue. This procedure is ascribed as offering an essentially blood-free surgical area and reducing the bacteremia risk. In this case report, the excision of a retromolar mucous membrane change, the subsequent healing process and the histological assessment of the removed tissue are described. The histological findings of the removed tissue were consistent with an irritation fibroma. The healing process was without irritation, discomfort and pronounced pain sensations for the patient. The blood-free working area allows the practitioner to work in a carefully controlled manner when removing mucous membrane changes without compromising the histological preparation of the tissue. This treatment method is very well accepted by patients as a suture is not required and there are virtually no post-treatment complaints.

KEYWORDS

Diode laser, 970 nm, mucous membrane, irritation fibroma, excision, pathology

Introduction

Dental laser systems are currently used for a wide range of different treatment methods. These include the surgical removal of pathologically changed tissue¹, the incision of soft tissue, biopsies and gingivectomies², frenectomies³ as well as various periodontal treatment techniques.⁴ The use of lasers is also described for the processing of dental hard tissue⁵ and, indeed, laser treatments are ascribed as being almost painless as the mechanical vibrations associated with conventional treatment methods do not occur.⁶ Depending on the laser type and the laser parameters set, the systems (e.g., CO₂

laser, Nd:YAG laser, diode laser) can be used for coagulating cutting or the removal of oral soft tissue.⁷ Such techniques are ascribed as offering an essentially blood-free surgical area and reducing the bacterial colonization of periodontal lesions.^{8,9} In this context, the bacteremia risk can also be reduced with the following treatment steps. As a rule, the antimicrobial effect of laser energy can be achieved athermally (e.g., as part of photodynamic treatment) or thermally. The antimicrobial properties of laser systems such as the diode laser are principally based on thermal effects. A 980 nm laser is ascribed as having an antibacterial effect which can be demonstrated into the depths of dental hard tissue.¹⁰

Case report

On March 6, 2013, a 48-year-old female patient presented at the Medical Center for Dental, Oral and Maxillofacial Sciences with a lentil-sized retromolar mucous membrane change in the palatoglossal arch region. The change was noted for the first time a few weeks before. After visiting her standard dentist, a suspected irritation fibroma was diagnosed and photo documentation was made in order to record any changes in the size and surface structure and also the reaction of the adjacent tissue. Although there were no discernible changes over the two-week monitoring period, the patient still expressed the wish to have the tissue removed. The patient stressed that she was very sensitive to pain and was afraid of the possibility of postoperative hemorrhaging following the surgical removal of the tissue. In order to accommodate the patient's concerns, in addition to conventional removal with a blade and subsequent suture, the use of a laser system was



Fig. 1: SIROLaser Advance 970 nm diode laser. Laser parameters for various treatment stages can be selected from presets and can also be individually adjusted.



Fig. 2: Patient wearing eye protection prior to the start of treatment. The laser protective glasses cover the operating wavelength range of 970 nm.

also offered. With this treatment method it could be assumed that a suture would not be necessary given the coagulating effect of the laser. Moreover, based on experience to date in connection with the use of lasers on patients, only very little to no sensation of pain has been reported. The SIROLaser Advance (Sirona, Bensheim, Germany), a 970 nm Class IV diode laser, with software version 2.0.6 was used for removal of the newly formed tissue. For the excision of tissue, for example the excision of a fibroma, a setting of 6W with pulse frequency (PF), a duty cycle of 50% and a frequency of 10 Hz are recommended by the manufacturer. As in this case there was no reliable diagnosis and the subsequently planned histological examination of the removed tissue was not to be impaired by heat necrosis, the presetting "Gingivectomy" was selected

which specifies a setting of 3W in CW and a resulting duty cycle of 100%. The handpiece was used with a 200 μ m (core diameter) fiber and was activated via the finger switch. As there were nothing of note in the patient's general medical history, Ultracain D-S 1:200 000 (Sanofi-Aventis, Frankfurt/Main, Germany) was used as the local anesthetic and, in total, 1.2 ml was infiltrated around the tissue to be removed. Following inspection of the anesthetic using a sharp probe in the surgical area, the patient and surgical team all put on protective glasses suitable for a wavelength of 970 nm. The treatment room was designated as a laser workplace from the outside. In addition, a warning light was activated which was located at the entrance door to the treatment area. The tissue to be removed was then excised after being grasped using surgical forceps. The fiber was guided circularly and vertically around and into the depths of the tissue. By pulling gently with the surgical forceps, it was possible to separate the tissue horizontally at a depth. Given the coagulating effect of the laser, there was no acute bleeding which would have required a suture. The wound area was rinsed with physiological saline solution to clean and moisten the treated tissue. The removed tissue was transferred to a prepared vessel with formalin and sent directly to the Institute for Pathology at the Gießen and Marburg University Hospital, Marburg, Germany, for histological examination. The wound area was covered with Solcoseryl Dental Adhesive Paste (Valeant Pharmaceuticals, Bad Homburg, Germany). The patient was advised to protect the surgical area as far as possible. Furthermore, she was also given the option of taking a

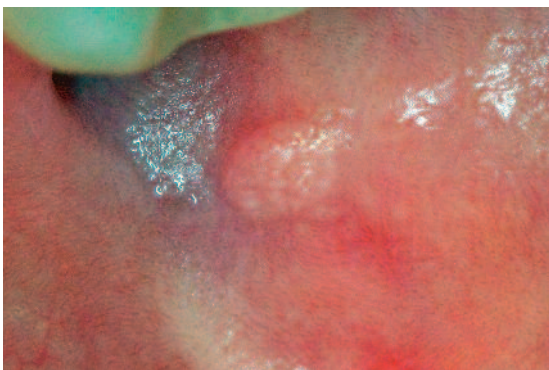


Fig. 3: Initial situation prior to the surgical intervention. Lenticular-sized retromolar mucous membrane change in the palatoglossal arch.

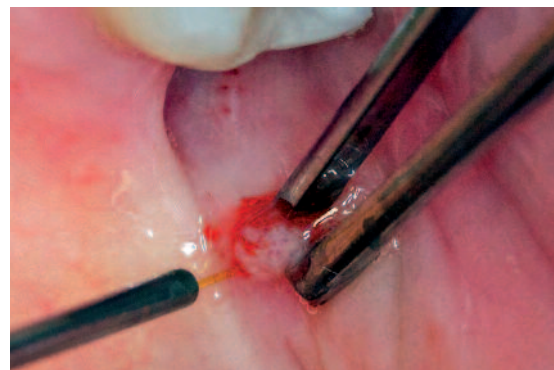


Fig. 4: Fixation of the tissue to be removed using surgical forceps and positioning of the approach at the base of the tissue change.

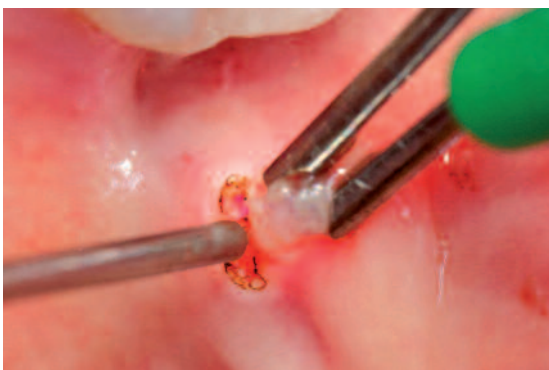

Fig. 5: Incision vertically to the tissue surface with the tissue change grasped using forceps.

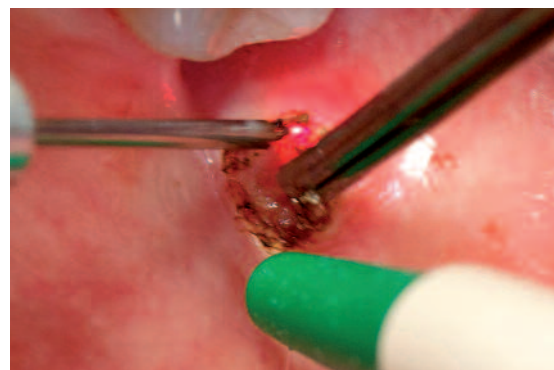

Fig. 6: Incision which runs horizontally to the tissue surface with the working fiber for complete excision of the changed tissue.

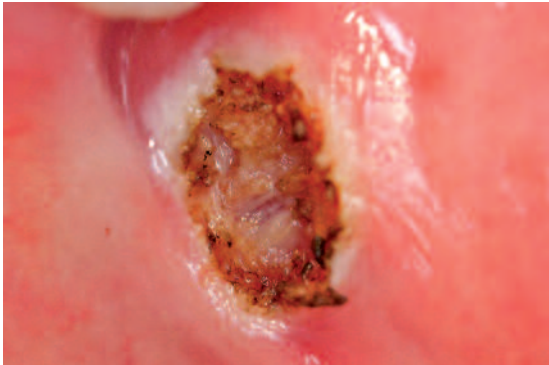


Fig. 7: Postoperative situation following complete excision of the tissue change. Thanks to the coagulating effect of the laser, no acute bleeding can be seen.

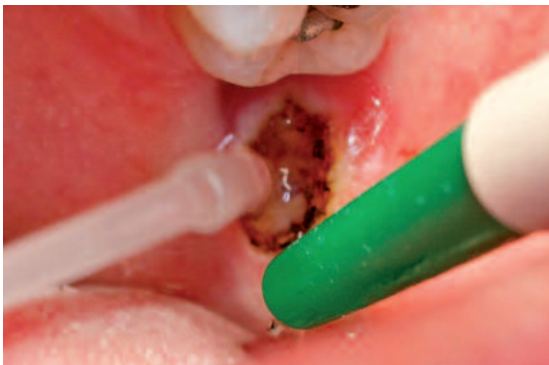

Fig. 8: Rinsing of the surgical area using physiological saline solution to clean and moisten the treated tissue.

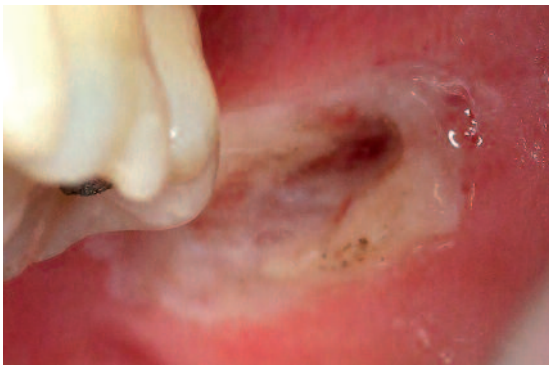

Fig. 9: Inspection of the wound two days after the intervention. Irritation-free wound area with the expected fibrin coating. No signs of postoperative hemorrhaging in the area from which the tissue was removed.

pain tablet should she experience pain once the anesthetic had worn off. She was told, as far as possible, to avoid eating whilst the anesthetic was still effective in order to prevent unchecked biting into the oral mucosa. The patient was requested to return for routine wound checks two and nine days after the intervention. This allowed an irritation-free wound area with the expected fibrin coating to be recorded. In the area from which the tissue had been removed, the patient could feel a discernible recess which did not impede the intake of food. There was no postoperative hemorrhaging and this was also not observed by the patient. The findings report issued by the Institute for Pathology describes the tissue removed following HE (hematoxylin-eosin) and PAS (periodic

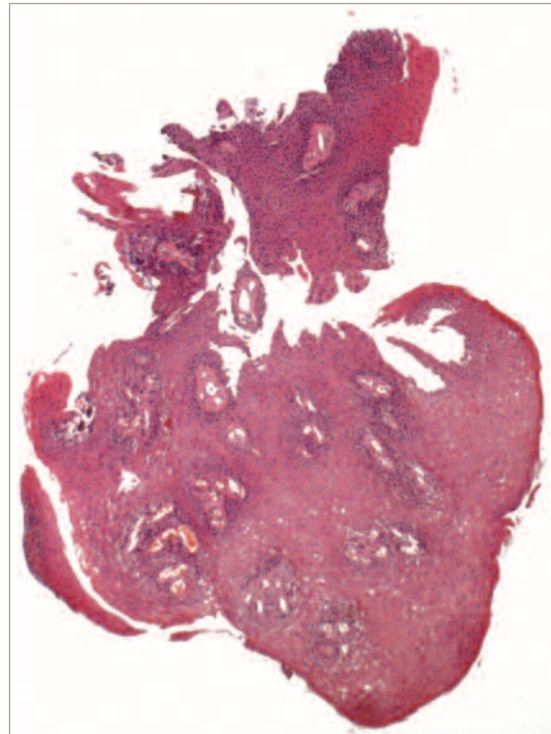

Fig. 10: Histological preparation of the tissue change. Tumor-free oral mucosa with the general findings of an irritation fibroma (original magnification 1 : 80).

acid-Schiff) staining: Tumor-free oral mucosa with slight epithelial hyperplasia and focal mild parakeratosis, fiber-increased stroma, normal mucosal gland sections at depth. Overall, the findings are consistent with an irritation fibroma. Wound inspection continued for a period of two months after the intervention. At this point in time, the wound was fully healed and the recess which was discernible immediately after removal could no longer be felt and there were no signs to indicate the formation of new tissue. There was neither visually pronounced scarring nor scarring which could be discerned when eating. The patient reported feeling a burning sensation in the area from which the tissue had been removed during healing. This sensation rescinded continually and could not be described as very painful at any time. A further inspection was carried out after six months as part of a routine dental check-up.

Concluding remarks

Laser systems can be used in a variety of ways for dental treatments. In most cases, this technology offers similar results to those achieved with conventional methods. In this case, the indication for use of the laser system was further supported by the patient's wishes: If a patient states that he is very sensitive to pain, a method should be chosen with which there is little risk of postoperative hemorrhaging and where a suture is not absolutely necessary¹¹ in order to avoid a second intervention to remove the suture. Furthermore, it must also be possible to acquire a tissue preparation which can be assessed histologically which enables a reliable diagnosis of new tissue formation to be made. In this case, all the require-

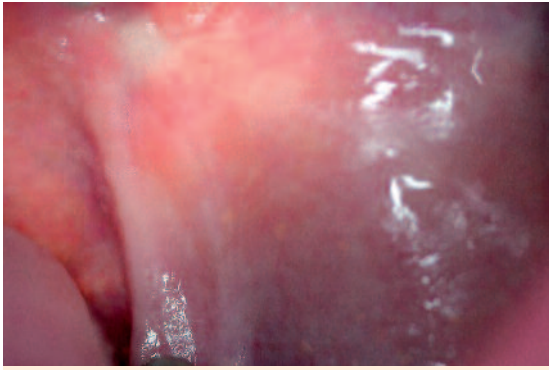


Fig. 11: Inspection of the wound two months after the intervention. Completely healed wound area without visible scar formation, no signs of the formation of new tissue.

ments for the use of a 970 nm diode laser for the surgical intervention were satisfied. This method thus complements conventional techniques for tissue removal and enables, subject to correct use, histological examinations of the tissue samples removed to be made. ◀

First published:

Laser Journal 3/13, OEMUS MEDIA AG (german edition).

Literature

1. Vescovi P, Corcione L, Meleti M, Merigo E, Fornaini C, Manfredi M, Bonanini M, Govoni P, Rocca JP, Nammour S. Nd:YAG laser versus traditional scalpel. A preliminary histological analysis of specimens from the human oral mucosa. *Lasers Med Sci* 2010;25:685–691.
2. Soares FM, Tarver EJ, Bimstein E, Shaddox LM, Bhattacharyya I. Gingival overgrowth in a child with arthrogyriposis treated with a Er,Cr:YSGG laser: a case report. *Pediatr Dent* 2009;31:8–13.
3. Haytac MC, Ozcelik O. Evaluation of patient perceptions after frenectomy operations: a comparison of carbon dioxide laser and scalpel techniques. *J Periodontol* 2006;77:1815–1819.
4. Russo J. Periodontal laser surgery. *Dent Today* 1997;16:80–81.
5. Ricketts DN, Pitts NB. Novel operative treatment options. *Monogr Oral Sci* 2009;21:174–187.
6. Braun A, Jepsen S, Deimling D, Ratka-Krueger P. Subjective intensity of pain during supportive periodontal treatment using a sonic scaler or Er:YAG laser. *J Clin Periodontol* 2010;37:340–345.
7. Romanos GE, Gutknecht N, Dieter S, Schwarz F, Crespi R, Sculean A. Laser wavelengths and oral implantology. *Lasers Med Sci* 2009;24:961–970.
8. Assaf M, Yilmaz S, Kuru B, Ipci SD, Noyun U, Kadir T. Effect of the diode laser on bacteremia associated with dental ultrasonic scaling: a clinical and microbiological study. *Photomed Laser Surg* 2007;25:250–256.
9. Lopes BM, Theodoro LH, Melo RF, Thompson GM, Marcantonio RA. Clinical and microbiologic follow-up evaluations after non-surgical periodontal treatment with erbium:YAG laser and scaling and root planning. *J Periodontol*. 2010;81:682–691.
10. Gutknecht N, Franzen R, Schippers M, Lampert F. Bactericidal effect of a 980-nm diode laser in the root canal wall dentin of bovine teeth. *J Clin Laser Med Surg* 2004;22:9–13.
11. Capodiferno S, Maiorano E, Scarpelli F, Favia G. Fibrolipoma of the lip treated by diode laser surgery: a case report. *J Med Case Rep* 2008;2:301.