

THE DENTAL
SOLUTIONS
COMPANY™



Orthophos SL – around the world

15 user cases from 11 countries



Dear Readers,



For solving complex, interdisciplinary problems, technological developments in dentistry are constantly opening up new opportunities. On the one hand, the latest innovations enable approaches within the various specialist areas to become more intricate while also becoming more reliable in diagnostics and the predictability of results on the other. When technology works smoothly, it helps dentists to better focus on the patient. Dentistry always should focus on the patient.

This distinctive brochure, which we were able to compose with the help of specialists from all over the world, focuses on X-rays. Our international authors all have one thing in common: they use 3D X-rays with Orthophos SL for unclear diagnoses and complex cases.

With the Orthophos SL, Dentsply Sirona offers a complete X-ray solution that optimally prepares you as a dentist for a wide range of treatment situations. This includes high-resolution CBCT images and low dose images, which provide 3D information in the dose range of a 2D image for a variety of indications.

The increased information from a 3D image relative to a 2D image,

provides greater reliability in diagnostics and planning, and more opportunities to find the best treatment options. There are plenty of examples of information gain and treatment impact contained in the brochure. Our authors, who use their Orthophos SL units for a wide range of problems, illustrate when and how your patients and, of course, you can use the advantages of a comprehensive X-ray solution for greater safety and success in your everyday practice through their case studies in implantology, endodontics, orthodontics, sleep apnea treatment and practice management.

Wishing you much joy and inspiration while reading this brochure,

A handwritten signature in black ink that reads "Jörg Haist". The signature is written in a cursive, slightly stylized font.

Jörg Haist
Vice President Global Platform
Management Equipment &
Instruments, Dentsply Sirona

Directory

● Dr. Erin E. Elliott,
Post Falls, ID, USA **p. 10**
#Dentists in sleep medicine

● PD Dr. Dr. Lutz Ritter,
Hennef, Germany **p. 20**
#Radiation exposure for children

● Dr. Fabienne Oberhansl,
Stuttgart, Germany **p. 16**
#Implant in atrophied bones

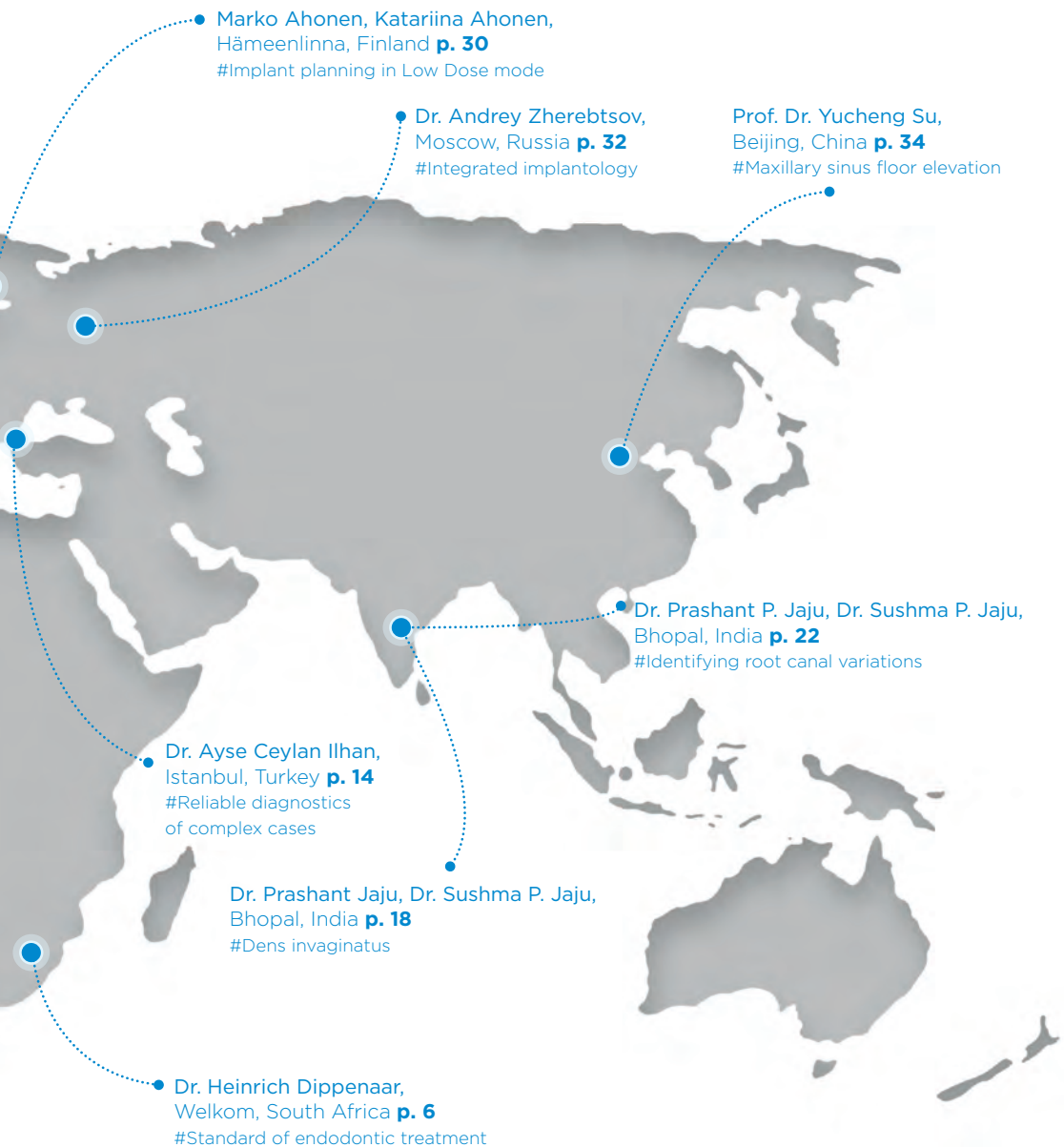
● Dr. Jörg Tchorz,
Raubling, Germany **p. 8**
#Visualizing root canal
anomalies

● Dr. Gertrud Fabel,
Munich, Germany **p. 12**
#3D respiratory tract analysis

● Dr. Björn Ludwig,
Traben-Trarbach,
Germany **p. 24**
#Alignment of displaced teeth

● Dr. Salvador Insignaris,
Cartagena, Colombia **p. 26**
#All-in-one-marketing

● Dr. Imre György Borzási,
Budapest, Hungary **p. 28**
#Effective diagnostics of
inexplicit cases



• Marko Ahonen, Katariina Ahonen,
Hämeenlinna, Finland **p. 30**
#Implant planning in Low Dose mode

• Dr. Andrey Zherebtsov,
Moscow, Russia **p. 32**
#Integrated implantology

Prof. Dr. Yucheng Su,
Beijing, China **p. 34**
#Maxillary sinus floor elevation

• Dr. Prashant P. Jaju, Dr. Sushma P. Jaju,
Bhopal, India **p. 22**
#Identifying root canal variations

• Dr. Ayse Ceylan Ilhan,
Istanbul, Turkey **p. 14**
#Reliable diagnostics
of complex cases

• Dr. Prashant Jaju, Dr. Sushma P. Jaju,
Bhopal, India **p. 18**
#Dens invaginatus

• Dr. Heinrich Dippenaar,
Welkom, South Africa **p. 6**
#Standard of endodontic treatment

MORE SAFETY THROUGH OPTIMAL PLANNING WITH 3D ENDO SOFTWARE

Author Dr. Heinrich Dippenaar, Welkom, South Africa

Over the last 10 years, the use of CBCT in endodontic treatment planning has gained popularity. Dentists quickly realized that CBCT was not just for implant and surgical planning but could also play a vital role in endodontic procedures. You can only treat what you can diagnose and see, and with the inclusion of a focused field 5x5 scanning option now standard on most CBCT machines, 3D imaging has become the standard of care in endodontic treatment protocols. It saves a lot of time knowing how many canals are present in a tooth before treatment commences.

A 53-year-old patient presented to my practice with irreversible pulpitis on tooth 46. The presence of an extra distal root was evident on the periapical X-ray (Fig. 1). I took a 5x5 focused FOV (Field-of-View) CBCT with my Orthophos SL and discovered an extra distal root on the 46 (Fig. 2 and 3). This is called a Radix entomolaris (Radix paramolaris when the extra root is located buccal). The scan was imported into the 3D Endo software and pre-planning followed (Fig. 4 to 6).

Looking at the post-operative X-ray, it should be noted how conservatively the canal preparations are done with the WaveOne Gold files. The new gold metal is very soft and gentle and it can feel like the canals are shaping the file, rather than the file that's shaping the canal.

With the new 3D Endo software I can plan my cases more accurately and print out a report for the patient. The patient also importantly benefits from better understanding the planned treatment.

Dentsply Sirona has taken the endodontic world by storm with their 3D Endo software specifically designed and developed for pre-endodontic planning. It is now possible to calculate the number of canals, the length of each canal, as well as which endodontic instrument to use in each canal to optimally clean and shape the canal without removing too much tooth structure. The software also assists in designing a conservative access cavity to enable you to find all the canals and preserve tooth structure. Figure 7 shows the final situation. All four canals were closed with WaveOne Gold Primary files.

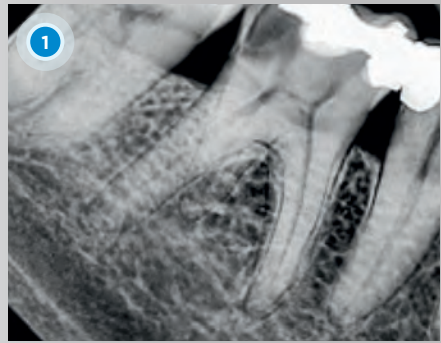


Fig. 1 Pre-op 2D X-ray showing indication of extra distal root.

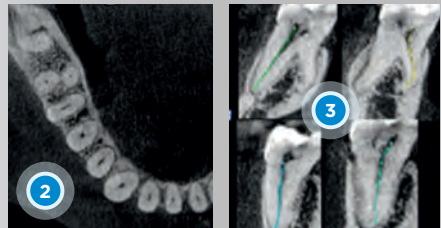


Fig. 2 Coronal Orthophos SL \varnothing 5x5 CBCT with extra distal root clearly visible.

Fig. 3 Canal plotting in 3D Endo software. Look at the severe curve of the extra distal root.

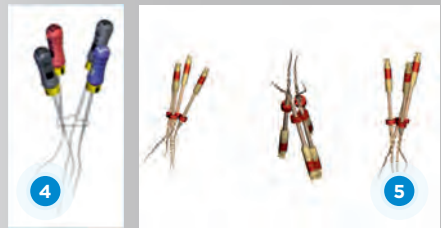

Fig. 4 Length determination in software. All the canals are separate and don't merge at the apices.

Fig. 5 Different angles of the 3D Endo software with planned WaveOne Gold Primary (red 25 tip size) for each canal. In turning the simulation one realizes what torsional stress endodontic files endure during treatment.

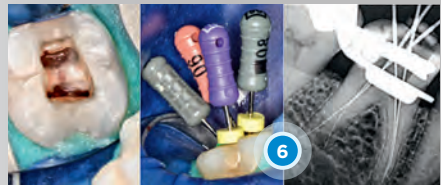
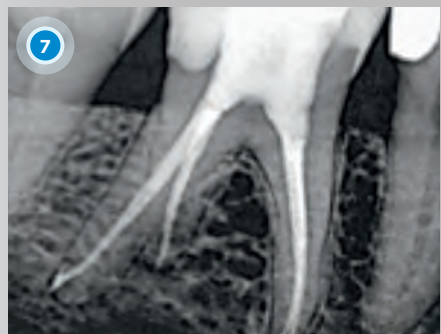
Fig. 6 Four canal orifice visible; length determination with the help of an apex locator.

Fig. 7 Post-op treatment X-ray. All four canals obturated with WaveOne Gold primary files.



THREE-DIMENSIONAL TREATMENT PLANNING

Author Dr. Jörg Tchorz, Raubling, Germany

When looking at intraoral radiographs, not only are periapical changes regularly overlooked, but also calcification, accessory roots and root canal curvatures are often misinterpreted. In particular, the posterior region of the upper jaw can be challenging due to osseous overlap. The usage of dental cone beam technology (CBCT) in endodontology has many advantages. CBCT not only reveals periapical lesions that were missed on intraoral images, it also enables the precise assessment of complex root canal anatomies.

Due to pulpitis on a second maxillary molar, a root canal treatment was started alio loco. Since the symptoms persisted after treatment, the patient was referred to a specialist for further treatment. The root anatomy and the periapical region could not be clearly assessed on the basis of the available intraoral radiograph due to a projection-related superimposition (Fig. 1). For this reason, it was decided to perform a CBCT scan with a small field of view (Orthophos SL, volume Ø 5 x 5 cm, High Definition resolution 80 µm) to facilitate pre-endodontic diagnostics. The DICOM data were then used for three-dimensional treatment planning using the 3D Endo software. The software guides the user intuitively through the individ-

ual planning steps. After a diagnosis of the entire volume, it is reduced to the relevant area (Fig. 2) and the canal entrances and apical foramina of each root canal are marked separately. The root canal progressions detected by the software in three dimensions are checked in the following step and can be modified by the user if necessary (Fig. 3). The visualized root canal instruments can be used to plan coronal canal extensions and rectilinear access cavities. The integrated file database allows the selection of suitable instruments and by adjusting the rubber stoppers to the respective reference points, the root canal lengths can already be estimated pre-endodontically (Fig. 4).

The CBCT detected an untreated second mesiobuccal canal. The 3D design resulted in a Weine classification type II with conflation in the apical third of the root. This anatomy was clinically confirmed after the glide path was established (Fig. 5). The three-dimensionally measured lengths were checked by electronic apex locator and the canals were then enlarged using WaveOne Gold instruments. The enlargement of the second mesiobuccal canal was only carried out up to the confluence. After activated chemical disinfection with EDTA and NaOCl, root canals were dried with paper points and

obtured using a warm vertical compaction technique (Fig. 6). The distortion and overlay-free imaging of the Orthophos SL CBCT in combination with the 3D Endo software enabled a precise assessment of the root canal anatomy and subsequent three-dimensional planning of the entire endodontic treatment.

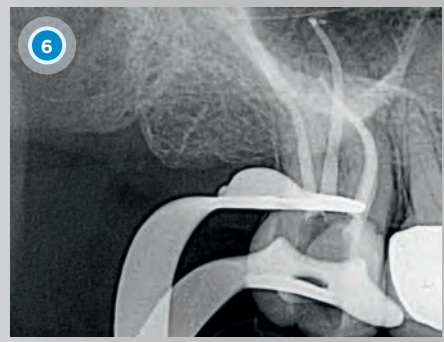
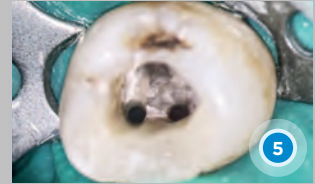

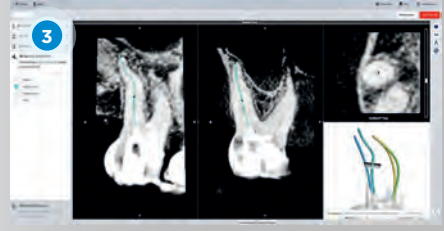
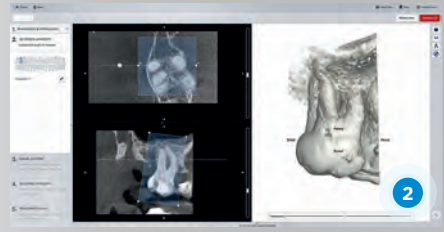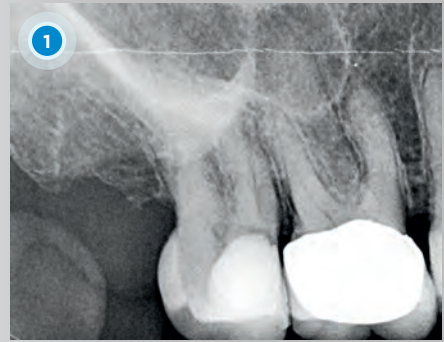


Fig. 1 Pre-endodontic intraoral radiograph: Due to osseous superimposition, periapical diagnosis and evaluation of root canal morphology is almost impossible.

Fig. 2 The 3D Endo software guides the user intuitively through the planning steps. After evaluating the entire CBCT scan, it is reduced to the relevant endodontic region.

Fig. 3 The three-dimensionally detected root canal space can be adjusted if necessary.

Fig. 4 The visualized root canal instruments facilitate the planning of the clinical access cavity localization and outline.

Fig. 5 The second mesiobuccal canal was detected in the CBCT and displayed clinically without any problems.

Fig. 6 Intraoral radiograph to evaluate the treatment outcome.

THE ROLE OF DENTAL PROFESSIONALS IN SLEEP MEDICINE

Author Dr. Erin E. Elliott, DDS, Post Falls, ID, USA

Patients often neglect to discuss sleeping issues with their dentist because they aren't aware of the role that the dentist can have in helping to diagnose and treat underlying problems such as sleep apnea. 3D imaging can help patients to visualize this connection and improves communication with the patient as well as understanding of the proposed treatment plan.

A 61-year-old female patient came to our practice for a regular check up as a new patient. Upon scanning we found a large periapical radiolucency resulting from an infection after a root canal creating a lot of bone loss near the sinus. The patient wasn't aware of the problem as she was not experiencing noticeable symptoms. We referred the patient to an endodontist for re-treatment.

As part of the initial consultation with every new patient, a detailed history is taken. During the conversation, the patient mentioned that she suffered from trouble sleeping and often experienced migraines but had never considered the possibility of suffering from sleep apnea. I specialize in Dental Sleep

Medicine and have treated sleep apnea for nearly a decade and therefore was able to recommend a plan for diagnosis and treatment if warranted.

The patient had dental signs and symptoms of sleep apnea including a narrow arch form, scalloped tongue, clenching and a narrow airway. Visualizing the Orthophos SL 3D scan in SICAT Air helped the patient to better understand the connection between the upper airway and dentistry. The next step involved a home sleep study, which indeed revealed moderate sleep apnea.

The treatment plan utilized 3D imaging data to create an OPTISLEEP appliance. The fully digital workflow is efficient and the appliance can be ordered directly through the SICAT Air software. The result was a very happy patient. This was a particularly rewarding case because after wearing the appliance, the patient remarked that she hadn't had a restful night's sleep in so long she had forgotten what it was like to wake up feeling rested.

As a dental practice that sees patients across all aspects of dentistry, the addition of the Orthophos SL

unit just over a year ago has improved our patients' understanding of diagnoses and treatment plans. This in turn helps to create awareness about the particular issue as well as a sense of urgency for why it's important to move forward with treatment. In the specific area of Dental Sleep Medicine, 3D imaging helps to start the conversation with our patients about why we as dental professionals care about sleep and how we can help.

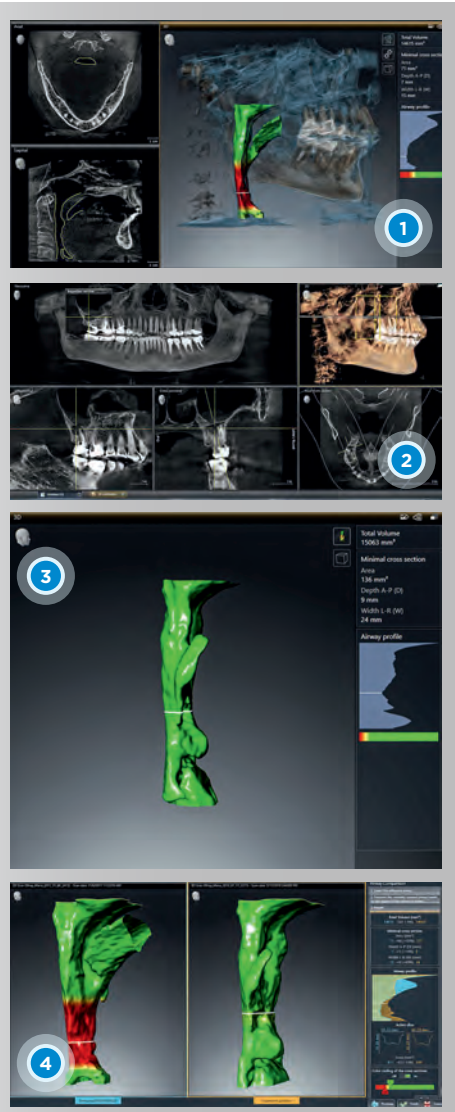

Fig. 1 Upper airway visualized in SICAT Air.

Fig. 2 3D examination in Sidexis 4.

Fig. 3 Final situation of lower jaw in therapeutic position (OPTISLEEP appliance in situ).

Fig. 4 Comparison of the upper airways in habitual and therapeutic positions of the lower jaw.

3D ANALYSIS OF UPPER AIRWAYS WITH SICAT AIR AND ORTHOPHOS SL

Author Dr. Gertrud Fabel, MSc., Munich, Germany

Snoring is a reason for more and more patients to visit a dentist. Quite a few come with the very concrete desire for a snore guard. They have the wish for a more restful sleep, but they are also worried about possible breathing interruptions. With the aid of an X-ray image in Low Dose mode and a 3D respiratory tract analysis, this can be precisely analyzed to advise the patient and treat accordingly.

Patients who snore and come to the dentist, often already have had an examination in a sleep laboratory. They have received the diagnosis of sleep apnea and bring the relevant documents with parameters such as the Respiratory Disturbance Index (RDI) into the practice. Some have had a breathing mask for some time at home (commonly CPAP: Continuous Positive Airway Pressure) without really accepting or tolerating it.

It is our experience that an additional 3D analysis helps to advise patients well and often results in a different method of treatment than originally planned. For this we use the Orthophos SL Low Dose mode in combination with the SICAT Air software. We can visualize the airways and gain new options for patient counseling. A standard control

of the upper airways in images taken from a different indication sometimes involves clarifying a possible airway obstruction. If the follow-up polysomnography provides a corresponding diagnosis and confirms the suspicion of obstructive sleep apnea (OSA), the dental protrusion appliance may be an adequate treatment method for mild to moderate RDI.

A digital scan of the upper and lower jaw with the CEREC Omnicam (alternatively: model scan in protruded bite position) allows for the fabrication of a protrusion appliance in a fully complete digital workflow. The SICAT OPTISLEEP is an appliance for the upper and lower jaw, connected by connectors which come in different lengths. The appliance allows for normal mouth breathing and patients find it very comfortable to wear due to its slim design. The following two cases are remarkable examples from our practice because they each ended with a different therapy than the patients initially expected.

The 37-year-old patient (female) was not considered an at-risk patient, presenting with a normal weight and without general medical findings. The CBCT was taken in

Low Dose mode as a follow-up check of an implantation (Fig. 1). The airway control already showed a strong constriction in the airways when the patient was standing, so that a polysomnography was recommended for existing anamnestic snoring. The diagnosis was: mild sleep apnea with RDI 6. The image in protrusion showed the airway with significantly better opening (Fig. 2). After the airway comparison in the SICAT Air software, the intraoral scan was superimposed in order to enable the digital ordering of the SICAT OPTISLEEP mandibular advancement appliance in this jaw position in the next step. The follow-up showed a subjectively improved night's rest and recovery of the patient.

The second patient (male), who had several risk factors for sleep apnea (age, overweight, snoring), came into the practice with a clear desire for a snore guard. The intraoral findings showed, among other things, a strongly reduced number of teeth and a covering bite, so that we

aimed at dental restoration and elevation of the vertical dimension in occlusion (VDO). The restoration with long-term temporaries and adjustment in neuromuscular jaw relation resulted in a complete remission of snoring. A narrowing of the airway when the VDO was raised was not noticeable (Fig. 3 and 4). Even after final tooth replacement treatment, there was no more evidence of apnea.

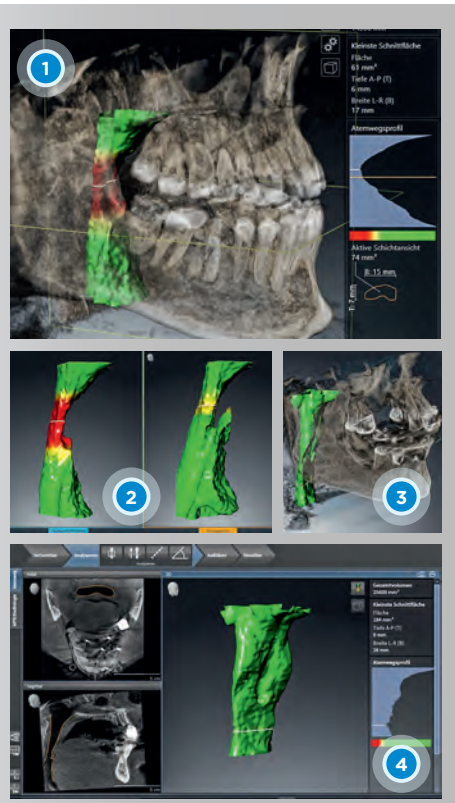


Fig. 1 Visualization of upper airway in 3D Low Dose mode after implantation.

Fig. 2 Comparison of the upper airways visualization in the SICAT Air software.

Fig. 3 Situation after raising the VDO: no constriction of the airways.

Fig. 4 Situation of pharynx and respiratory tract after raising the VDO.

RELIABLE DIAGNOSTICS WITH 3D ANALYSIS

Author Dr. Ayse Ceylan Ilhan, MSc. Dt., Istanbul, Turkey

In daily practice, complex cases present difficulties for decision-making during treatment planning. Digital technology helps the clinician to get more information via a 3D scan of the whole jaw or a specific area and makes it possible to combine all critical prosthetic information and anatomical information. Orthophos SL provides us with high quality images in diagnosis. With a 3D X-ray scan we perform complicated endo treatments and produce surgical guides for implant therapy. After a surgical intervention is performed, it is possible to finish the case within a single visit using the CEREC system. This integrated workflow helps us to create different treatment options leading to a successful outcome.

A 34-year old female patient presented to our clinic complaining of severe pain in her left lower jaw while chewing. Tooth number 36 was extracted a few weeks earlier at a hospital due to total crown loss, but the extraction had not remedied her pain.

During the initial clinical and radiological 2D examination, there were some complicated findings (Fig. 1): Tooth number 36 was extracted as it was suspected to be the cause of the pain. Tooth number 35 had been severely destroyed by repeated endo-

dontic treatment and seemed to be beyond saving. The remaining dentin was very weak due to poor preparation of the access cavity, meaning that the access cavity was very deep. Additionally, tooth number 37 had an old filling with a marginal discrepancy at distal. We decided that additional information would be needed for the treatment planning and therefore performed a 3D scan in Standard Definition (SD) mode with Orthophos SL.

We decided to use this 3D data for each step of the necessary treatment including implant placement as well as endo analysis. A digital impression and CBCT scan were performed from the lower jaw for implant planning. The first idea was to extract tooth number 35 and place two implants. However, a second missed lateral canal was determined based on the CBCT. We decided to do a retreatment using 3D Endo software. The lateral root canal ended at the same apical foramen (Fig. 2). The old restoration was removed carefully under magnification. The remaining tooth structure was very weak and the access cavity depth was calculated on 3D Endo software to be around 7.75 mm. The additional lateral root canal treatment was planned. The old root canal filling was redone and the lateral root canal was also filled with gutta-percha and sealing paste. Afterwards a fiber

post was adhesively cemented in the root canal.

For treatment of region 36, a CEREC Guide 2 was milled based on the implant planning in the Galileos Implant software for placing a XIVE S Plus implant (diameter 4.5; length 11) precisely at the septum area of the extraction socket (Fig. 3 and 4). After two and a half months, osseointegration occurred and for the prosthetic phase we placed a scan-post on the site of tooth number 36 for a digital impression (Fig. 5). At the same time, crown preparation for tooth number 35 and onlay preparation for tooth number 37 was done along with a digital impression using the CEREC Omnicam. During the same appointment, a screw-retained crown was milled and cemented on a 4.5 FX Tibase with Multilink Hybrid Abutment and

placed intraorally. A CEREC inlay restoration on tooth number 37 and a CEREC crown on tooth number 35 were milled with e.max CAD Block and adhesively cemented (Fig. 6).

The integration of 3D data and digital impressions promises confidence in treatment planning and simplifies the path to success in complex cases.

Fig. 1 First Orthophos SL X-ray of the initial situation. Tooth number 36 was extracted; tooth number 35 has been severely destroyed by repeated endodontic treatment and seemed to be beyond saving.

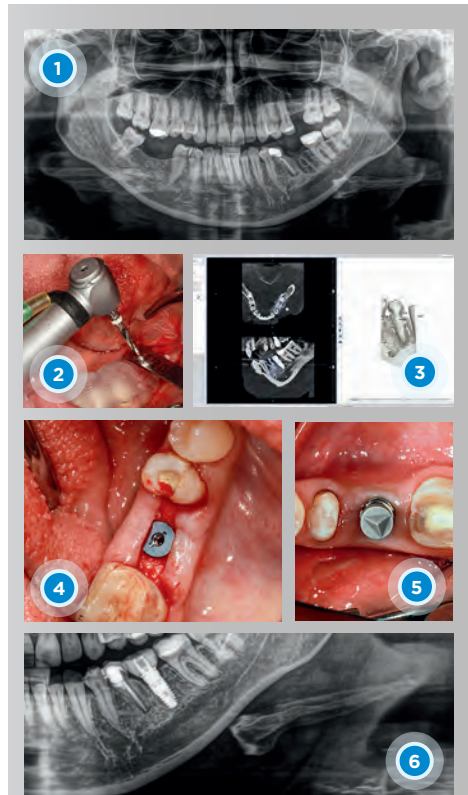
Fig. 2 The initial situation in 3D Endo to perform retreatment of tooth 35.

Fig. 3 A CEREC Guide 2 was produced for placing the implant precisely at tooth 36.

Fig. 4 The implant was positioned using the flap technique.

Fig. 5 With the Scanpost for digital impression in-situ.

Fig. 6 The Orthophos SL image of the final situation.



IMPLANTS WITH LIMITED BONE STRUCTURE

Author Dr. Fabienne Oberhansl, MSc., Stuttgart, Germany

In the case of patients with a significantly reduced number of teeth or edentulousness and the desire for a fixed restoration, the dental surgeon is often faced with the dilemma of a compromise due to the atrophied bone. This article shows a minimally invasive solution for such a case that makes optimal use of the existing bone supply with low surgical load and short treatment duration with the aid of 3D diagnostic-based planning and angulated implants.

In the late 1990s, Dr. Paulo Maló published the principle of placing implants at an oblique angle in order to achieve the largest possible support polygon and thus a tooth system up to the first molar with only four implants. Advantages of the procedure are minimally invasive implantations, avoidance of augmentation and large incisions, sufficient tissue punching and ideally positioned implants thanks to guided implant placement. Immediately after placement of the implants, the long-term temporary can be adapted and inserted. The patient leaves the practice with fixed teeth on the day of implantation.

The SmartFix concept on the Astra Tech Implant System EV offers the additional advantage that the beveled profile EV implants in the dorsal area, which can be placed circularly

flush with the bone, do not have to be inserted very deeply. There are no deep or dirt pockets and the associated risks of peri-implant inflammation or bone fractures.

The 33-year-old patient presented with desolate tooth status (Fig. 1). She suffered from poorly fitting model cast prostheses and expressed a desire to have her teeth fixed. The telescopes in the upper jaw had already been decemented several times. The stumps underneath were carious and destroyed and prosthetic restoration was not possible. The lower jaw showed a cystic lesion of more than 2 cm in diameter and apical lesions on 42-43 on the radiograph in region 33-32. A decision was made to treat the upper jaw with six implants and the lower jaw with four implants.

CBCT (Orthophos SL) was used to estimate the exact course of the inferior alveolar nerve and bone supply in the orovestibular direction and to plan the treatment. On this basis, reliable planning could be carried out. In region 26, only about 1 mm residual bone level was present. Due to the need for an external sinus lift, this area was not included in the provisional immediate restoration. In the lower jaw, the dorsal region was also strongly atrophied. Therefore, it was decided to place the implants intraforaminal

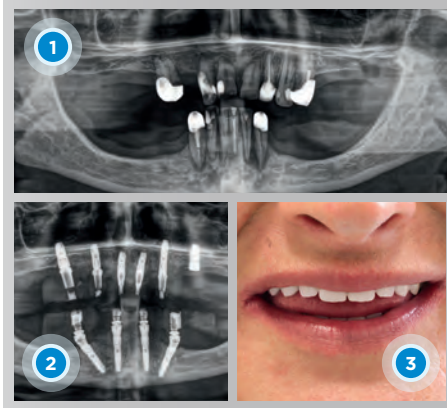


Fig. 1 Image of the initial situation with the Orthophos SL: the desolate initial situation is clearly visible.

Fig. 2 X-ray after implantation.

Fig. 3 Lip image with the long-term temporary.

and the two lateral ones after dorsal angulation.

Due to the poorly fitting prosthetic restorations, the vertical dimension had dropped more than 1 cm. Therefore, a mock-up for the front with attachment of bite splints was made and adhesively cemented. After a few weeks, the impression was taken for planning and the technician duplicated the reconstructed prosthesis. The models and duplicated mock-up were scanned and matched in the Siplant software. Now the implants could be ideally placed virtually and the abutment parts could be selected and ordered. It was also determined whether a dental, mucosal or bone-supported surgical guide should be ordered. The most minimally invasive variant was chosen: the dental-supported surgical guide.

The planning is then checked by the Siplant team and, if necessary, small adjustments are suggested before the surgical guide is produced and delivered to the practice

within a few days. The dental technician prepares the temporary restoration and the operation can go ahead.

The operation in the upper jaw was performed first. At the request of the patient, who had handled the operation very well, the lower jaw could already be operated on after six weeks. After extraction of the teeth that weren't required for stencil stability, the cystic tissue was completely removed by curettage under the surgical microscope. Afterwards, the Astra EV implants were placed using a fully guided method. Multibase EV abutment bodies and heads were then screwed into their correct positions (25 Ncm), followed by the Multibase EV Temporary Cylinder on which the long-term temporary was tried on without tension. During the redevelopment and polishing of the long-term temporary in the laboratory, the areas of the extraction sockets and the cystic lumen were filled with a mixture of autogenous bone and Symbios. The long-term temporary was then introduced. The shafts were closed with a foam pellet as a placeholder above the screw and flowable composite. The occlusion was optimized and a post-operative X-ray and lip images were taken (Fig. 2 and 3).

DIAGNOSING DENS INVAGINATUS WITH ORTHOPHOS SL CBCT

Authors Dr. Prashant P. Jaju, BDS, MDS, and Dr. Sushma P. Jaju, BDS, MDS, Bhopal, India

As a practice specialized in dental radiology, many dentists use our services. We were the first practice in India to use 3D imaging. With the introduction of Dentsply Sirona's Orthophos SL CBCT, complicated cases are diagnosed and treated efficiently and more successfully with the help of a smaller volume specific for endodontic purposes. Indeed, cone beam computed tomography is a boon for endodontists across the globe. In this article we are presenting a difficult endodontic case where an Orthophos SL CBCT 5x5,5 volume aided in identifying dens invaginatus and its subsequent treatment planning.

A 24-year-old male patient had swelling in the upper right canine region. An intraoral, periapical radiograph showed variation in pulpal floor anatomy but the lack of a third dimension limited its utility. For further evaluation of tooth root canal anatomy, limiting volume CBCT was advised. Orthophos SL CBCT 5x5.5 High Definition (HD) volume, at 80 microns showed variation in pulpal floor anatomy. CBCT images revealed invagination extending through the root and communicating laterally with the periodontal

ligament space through a pseudo-foramen without communicating with the main root canal space. A single major orifice was present surrounded by two radiolucent areas on mesial and distal sides extending approximately 4 mm within the root not associated with the main canal (Fig.). A single, large, periapical radiolucency was present with the tooth resulting in thinning of labial cortical plates.

This was radiographically diagnosed as a case of dens invaginatus type IIIA resulting in chronic periapical abscess (1). With three-dimensional visualization of the root canal space anatomy variation, the endodontist was able to proceed with a new, improved treatment protocol resulting in successful root canal filling and restoration.

Dens invaginatus is a developmental anomaly resulting in a deepening or invagination of the enamel organ into the dental papilla prior to calcification of the dental tissues. Although dens invaginatus is common it may be easily overlooked because of the absence of any significant clinical signs of the anomaly.

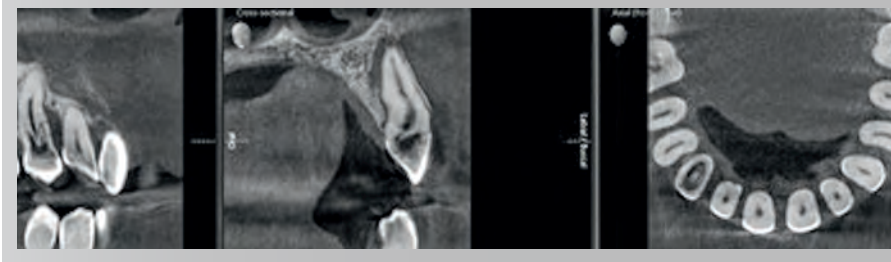


Fig.: Sagittal, cross sectional, axial images of upper right canine on Orthophos SL with a resolution of 80 μm .

Periapical radiographs are limited in revealing the type, extension, and complex morphology of dens invaginatus as well as the actual bone loss when compared to tomographic techniques. More advanced imaging techniques, such as CBCT, may aid the diagnosis as well as the management plan and follow-up of teeth with this developmental defect (2).

References:

1. Alani A, Bishop K. Dens invaginatus. Part 1: Classification, prevalence and aetiology. *International Endodontic Journal*, 41(12): 1123-1136.
2. Pradeep K, Charlie M, Kuttappa MA, Rao PK. Conservative Management of Type III Dens in dente using cone beam computed tomography. *Journal of Clinical Imaging Science* 2(1): 51.

LOWEST POSSIBLE RADIATION EXPOSURE IN PEDIATRIC DENTISTRY: THE 3D LOW DOSE MODE

Author PD Dr. Dr. Lutz Ritter, Hennef, Germany

Radiation protection has a key role to play in pediatrics and orthodontics. It is important to keep radiation doses as low as possible for young patients. But to be able to make a precise diagnosis, it is also important to achieve good quality imaging of the symptoms. Orthophos SL 3D's Low Dose mode is therefore an outstanding match for use with children and young persons: Despite its low radiation dose, it delivers radiographic images of a suitable diagnostic quality.

X-ray examinations place particular demands in the case of children and young persons and especially in the orthodontic treatment of children. The imaging systems operate with radiation doses, adjusted to generate high-quality images for clear diagnosis and effective treatment planning in adults. Such a dose can often be too high for children as they are more susceptible to radiation-induced cancers. Therefore global guidelines ensure special radiation protection in pediatric radiology. Adhering to these guidelines and creating high-quality images is a major challenge, which can be ameliorated in two ways: restrict-

ing the volume size, and limiting the radiation exposure. Orthophos SL 3D makes both possible: It can be used optionally with volumes measuring 8x8 cm, 11x10 cm or 5x5.5 cm. In addition, the Low Dose mode enables, for example, the arrangement and the precise position of teeth to be imaged; which can lower the radiation level by up to 85 percent in comparison with conventional 3D images. The image quality and various application options required for each indication are thus easily combined, as shown in the example below.

A young patient presented to the practice with lower jaw symptoms which – as it turned out – originated from difficult dentition (Dentitio difficilis) affecting tooth 38. To prepare the X-ray findings, an initial panorama image was made using the 2D mode of the 2D/3D hybrid X-ray system Orthophos SL, which showed the Canalis mandibularis covering the root (Fig. 1). There was also an incidental finding: Tooth 28 was displaced – with ambiguous resorption of the roots of teeth 38 and 48 with the mandibular canal. There was also a suspected inflammation of the root tip (apical osteitis) at tooth 26.

To produce unambiguous diagnoses, we made a CBCT in the Low Dose mode of Orthophos SL. Different volumetric images generated from the volume were able to reveal the interradicular position of tooth 28 without any sign of the roots of tooth 27 being resorbed (Fig. 2). In addition, it was shown which of the three roots of tooth 26 was infected: the strongly curved mesial root of 26 (Fig. 3). There are signs of bone loss (osteolysis) distally from tooth 27 (Fig. 4). The positional relationship of tooth 38 to the mandibular canal could be unambiguously imaged by using differing perspectives (Fig. 5).

Result: Even at a reduced dose, the image is of suitable quality to show the precise position of displaced teeth and their positional relationship to other anatomical structures thereby enabling a therapy plan to be worked out. 3D imaging of tooth 26 thus made it possible to clearly establish that treatment was required and also which root was affected.

The full diagnosis meant a gain in terms of safety for the clinician and improved patient communication because the patient could be briefed about potential risks more meaningfully and precisely while better demonstrating the therapy proposal.

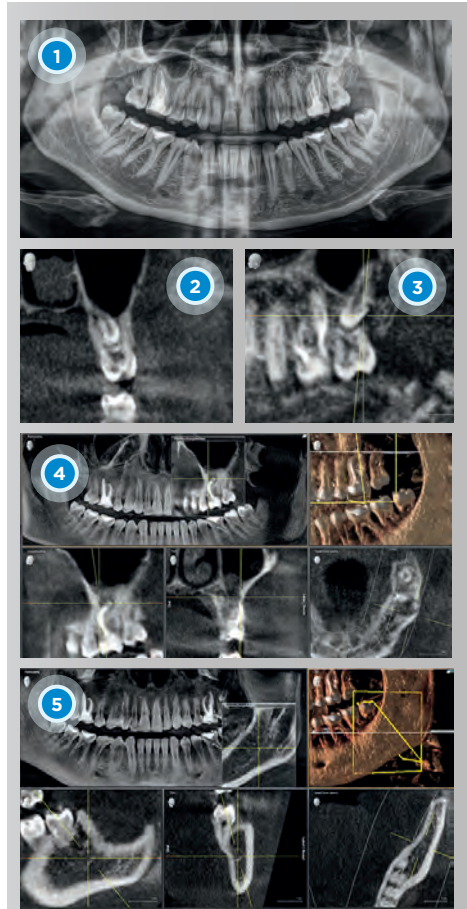
Fig. 1 The generated panorama image shows the displacement of tooth 28.

Fig. 2 According to the transversal slice image (TSI) of the Low Dose scan the displaced tooth 28 shows no signs of its roots being resorbed.

Fig. 3 The image confirms the suspicion of apical osteitis of the mesial root.

Fig. 4 The first signs of osteolysis are recognizable.

Fig. 5 Positional relationship of tooth 38 to the mandibular canal.



CBCT IDENTIFIES UNCOMMON ROOT CANAL VARIATION

Authors Dr. Prashant P. Jaju, BDS, MDS, and Dr. Sushma P. Jaju, BDS, MDS, Bhopal, India

CBCT brought a paradigm shift to dental imaging, unraveling the unsolved mysteries of dentistry from a two-dimensional perspective to a three-dimensional perspective. Hybrid CBCT machines such as the Orthophos SL offer better resolution which helps to evaluate changes in cortical and cancellous bone at the sub-millimeter level. The following case demonstrates how CBCT enabled the identification and subsequent navigation of complex root canal anatomy.

A 27-year-old female patient was referred to our dental diagnostic center for evaluation of the maxillary right first molar because the general dentist suspected variation in root canal anatomy. A 5 x 5.5 cm CBCT scan was performed. On evaluation of the scan, three major orifices were present, mesiobuccal, distobuccal and palatal. The mesiobuccal canal below the furcation region showed two canals – mesiobuccal 1 and 2.

Approximately 2.5 mm below the pulpal floor, a third canal emerged (MB3) from the main mesiobuccal canal (MB1) (Fig. 1–3). At approximately 4 mm distance below the pulpal floor, 2 and 3 merged again with each other to exit through a

single foramen and the main mesiobuccal canal exited through another foramen. Oval shaped periapical radiolucency was present with all three roots. Thinning and perforation of the palatal and buccal cortical plates on the sinus floor were observed.

Opening and modifying the shape of the access cavity to approach all orifices is a key to success in identifying and negotiating unusual anatomy of root canals. CBCT is a valuable tool for the initial identification and effective evaluation of the internal morphology of teeth. Mesiobuccal 2 canal is one of the most common root canal anatomy variations with respect to maxillary molars. Mesiobuccal 3 canal is quite rare with an incidence of 1.1 percent. Minute assessment of this complex root canal anatomy was possible due to the high resolution offered by Orthophos SL. The diagnosis and information were then passed on to the patient's dentist.

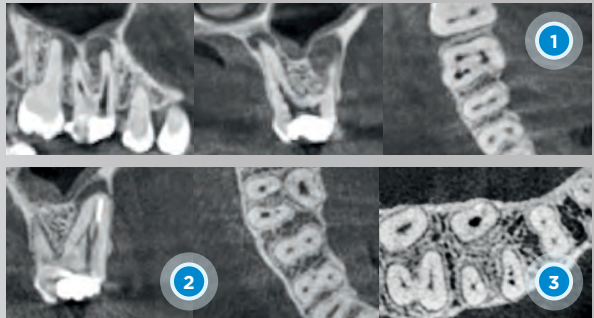


Fig. 1 Images taken at coronal third level of roots. Orthophos SL axial image shows four major orifices, with two mesiobuccal canals. Periapical lesion is present with both buccal roots.

Fig. 2 Orthophos SL cross sectional and axial image view show separation of mesiobuccal 1 canal into mesiobuccal 3 canal in middle third level of root.

Fig. 3 Orthophos SL axial images show all three canals in mesiobuccal root at apical third level.

EASY TREATMENT MONITORING THROUGH CBCT

Author Dr. Björn Ludwig, Traben-Trarbach, Germany

3D diagnostics has increased considerably in significance in recent years. More and more dentists of widely differing specializations are discovering the benefits of cone beam computed tomography (CBCT) in diagnostics and the numerous innovative options they provide for planning and conducting therapies. The Low Dose mode unlocks a simple option for treatment monitoring with low dose radiation.

Impacted and displaced teeth are no rarity at an orthodontic practice. Third molars and upper canines are most often affected. Surgical exposure of upper canines and the subsequent orthodontic tooth alignment are routine surgeries in dentistry. To make the procedure as atraumatic as possible, the position of canines should be precisely determined and verified by means of a CBCT to ensure problem-free treatment, as shown in the following case report.

Particularly in growing patients, which represent the majority of orthodontic patients, the radiation exposure should be selected as low as possible. Here the Low Dose mode offers a new radiation-minimizing option.

In this particular young patient, the lower left canine was diagnosed and found to be displaced. Many such cases require orthodontic therapy to elongate the impacted tooth and align it correctly into the dental arch. For the further treatment of the displaced tooth, the attending oral surgeon opted to align the tooth by means of a fixed device using mechanical extrusion and a double arch technique, and took corresponding action by attaching brackets.

The perpendicular movement of a tooth requires the introduction of a vectorially directed, constantly acting force. The treatment is minimally invasive, time-saving, and atraumatic and is almost painless. Correspondingly, an extrusion pin was inserted on the displaced tooth and fixed to the tooth using a bonding technique and composite. The extrusion bar was fastened onto the brackets of the adjacent teeth.

Because of the determination of the position of canine-crown in relation to the roots of mandibular incisors (using CBCT in Low Dose mode) orthodontic biomechanics could be used. That almost completely prevented damage to neighboring roots (Fig. 1). Therefore, all the risks could be assessed

beforehand and the procedure made as atraumatic as possible for the patient. Thanks to the extrusion bar, the tooth was able to be successfully removed from the jaw (Fig. 3).

Using radiation-reduced CBCT datasets was advantageous with displaced canines in the treated case as it can supply valuable findings about the risks and prognoses of a possible attempt at alignment. Despite the X-ray dose being low, a clinician can get information which is impossible from 2D imaging. The procedure is easier to justify to patients and shows that a physician's duty of care is upheld.

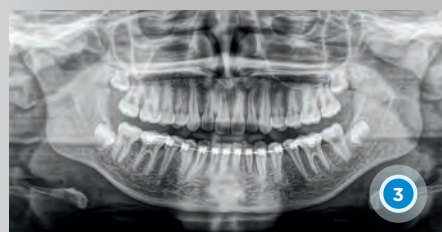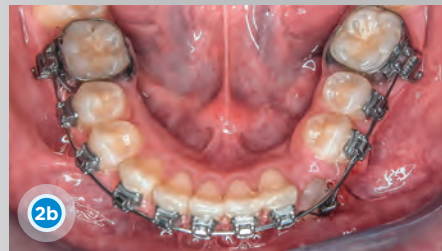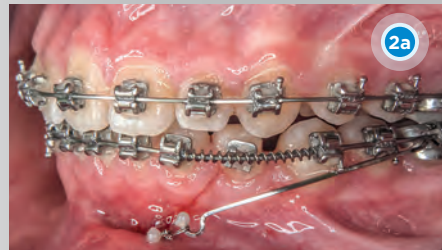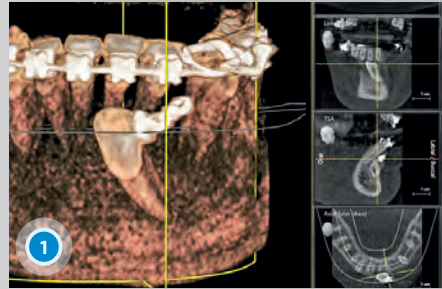


Fig. 1 Post-operative CBCT in the Orthophos SL Low Dose mode.

Fig. 2a and 2b Orthodontic alignment of the surgically exposed canine.

Fig. 3 X-ray overview image (Orthophos SL) after alignment of the lefthand lower canine and alignment.

HOW MODERN TECHNOLOGY MARKETS MY DENTAL PRACTICE

Author Dr. Salvador Insignaris, Cartagena, Colombia

People prefer to buy from market leaders. This principle can also be applied to dental practices. For a dentist working in Colombia in dental prosthetics and implantology who wants to establish himself as a dental service provider at the top of the competition pyramid, the creation of a unique selling proposition is the first priority. The ability to provide high-quality dental services in the shortest possible time formed the basis of this business vision.

In order to achieve this goal for the practice and to offer patients easier and faster treatment, the first step was to unite several treatment centers in a single location for various special applications such as prosthetics, endodontics, periodontology, orthodontics and dental surgery.

The second step was to set up a laboratory equipped with the latest CAD/CAM technology, which was integrated into day-to-day practice. Based on the scientific literature, the choice fell on the CEREC system from Dentsply Sirona, the gold standard in precision and speed. I chose a premium package including Omnicam and the CEREC MC XL milling unit with the software version 4.0 and later updated to ver-

sion 4.5. These tools made it possible for me to fabricate restorations for my patients using a wide variety of materials on natural teeth or implants that fully meet the requirements for functionality, structural strength and esthetics.

This technology also opened up another field of business: the production of transparent Aligner splints for gentle correction of tooth misalignments. When dental colleagues outside my practice heard about my modern laboratory, I unexpectedly began to receive orders to make restorations for them. Thanks to CAD/CAM technology, this further increased the efficiency of my practice and provided my dental technicians with an additional incentive.

The third step was to integrate a fully digital radiology center through the purchase of the Orthophos 2D/3D in order to meet all the imaging requirements for the treatment of my patients in implantology, periodontology, endodontics, orthodontics and dental surgery. Having this technology at our disposal motivated my team. Dentsply Sirona was able to offer my practice integrated implantology and the associated high reliability of a perfectly coordinated workflow without the need for adjustments to be made between

different manufacturers or conversions due to incompatible formats or archives.

Today my patients are happy to be treated in a dental practice equipped with the latest technology and in which Sinius CS treatment centers offer them comfort and relaxation (Fig. 1). In terms of comfort, impression-taking of the teeth with elastomers is a thing of the past as the Omnicam intraoral camera has greatly improved this part of restoration treatment for patients. In addition, restorations are now made and inserted for the first time within one day.

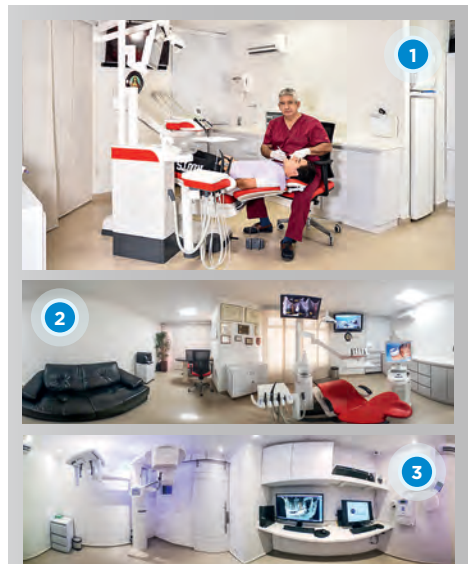We plan implants using the Galileos Implant planning software in the presence of the patient, which ensures greater trust and makes our professionalism tangible for the patient. In this way, the patient can clearly see the difference to other practices so that treatment costs become a secondary concern (Fig. 2). Depending on the patient, radiographs, digital impressions, implant planning, the fabrication of surgical guide rails as well as temporary implants and prostheses are possible within one morning or afternoon. Only more complex individual cases require more time.

I was able to achieve a return on investment through various strategies that have a positive effect on our patients. Everything can be done within the practice including X-ray examinations and their findings (Fig. 3). The high-tech dental laboratory, in which restorations are fabricated in a few minutes under the strictest quality controls, is also used for implant planning and manufacture for the flapless procedure, resulting in a reject rate of zero. Our lab also enables individual coloring of the restorations and reworking for optimum adaptation. The dentist and dental technician are involved throughout the entire procedure.

Fig. 1 Dr. Salvador Insignaris at his Sinius CS treatment center.

Fig. 2 One of Colombia's most modern practices with the complete integrated workflow of Dentsply Sirona.

Fig. 3 The X-ray and diagnostic room featuring Orthophos SL.



HOW ORTHOPHOS SL 3D CHANGES PRACTICE LIFE

Author Dr. Imre György Borzási, Budapest, Hungary

I have been working with oral surgery for 20 years and with implantology for 15 years. Around the time that the editing software using CBCT scans for creating dental surgical guides first appeared, I was just starting to get acquainted with the 3D imaging technique.

Initially, the number of enterprises specialising in CBCT increased dramatically, and the first devices appeared in the major clinics. Soon after, manufacturers improved image resolution, offered selectable fields of view, introduced 3D Low Dose and software with extended ranges of capabilities. What kind of changes could we expect in the life of the practice? Among the most significant are the ability to provide an almost immediate diagnosis of uncertain cases, create a treatment plan accordingly, as well as to be able to show the patient the cause of the necessary intervention. The introduction of Orthophos SL 3D represents the greatest progress in my practice. When we cannot identify the cause of complaints through a traditional patient examination and the X-ray images taken by us or by others do not show any deformation, then it is appropriate to capture a CBCT image. Over the past year, the 3D imaging method provided completely clear answers to the origin of complaints and indicated the necessary therapy.

Sándor, 64 years old, has been wearing an upper circular bridge, free of symptoms for 8 years. In the course of the annual screening test, a panoramic X-ray image was taken which indicated periapical mutation around region 27 (Fig. 1). Questions arose immediately such as: What is causing the mutation? How many and which roots are involved and whether bifurcation is concerned? Can the mutation be treated surgically or is the bone structure of sinus maxillaris l.s. preserved? The CBCT image made clear that the tooth could not be saved despite the correct root treatment in the palatal canal and also in the buccal canal. The presence of bifurcation and the defect of bone structure in sinus maxillaris anticipates the need for removal of the tooth and subsequent reconstruction.

Mónika is a 42-year-old patient who came with tooth sensitivity (tooth 15). Taking a 2D image was not an option so we immediately captured a CBCT scan (Fig. 2) because of the tooth mobility and in view of the patient's request. She wanted to fill the gap with an implant after a potential tooth loss. Contrary to the previous case, the imaging technique here was not needed in order to decide upon tooth removal, however it was a great help in planning the reconstruction. The preserved buccal

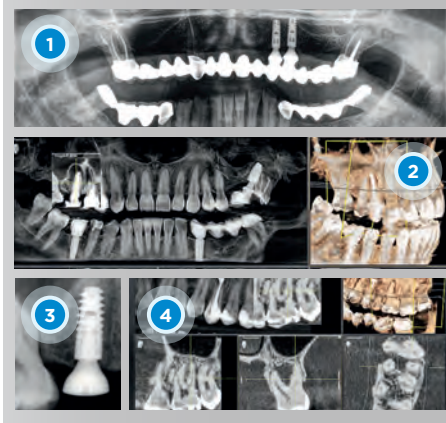


Fig. 1 The panoramic X-ray image (Orthophos SL) shows a periapical mutation around region 27.

Fig. 2 The scan of tooth 15 (Orthophos SL) shows a preserved buccal bone wall and the intact sinus.

Fig. 3 The image shows the control RVG after 2 months healing.

Fig. 4 The CBCT image (Orthophos SL) showed serious bifurcation on 27.

bone wall and the intact sinus were the key pieces of information in treatment planning. The scan shows the result of the tooth removal and the socket preservation 3 months following the intervention. Orthophos SL 3D now makes it possible to take a control scan in Low Dose mode. The implant was inserted on the date of the scan. An impression was also taken on the same day and 10 days later (Fig. 3), an Atlantis individual suprastructure and zirconia ceramic crown were placed. The patient visited our practice 5 times spending less than 5 hours in the practice in total. Within a short period of time, we managed to create an appropriate restoration from a near-loss situation.

Katalin is in her thirties. In the course of a screening test, I asked about a lilac pinhead size dot on her palate around teeth 27-28. She said, that occasionally she had a tiny swelling on her palate for several years, without any toothache. Tooth 27 is definitely vital, 28 is uncertain. The X-ray

image which she brought indicated the likelihood of periodontal origin, which seemed to be confirmed by the palatal probe analysis up to a depth of 7 mm. The CBCT image (Fig. 4) showed serious bifurcation on 27 however, the panoramic X-ray showed neither the bifurcation nor the nearly 9 mm horizontal defect. Two months after the extraction of 28, the fistula disappeared without any trace. Tooth 27 remained vital, not movable, and the patient is asymptomatic. In another two months we will take a low dose control scan.

In conclusion, precision imaging techniques with high resolution and excellent image quality provide reliability for the dentist in regard to diagnostics, treatment planning and even investigating complaints with an uncertain origin. Ensuring predictability is desirable to the patient during both long-term and short-term therapies. Such predictability has the added benefit of attracting patients to our practice.

IMPLANT PLANNING IN LOW DOSE MODE

Authors Marko Ahonen, DDS, and Katariina Ahonen, DDS, Hämeenlinna, Finland

3D imaging is changing the way we practice as dentists, making us more efficient and also improving communication with the patient as well as safety.

As the first practice in our area to offer digital dentistry, many of our first-time patients come to us never having experienced this kind of dentistry before. They are informed and eager to take advantage of its benefits. When working with new patients on implant procedures, we prefer to take larger images (\varnothing 8 x 8 cm or \varnothing 11 x 10 cm) to check for infections, as identifying these is important for their overall health. The Low Dose mode of the Orthophos SL is ideally suited for this purpose as you can take larger 3D images that provide superior information but still maintain a lower radiation dose that is acceptable for the patient.

A 70-year-old male patient came to our practice for an implant consultation because he was missing teeth 25, 26, and 35. With the digital workflow, these consultations typically last only about 30 minutes. The initial steps involved using a CEREC Omnicam to take digital impressions and an \varnothing 8 x 8 cm image taken with the Orthophos SL in Low Dose mode. Prosthetic planning was then done using the

CEREC chairside software. The next step combines the CBCT imaging with the prosthetic planning. Once the surface model is superimposed with the CBCT, it becomes easy to form a plan for ideal implant placement in the Galileos Implant software. CEREC Guide 2 surgical guides were designed using chairside software and milled in our practice. A small crestal flap was raised and fully guided osteotomy was performed. An internal sinus lift was performed on site 26. For this patient, Astra TX 5/9 and 5/11 implants were used. After an initial healing period of three months, I performed the final intraoral scans for the prosthetics using the CEREC Omnicam. All three implant positions were scanned and the prosthetic designs were planned simultaneously without any physical models. Ideally positioned fixtures enable ideal prosthetic planning and screw-retained monolithic restorations. The prosthetics were delivered without any modifications intraorally.

A final intraoral X-ray six months after the implant crown delivery showed that the planning had been implemented successfully with ideal positioning of the implants and bone level. The result was a very successful outcome for the patient.

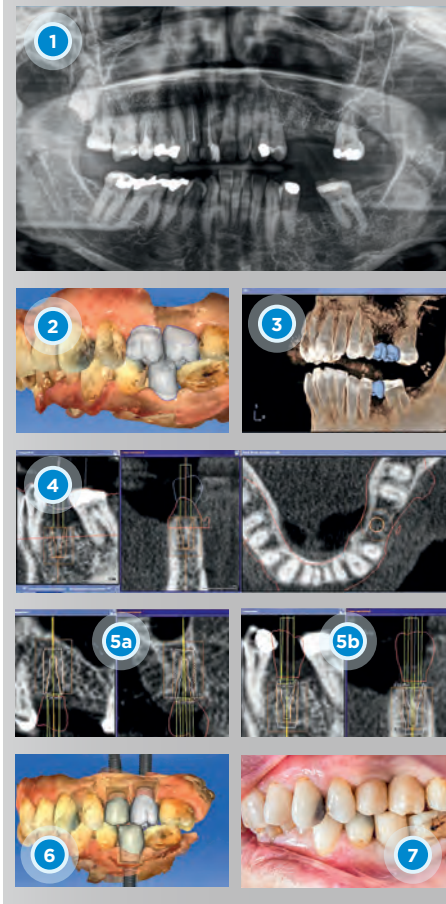


Fig. 1 Panoramic image showing the initial situation: patient missing teeth 25, 26 and 35.

Fig. 2 Prosthetic planning was done with CEREC chairside software.

Fig. 3 The prosthetic planning is matched with the Low Dose CBCT image in Galileos Implant. The result shows precisely the position of the bone.

Fig. 4 Upper jaw: once the surface model is matched with the CBCT in Galileos Implant, it is easy to see where bone and soft tissue goes and therefore possible to plan for ideal implant placement based on bone, soft tissue and prosthetic plan.

Fig. 5a and b Only minimal deviation between the planned (orange) and placed (white) implant fixture can be seen on the pictures (a region 25, b region 35).

Fig. 6 Final intraoral scanning for prosthetics was performed using Omnicam. All three implants were scanned and the prosthetic designs were planned simultaneously without any physical models.

Abb. 7 Final situation: prosthetics were delivered without any modifications intraorally.

Compared to traditional methods, Orthophos SL CBCT improves planning efficiency and also benefits the patient in terms of comfort and safety. Using a 3D printer, the surgeon can even build a 3D model from the digital imaging data to practice for the specific surgery.

Patients often want to know the answers to three important questions:

- will the procedure hurt?

- how much time will be needed to achieve the final restoration?
- how much will it cost?

CBCT gives the clinician the information needed to answer these questions during the initial consultation. Particular challenges can be identified in advance, resulting in a more predictable outcome and a better-informed patient who is more likely to accept the proposed treatment plan.

SECURE IMPLANT PLANNING WITH ORTHOPHOS SL

Author Dr. Andrey Zherebtsov, Moscow, Russia

A 42-year-old female patient complained of looseness of tooth 24. After consultation, the patient had a CBCT taken using Orthophos SL. The CBCT identified a fissure of the palatine root of tooth 24 (Fig. 1). Upon further examination, a disassembled orthopedic structure was removed from tooth 24 revealing a longitudinal fracture of the palatine root. The patient planned to undergo an implantology treatment.

Treatment began with the virtual implant planning and manufacturing of a surgical guide; the future orthopedic structure is designed first (Fig. 2). Using this approach, the optimal position of the implant is determined not only by the anatomical conditions of the bone tissue, but also in respect to the characteristics of the orthopedic structure.

Choosing the best implant diameter depends on the bone density and the relationship between its cortical and spongy parts. The cortical part of the bone is responsible for the primary mechanical stability of the implant, while the spongy part determines the blood supply necessary for successful osseointegration. The angulation of the implant largely determines its spatial orientation in the bone tissue and the relationship with the orthopedic structure. Angulation of the implant should take into account the direction of the

occlusal forces, which in an ideal position of the infrastructure should be directed along its long axis. Thus, the center of the implant and the hole for the screw onto which the orthopedic structure is fixed need to coincide with the position of the central fissure in the area of the chewing teeth. Occlusal forces are directed strictly along the axis to the support role of the antagonist tooth. The depth of implant placement is influenced by the distance to the proximal contacts and the presence of at least 1 mm of bone around the implant. The implant platform should be no more than 5 mm from the proximal contact area, in which case it is possible to predict the aesthetic formation of the gingival papilla. In this case, the implant was placed distally, close to the root of tooth 25.

The implant planning report shows all characteristics, not only of the implant but also of the working length of the cutter (Fig. 3). In transverse sections with a step of 1 mm, it is possible to analyze the relationship with adjacent teeth (± 3 mm from the center of the implant). The virtual implant is visualized within the CEREC software for modeling and manufacturing the surgical guide. With the guide ready, it was possible to start the surgical intervention and extract tooth 24. The fit of the guide was checked through

the inspection windows and a guiding key for drilling was installed in the surgical guide to help carry out pilot drilling.

A closed sinus-lifting was performed simultaneously with the expansion of the implant bed. Since the height of the bottom of the maxillary sinus did not exceed 2 mm, the material for augmentation was not used. The implant had a diameter of 4.5 mm and a length of 11 mm and was installed with a standard guide and a 3 mm diameter guide wire with 50 Ncm torques. X-ray confirmed that the implant was placed in accordance to the virtual plan (Fig. 4).

The titanium base (CEREC TiBase) is then installed with a scan body for a post-op intraoral scan. Thanks to its shape, it conveys information about the spatial position of the implant. Based on the data, a temporary orthopedic structure (CEREC) is modeled and the restoration enters the milling stage with CEREC MC X or MC XL. The temporary construction is affixed to the implant platform and an X-ray image is taken. The patient returns for a second exam after 14 days.

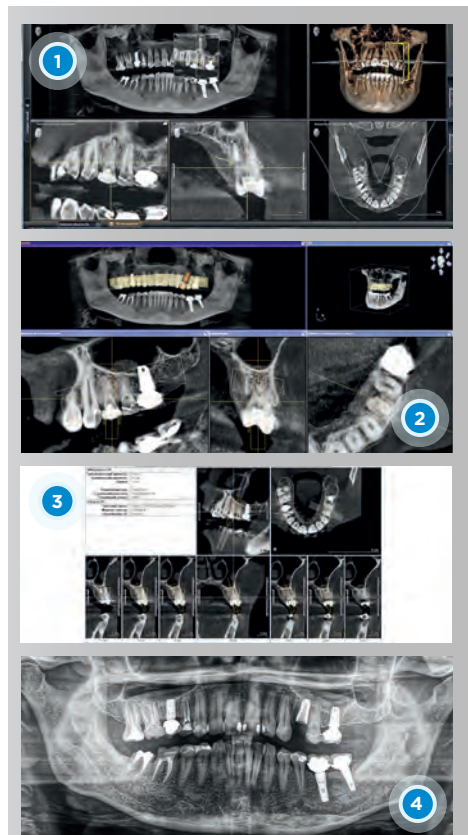
Integrated implantology uses high-quality diagnostics to create an accurate treatment plan and to objectively monitor the treatment process to achieve functional and aesthetic results. It provides an optimal and comfortable process for treatment while reducing costs by saving clinical time for the dentist.

Fig. 1 The CBCT (Orthophos SL) of the initial situation shows a fissure of the palatine root of tooth 24.

Fig. 2 Virtual implant planning in Galileos Implant as basis for the manufacturing of the surgical guide.

Fig. 3 The implant planning report.

Fig. 4 CBCT of the final situation. Implant is placed in accordance to the virtual plan.



MAXILLARY SINUS FLOOR ELEVATION AND DENTAL IMPLANT PLACEMENT

Author Prof. Dr. Yucheng Su, Beijing, China

A 63-year-old male patient had a chief complaint of distending pain and discomfort in the right upper posterior teeth for over one month. A CBCT scan (Orthophos SL) showed, on 16, large-area absorption of alveolar bone, root resorption, an incomplete bottom bone plate of the maxillary sinus, and mucosa of about 1.5 mm thickness (Fig. 1a and 1b). The molar could not be preserved. A maxillary sinus floor surgery and implant strategy was established. The patient understood and accepted the treatment plan.

Local anesthesia was administered in the vestibular groove and palatal side of tooth 16. After the separation of the gingiva, the roots were all removed. After scraping the granulation tissue in the lateral wall, hemostatic sponges were used to fill the tooth extraction socket. After suturing the tooth extraction wound, an Orthophos SL CBCT Low Dose scan was used immediately (Fig. 2). There was no residue of broken root or dental film in the tooth extraction socket. Osseous plate discontinuity of the tooth extraction socket was observed, without fluid present at the bottom of the sinus. The suture was removed one week later and the extraction wound had healed well.

Three months later, an Orthophos SL CBCT High Definition scan revealed severe alveolar bone loss in the tooth 16 extraction site, severe insufficiency in the vertical bone height, slightly low bone density, normal maxillary sinus gasification, no obvious thickening in the mucosa of sinus floor, moderate thickness of the lateral wall of bone plate, and no larger blood vessels. The operation plan foresees lateral sinus floor elevation, GBR and implant placement in 16.

The postoperative CBCT examination provided easy judgement for the postoperative condition (Fig. 3). The three-dimensional position of the implant was satisfactory. It could also be observed that the mucosa of the sinus floor had been lifted by the bone graft material without fluid present in the maxillary sinus. The operation achieved the desired effect and the patient was satisfied with the surgical outcome.

During the process of implantation in the maxillary posterior teeth area, significant difficulties can arise. It is imperative that the maxillary sinus be taken into account. Bone mass, anatomic morphology, position of the sinus floor, health of the sinus

mucosa, bone thickness of the lateral wall, and distribution and direction of blood vessels are all critical pieces of information. CBCT significantly benefits the assessment of the initial diagnosis, the selection of the operative procedures and the evaluation of the results post-operation. Orthophos SL is capable of different modes to meet the different needs of diagnosis and treatment.

To be specific, Standard Definition (SD) supported our case in the course of the primary examination where we wanted to obtain a survey of the full oral health information of the patient. After tooth extraction, we were interested in seeing whether there were residues in the tooth extraction socket as well as the basic condition of the alveolar bone plates - information we were able to get with the Low Dose mode at only 20 micro Sievert. In addition to bone quality and quantity at the site of tooth loss, there was a need to acquire image information in the maxillary sinus area. This could be clearly obtained using the High Definition (HD) mode.

To summarize, with Orthophos SL, the needs of different stages of examination can be met with minimal patient exposure, so as to provide the surgeon with the opportunity to minimize the risks of operation under predictable conditions and achieve the desired therapeutic effect.

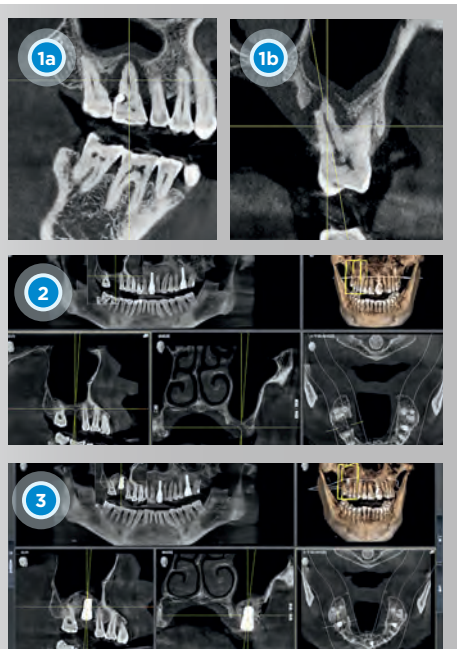


Fig. 1a and 1b Pre-operative CBCT assessment of the affected area.

Fig. 2 Immediate CBCT examination after tooth extraction.

Fig. 3 Post-operative CBCT examination.

NOTES

A series of 20 horizontal dotted lines for writing notes.

NOTES

.....

.....

.....

.....

.....

.....

.....

.....

.....

.....

.....

.....

.....

.....

.....

.....

.....

.....

.....

.....

.....

.....

Publisher

Dentsply Sirona
Sirona Straße 1
A-5071 Wals/Salzburg (Austria)
email: contact@dentsplysirona.com
Telephone: +43 (0) 662 24 50-0
Telefax: +43 (0) 662 24 50-510
www.dentsplysirona.com

Responsible under german press law

Franziska Riversa, Guenther Schmidhuber,
Dentsply Sirona

Editorial and design

Edelman GmbH
Schöneberger Straße 15
D-10963 Berlin, Germany
www.edelman.de

Photo credits

Page 4, 5: lukbar / iStock / Getty Images Plus

Special thanks also to:

Katariina Ahonen, Marko Ahonen,
Dr. Imre György Borzási, Dr. Heinrich
Dippenaar, Dr. Erin E. Elliott, Dr. Gertrud Fabel,
Dr. Ayse Ceylan Ilhan, Dr. Salvador Insignaris,
Dr. Prashant Jaju, Dr. Sushma P. Jaju, Dr. Björn
Ludwig, Dr. Fabienne Oberhansl, Dr. Dr. Lutz
Ritter, Prof. Dr. Yucheng Su, Dr. Jörg Tchorz,
Dr. Andrey Zerebtsov

Printing

Königsdruck
Printmedien und digitale Dienste GmbH
Alt-Reinickendorf 28
D-13407 Berlin

Subject to technical changes and errors in
the text, Order No. A91100-M47-C073-01-7600,
Printed in Germany, Dispo-Nr. 04602,
Koenigsdruck19 WS0119.V1

All reproduction of contents, even excerpts thereof, must be accompanied by a source attribution. Not all products are available in all markets. In order to improve readability, ™ or ® is not used in the running text or on pictures. By doing so, however, Dentsply Sirona does not waive any rights to its trademarks. The provisions of the individual countries apply. Subject to technical changes and errors.



Orthophos SL

The overall imaging solution

Orthophos SL provides one of a kind solutions for a number of treatment situations. It features the highest image quality, well-conceived operation, and reliability “made in Germany.” Smart tools like the 3D Low Dose mode, which offers indication-based 3D X-rays in a 2D image dose range, add an additional layer of options for your best diagnosis. Together with the award winning Sidexis 4 X-ray software, the Orthophos SL is the overall imaging solution for your practice.

dentsplysirona.com

A91100-M147-C073-01-7600

THE DENTAL
SOLUTIONS
COMPANY™

 Dentsply
Sirona