

An IPS e.max CAD single crown – First upper molar in 60 minutes

Case Description

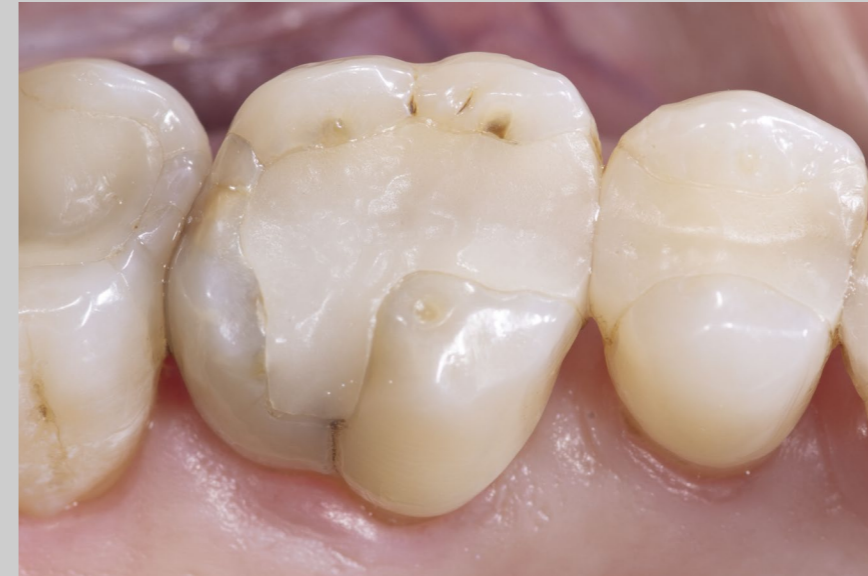A female patient, 47 years old, presented with a slightly intermittent sensitivity to cold at tooth 16. The clinical examination as well as the radiological findings indicated a large insufficiency of the composite filling, with distal marginal ridge cracks, a lingual wall crack, and distal recurrent decay. The tooth was not sensitive either to percussion or palpation, and showed no signs of apical inflammation. A cracked tooth syndrome was diagnosed. Due to the size of the filling and the caries to be treated, a core buildup and a full cuspal coverage ceramic crown restoration was planned. After local anesthesia with 4% Septocaine® (1:100,000 epi), we selected the material and the color for the restoration: IPS e.max CAD MT A3. Prior to the preparation and design of the new restoration, my assistant prepared the CEREC Primemill by inserting the block and starting the pre-touch process. After the initial scan of the upper and lower jaw with CEREC Primescan, I removed the filling. This confirmed the initial diagnosis of a fracture in the lingual wall. Following the excavation, I applied a composite core buildup (3M Vitrebond, Empress Opaque, Ivoclar Vivadent). In this case, I was able to complete the preparation in a way that the enamel was retained in the buccal wall. Subsequently, I took a new digital impression with the CEREC Primescan. I then defined the preparation line in the digital model. The CEREC Software provides excellent support in this respect. I was satisfied with the first restoration proposal, which I accepted without any changes. During the design phase, I paid particular attention to the fissure height and contours, the correct occlusion, and the contact points. After grinding with CEREC Primemill, I crystallized and glazed the crown. I performed a quick final check and could place the crown using adhesive. The patient was very happy with her experience and grateful for being able to have her tooth restored with a permanent, strong, and highly esthetic crown in a single visit that took just over an hour. Since then, she has been completely free of symptoms.

Discussion

The clinical case demonstrates how quickly and efficiently the new CEREC Primemill allows a full-surface glass-ceramic crown to be fabricated chairside in a single session, while meeting a high level of esthetic demands. I can no longer imagine practicing without CEREC Primemill.

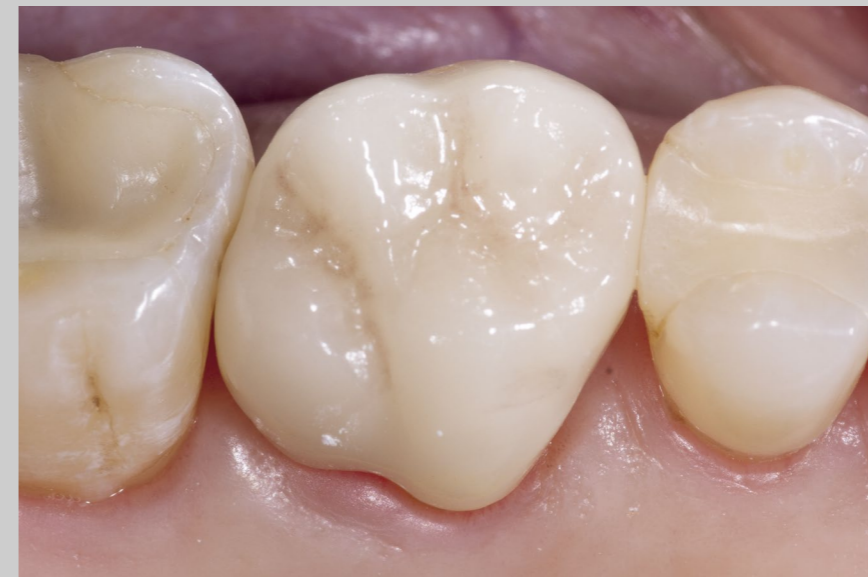

Dr. Karyn M. Halpern DMD, MS
New York, USA



Before:

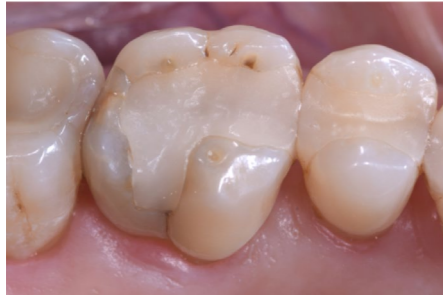Large insufficiency of the composite filling on tooth 16 with distal marginal ridge cracks, a lingual wall crack, and distal recurrent decay.



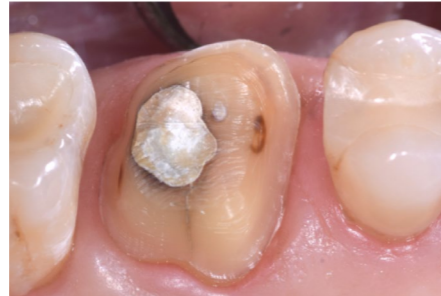After:

Highly esthetic full-surface glass-ceramic crown.

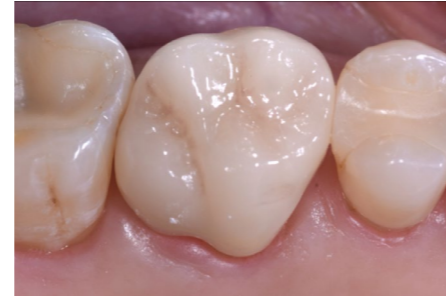Clinical Images



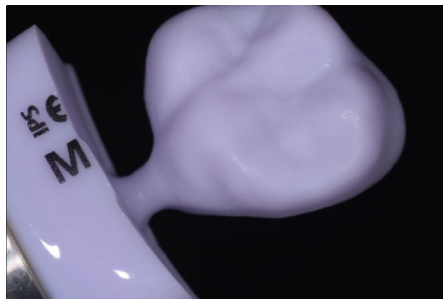The patient presented with a chief complaint of mild intermittent sensitivity to cold beverages and pointed to tooth 16.



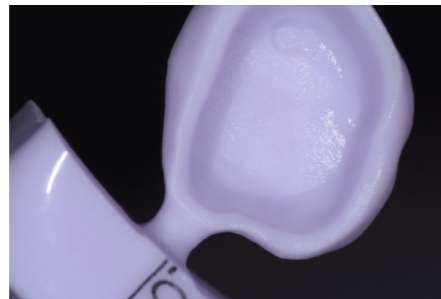The previous failing restoration was removed, and both mesial and distal recurrent decay was found and excavated. No pulp was exposed upon completed excavation. A composite core buildup was completed using a glass ionomer liner (3M Vitrebond) and composite resin (Empress Opaque, Ivoclar Vivadent).



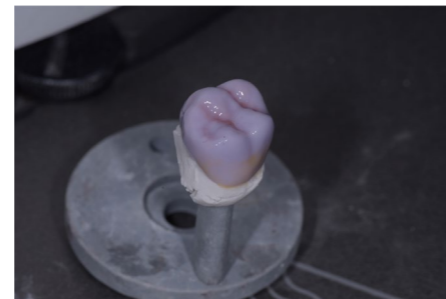After crystallizing and stream cleaning the restoration, the e.max CAD was prepared for bonding and bonded with resin cement.



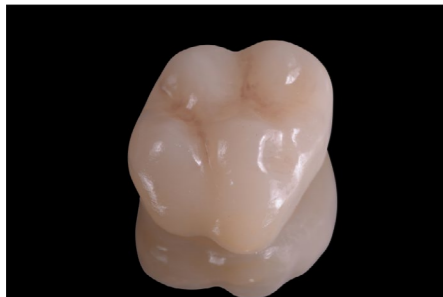The local parameter marginal thickness was adjusted to 100 µm. The design phase was then completed with very little modification to the fissure height and contours. The design was evaluated for proper occlusion, contacts and contours.



Since the touch process had been completed in advance, the grinding began right away after the restoration was sent to the CEREC Primemill. The e.max restoration was grinded in 3:54 without any marginal chipping. The fit was checked, and no further adjustments were needed.

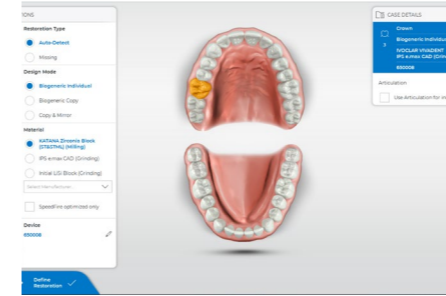


The restoration was then glazed and stained using Ivoclar Vivadent IPS e.max CAD Crystall Shades, Stains and Glaze Paste.

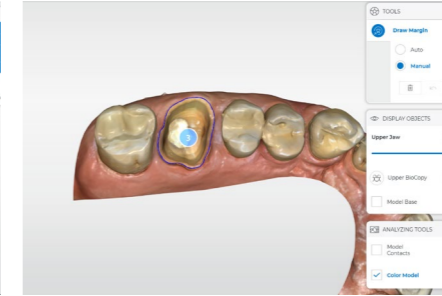


It was then crystallized in a furnace.

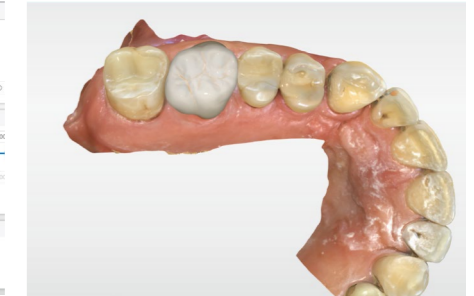Workflow Images



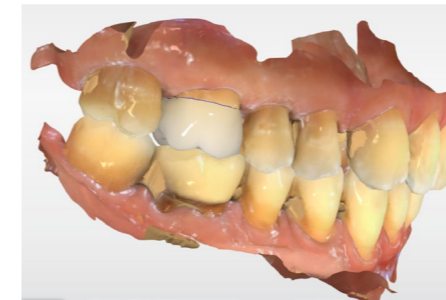The patient information and the Administration Phase was completed, designating IPS e.max CAD for the restoration.



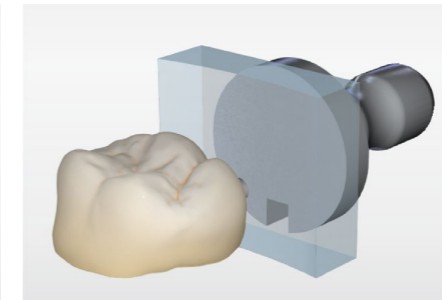
Automargination was completed by the software and no modifications were needed.



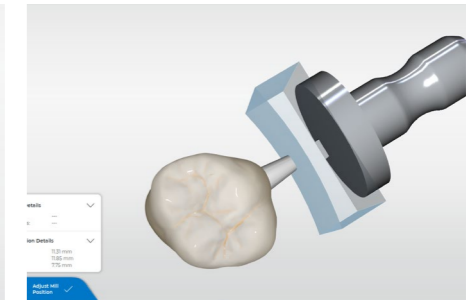
Design proposal.



The design was evaluated for proper positioning, contours, occlusion, and contacts.



In the Manufacture Phase the sprue was automatically proposed on the lingual surface.



The restoration was then sent to the CEREC Primemill.