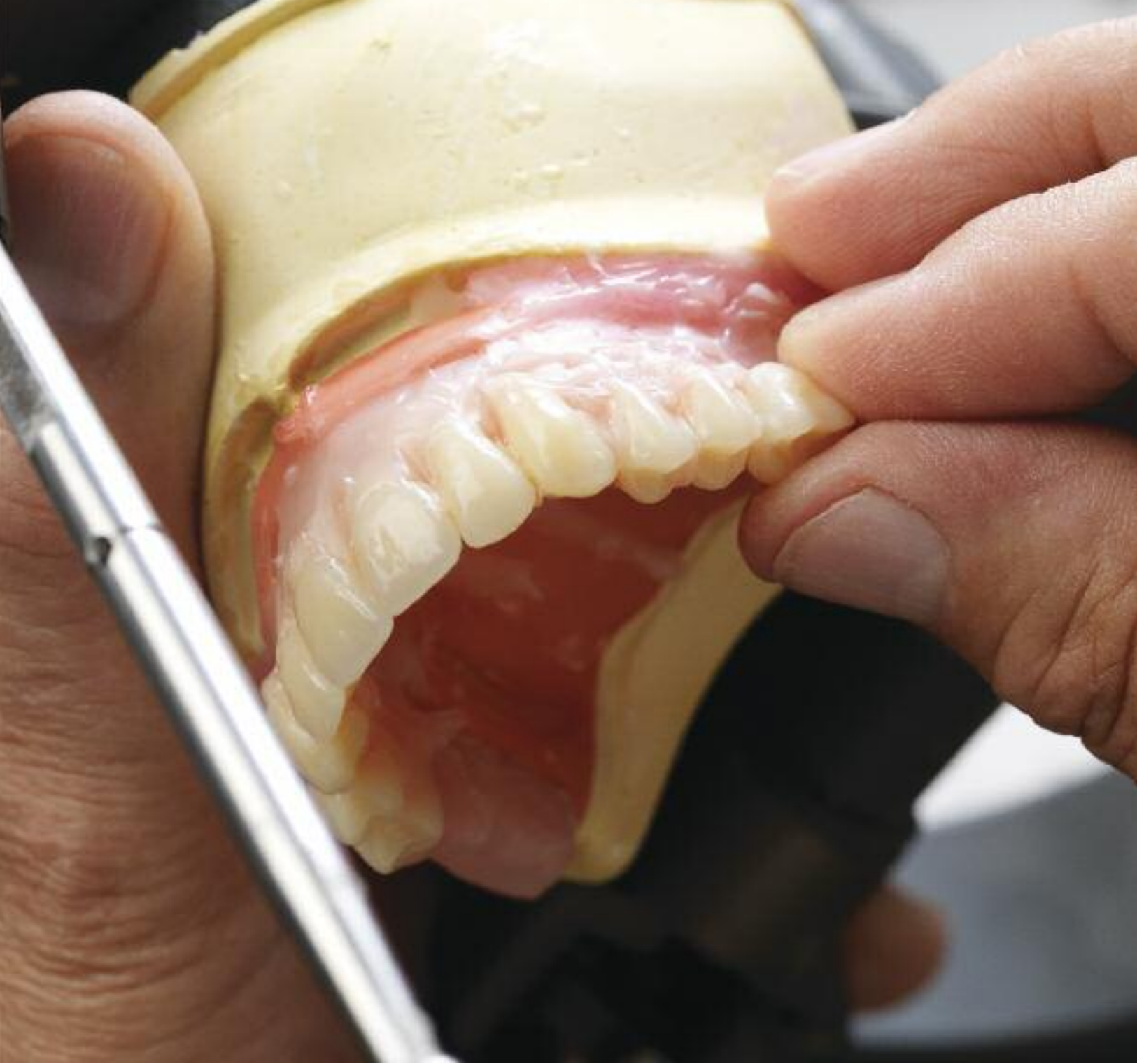



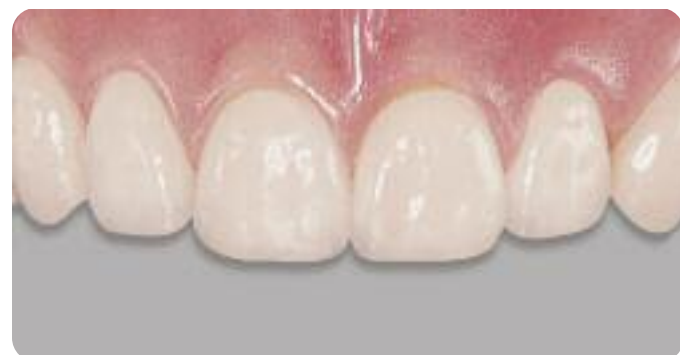## Anterior & Posterior Tooth Arrangement Manual

---

# Suggested procedures for the arrangement and articulation of Dentsply Sirona Anterior and Posterior Teeth

Contains guidelines for use, a glossary of key terms and suggested arrangement and articulation procedures

Table of Contents	Pages
Anterior Teeth.....	2-8
Lingualized Teeth .....	9-14
0° Posterior Teeth .....	15-17
10° Posterior Teeth.....	18-20
20° Posterior Teeth.....	21-22
22° Posterior Teeth.....	23-24
30° Posterior Teeth .....	25-27
33° Posterior Teeth.....	28-29
40° Posterior Teeth.....	30-31
Appendix.....	32-38



# Anteriors

## Description:

Exceptional aesthetics, plus an infinite variety of moulds to satisfy any need.

## Indications For Use:

Any full or partial denture case; also ideal for use in implant prosthetics and provisional restorations.

## Factors to consider in the Aesthetic Arrangement of Dentsply Sirona Anterior Teeth

### Natural antero-posterior placement of maxillary anterior teeth

Antero-posterior positioning of anterior teeth is an important factor in aesthetics since the teeth give support to the lips, cheeks, and other tissues of the oral cavity. The replacement of artificial teeth in the original position of the natural teeth is frequently not stressed or simply overlooked. Too often, resorbed residual ridges are used as the primary indicator for tooth position. Because of what may be extreme changes in shape and size, a resorbed, residual ridge is a questionable landmark for either functional or aesthetic tooth position.

Setting artificial teeth directly over the center of resorbed ridges makes the development of natural aesthetics extremely difficult to achieve. This is because natural teeth seldom occupy the so-called "over the ridge" position. Dental restorations, complete dentures in particular, will not normally be aesthetically pleasing if teeth are improperly positioned.

The loss of bone structure after tooth removal is usually greater on the buccal/labial aspects of the maxillary ridge than on the palatal aspect. Therefore, the ridge center is more palatal, smaller and different in shape than it was previously.

The overall heights may vary, depending on the anatomical differences between individual patients and on the degree of vertical overlap (overbite) incorporated into the anterior tooth arrangement. An accepted rule-of-thumb is discussed on page 3, bottom of column 2.



When using Dentsply Sirona IPN® Denture teeth, prior to placing teeth in wax, it is suggested the underside of the tooth be ground (deglazed) to remove the polished surface to enhance retention.

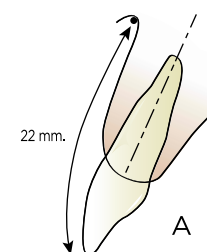
Ridge resorption is a major factor in the position of anterior teeth.



For natural aesthetics and phonetics, artificial teeth should be placed as nearly as possible in the same position antero-posteriorly, and be of the same length as the original natural teeth.

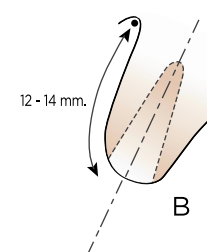
### Natural Tooth Position

"A" illustrates the position of the natural central incisor and its relationship to the ridge. 22 mm.



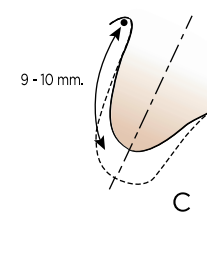
### Position After Loss/Removal

"B" illustrates the same ridge immediately after removal of the tooth. Dotted lines indicate position of the natural root. 12 - 14 mm.



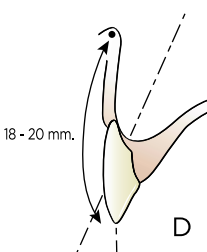
### Direction of Resorption

The direction of resorption is up and back. In "C", the solid line identifies the resorbed ridge; the dotted line, the original contour of the ridge. 9 - 10 mm.

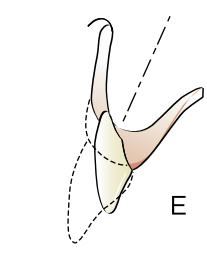


### Improper Positioning of Teeth

"D" illustrates one of the most common errors in anterior tooth positioning - positioning the teeth over the resorbed ridge without considering the original position of the natural teeth. 18 - 20 mm.



In "E," with drawing "A" superimposed over drawing "D," the denture with teeth set over the ridge is compared to the original position of the natural central. The loss of vertical dimension and lip support, and resulting loss in aesthetics, is the most common result.



The following matrix studies further demonstrate the relationship between tooth position and ridge resorption, and proper lip support:

Figure 1 shows a cross-section of the matrix and cast made before natural teeth were removed.



Figure 1.

In Figure 2, the cast has been trimmed to simulate a normal amount of ridge resorption in the anterior area.



Figure 2.

In Figure 3, a graphic illustration is provided of what happens to tooth positioning when the teeth are set "up and back" on the resorbed ridge.



Figure 3.

These figures illustrate the extent to which an artificial tooth set on the resorbed ridge may deviate from its true natural position. This "on the ridge" position of the teeth cannot provide proper lip and facial tissue support.



The measurements of 22 mm and 18 mm from the labial fold to the incisal edges of the maxillary and mandibular incisors respectively, are reasonable averages. These distances may be used as a guide for the length of wax occlusal rims in the anterior area, and positioning of the central incisor teeth for preliminary tooth arrangements.

### Proper vertical positioning of artificial teeth according to averages.

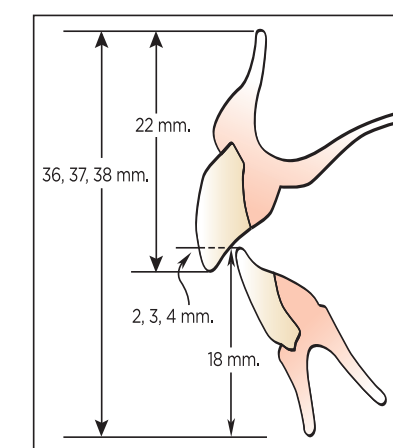


Figure 4.

(Note that the teeth in the schematic drawing above are labial to the residual ridges.)

## The relationship of the arch form to tooth arrangement

Nature tends to harmonize the form of maxillary centrals with the form of the face, the dental arch, and the arrangement of anterior teeth. Persons with dominantly square faces often have mainly square arrangements of mostly square-shaped teeth. In general these same harmonious principles also apply to the square tapering, tapering, and ovoid type.

**Key Tip** Mandibular ridge is used to determine arch form due to resorption of maxillary ridge.

### Tooth Arrangement in the Square Arch

In the Square Arch form, the two centrals are usually set to an almost straight line across the front of the arch. The laterals are also positioned with a nearly full labial aspect and exhibit very little rotation. This helps give prominence to the canines. The radius of square arches tends to be wider than, for example, tapering arches. This provides sufficient room for placement of the incisor teeth without crowding or lapping.

**Key Tip** Overall, in the Square arrangement the visual effect is fairly straight from canine to canine. The teeth also tend to be straight up and down, rather than sloping. The full or nearly full labial surface presented by all six anterior teeth gives a broad effect which is in harmony with a broad, square face.

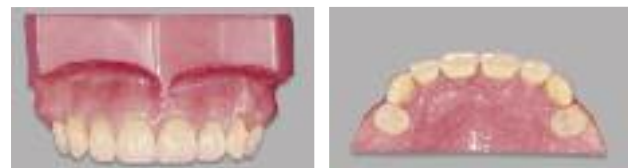

Figure 5. Mould 12G is illustrated.

**More Sources** Other appropriate mould forms are listed in the IPN Mould Chart, Reference #905473 and in the Individualized Anterior Arrangement brochure, Reference #3900.

### Tooth Arrangement in the Tapering Arch

A common feature here is the rotation of the centrals on their long axis inward at the distal, which sets the two teeth at an angle. Rotation and lapping of teeth is often observed because there is less space in this arch than in any other type, and crowding is a result. This often reduces the amount of labial surface visible.

**Key Tip** In the Tapering arch, the central incisors are often found to be a greater distance forward of the canines than in other types of arches.

A Tapering arrangement does not appear as wide as others, however, it is usually in harmony with the narrowing effect visible in the lower third of the tapering face. The laterals are often raised from the occlusal plane and depressed at the gingival. In addition, the necks of the canines at the gingival are often quite prominent. The incisal tips of the canines may be at the same height or slightly above the incisal edges of the laterals.

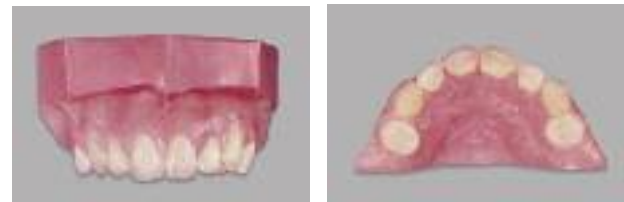

Figure 6. Mould 45F is illustrated.

A Tapering arrangement may also exhibit some "slope"; that is, the incisors of the centrals and laterals are projected forward, and the cervical area of canines is brought out.

### Tooth Arrangement in the Square Tapering Arch

The Square Tapering arrangement combines characteristics of the Square and Tapering forms, modifying both. It has a characteristic Square placement of the centrals, but is set in a "softer" arrangement. The Square Tapering arrangement may not exhibit the illusion of fullness or width as does the Square, and usually the canines exhibit more distal rotation than in a Square arrangement.

**Key Tip** The centrals are set prominently with the laterals and canines elevated. There may be little or no rotation of the centrals combined with a typical Tapering effect or rotation of laterals and canines.

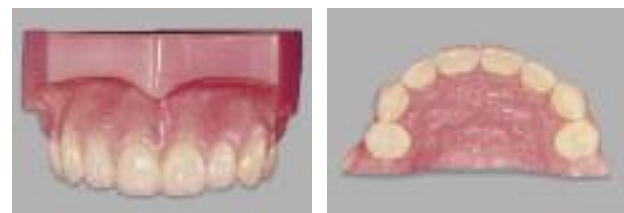

Figure 7. Mould 22G is illustrated.

### Tooth Arrangement in the Ovoid Arch

The Ovoid arrangement exhibits definite curvature; rotation is seldom observed.

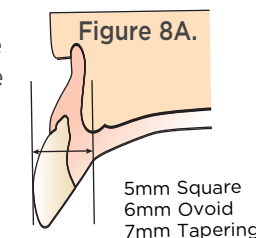
**Key Tip** The central incisors in the Ovoid anterior arch are often set well forward of the canines, in a position between that of the Square and the Tapering arches.

A typical Ovoid alignment shows a fullness of labial surface from canine to canine. This, in conjunction with setting the teeth to the curved arch, gives a broad effect that is in harmony with a round Ovoid face.

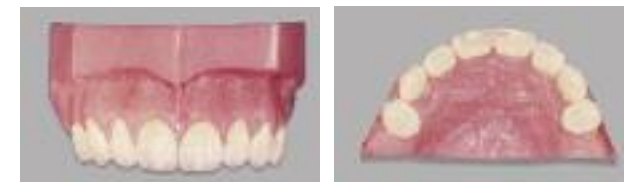

Figure 8. Mould 65G is illustrated.

Figure 8A illustrates the average antero-posterior distance from the center of the incisive papilla to the labial surface of the centrals, based on the tooth form selected.



### Basic placement of anterior teeth

There are five important factors involved in positioning anterior teeth:

1. Anterior slope - Labial inclination
2. Mesiodistal inclination - Mesial or distal tilt
3. Inferior-superior positioning to a horizontal plane - Above/below plane of occlusion
4. Rotation on a long axis - Turning tooth on its center axis
5. Antero-posterior positioning - How far labially or lingually (in or out) the anterior or posterior teeth are located

### Proximal View - Anterior Slope

On average, the central incisor, when set at approximately the same angle as natural teeth, will be at an inclination slightly offset from vertical. The incisal edge will contact the occlusal plane.

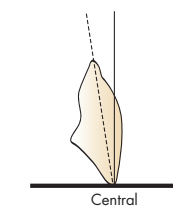


Figure 9A.

The slope of the lateral incisor is often slightly more accentuated than that of the central. The incisal edge of the lateral may be slightly raised (superior to) about 1/2 mm from the occlusal plane.

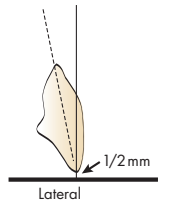


Figure 9B.

The canine may be set prominently, often to a line at right angles to the occlusal plane, with the incisal edge set on or slightly above the plane.

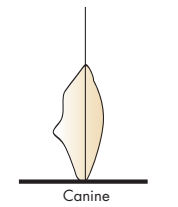


Figure 9C.

### Frontal/Facial View - Mesiodistal Inclination

The desirable angulation to the median line may be correlated to the form of the arch and of the tooth. Generally, the Square Arch form and tooth, and the Ovoid Arch form and tooth, may be set to approximately the same angulations.

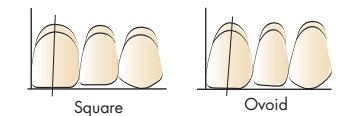


Figure 10A.

The Tapering forms are often set to a slightly greater angulation.

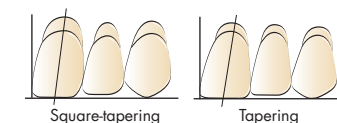


Figure 10B.

Any technique concerning the preliminary arrangement of teeth is based upon average conditions. Many times practical considerations dictate modifications in these methods in order to cope with individual differences in oral and facial anatomy. However, if basic principles are followed, they will be a workable foundation for a harmonious arrangement.

## Procedures

### Occlusion Rims

A wax occlusion rim is fabricated and defines the position, size and shape of the teeth to be replaced. Critical information about the patient's correct vertical dimension of occlusion, occlusal registration and the general arrangement of the denture teeth are indicated on the occlusion rims. From this wax "template", a technician can proceed to position and arrange the teeth in the initial set-up.

1. Place the central incisors in position with incisal edges touching the occlusal plane or a mandibular occlusion rim (Figure 11).

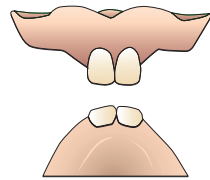


Figure 11.

2. Position the laterals with the incisal edge raised approximately 1/2 to 1 mm (Figure 12).

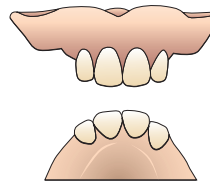


Figure 12.

3. Place the canines with the incisal tip close to or touching the occlusal plane, and tilt the cervical third buccally to give it prominence. Often, the mesiolabial aspect of the canine is visible when viewed from the anterior.

In nature, the position of the canine teeth plays an important part in the aesthetic appearance of the dentition. In a denture, they play an equally important role. They have aesthetic and functional influence on both the anterior and posterior tooth arrangements (Figure 13).

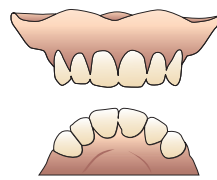


Figure 13.



More information regarding use of wax occlusion rims, waxing-up and general set-up guidelines are available in the Appendix, page 32.

### Positioning of maxillary canines

Figures 14 and 15 show the importance of the proper positioning of the upper canines.

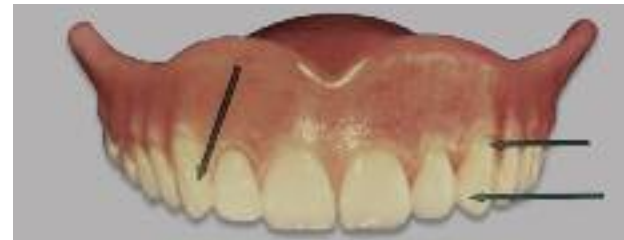

Figure 14. Viewed from the anterior, the mesiolabial surface of the canine is prominent, and the gingival one-third is positioned more facially than the incisal one-third.

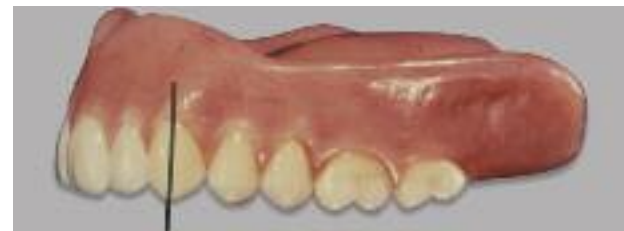

Figure 15. Profile or side view emphasizes the almost vertical long axis and position of the canine.

### Factors of softness and vigor

In nature there are a number of conditions which may be observed that directly affect the individual arrangement and aesthetic appearance of natural dentition.

Softness in a tooth arrangement is a reduction of the labial surface in terms of its visual appearance. A rounded mesiodistal curvature of the tooth combined with an ovoid outline of the tooth appears softer than a flat tooth with more angularity. A rounded form is far softer to the eye than a straight line or a flat plane.

A characteristic of the bold, vigorous face is the dominant size and alignment of the teeth. The relatively larger size of the lateral incisors and canines, and their straight bold arrangement, are important considerations in achieving the effect of strength. Vigor and boldness are not necessarily solely masculine characteristics, since strong, bold faces may be found in many female patients.

The following drawings illustrate the principle of tooth positioning for visual effect:

In Figure 16A, two central incisors are normally positioned. Viewed from the front, these teeth would look normal in their size or relation to each other.

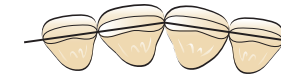

Figure 16A.

In Figure 16B, the two centrals have been positioned with the mesials slightly more prominent and with the distals rotated inwardly so they are less prominent. Viewed from the front view, the teeth in "B" would look smaller than those appearing in "A." The illusion is created by merely rotating the teeth, giving them a somewhat smaller and softer look.

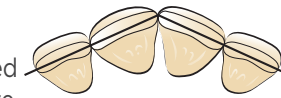

Figure 16B.

To further soften this effect, a rubber wheel may be used to round the distoincisor surface of either tooth, thereby introducing a slight degree of asymmetry.

In Figure 16C, the same two central incisors are placed to make the teeth look larger, creating the illusion of boldness or strength. This is accomplished by rotating the mesial in and the distal out to show more facial surface. If the laterals are also depressed slightly behind the centrals, the boldness of the tooth arrangement is further accentuated. This illusion may be made even stronger by grinding the teeth incisally to leave the distoincisor area prominent.

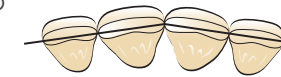

Figure 16C.

### Procedures to be observed in arranging the mandibular anterior teeth

Figures 17 and 18 show an anterior view of the lower anterior teeth arranged in average horizontal alignment of their incisal edges. Note that the long axis of the central incisors is perpendicular to the plane. The long axis of the lateral incisors is inclined slightly to the distal at the neck. The long axis of the canines is inclined more to the distobuccal at the neck.

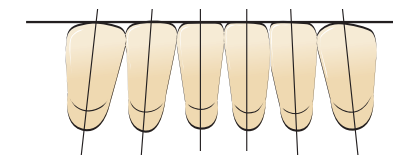


Figure 17.

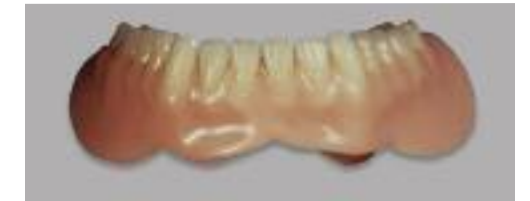

Figure 18.

Figures 19 and 20 illustrate how to achieve greater characterization; lower anteriors should be rotated and lapped with no two long axes of the teeth parallel to each other.

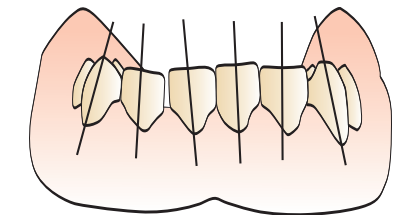


Figure 19.

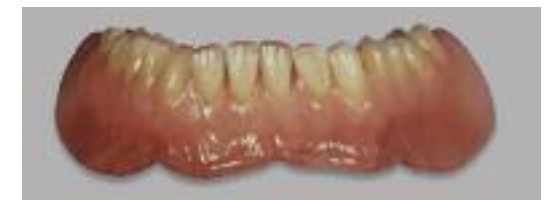

Figure 20.

The horizontal plane used for the alignment of lower anterior teeth may be above the occlusal plane, a distance usually described as the vertical overlap or overbite (Figure 21). The vertical overlap of the teeth may be influenced by the aesthetic and phonetic needs of the patient. Anterior teeth should also be arranged in harmony with various degrees of incisal guide table angulation.

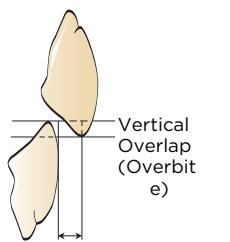


Figure 21.

Figure 22 shows a proximal view of the lower anteriors indicating their average antero-posterior inclinations to a horizontal plane.

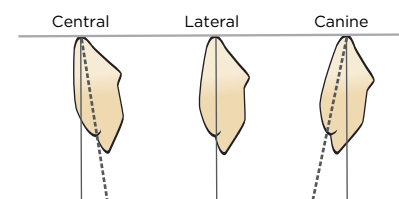


Figure 22.

## Overall evaluation of anterior tooth arrangement

Although there are varying methods and guides in the arrangement of artificial anterior teeth, it is the overall visual effect of the teeth in the mouth of the patient, created by their shape, size, color, and position, that determines acceptance or rejection. The teeth must fulfill the Aesthetic, Phonetic and Functional requirements of the individual patient. This is why a wax try-in and acceptance of the denture arrangement by the patient is so important.

A wide variety of patient communication materials and denture selection aids are available from Dentsply Sirona to help educate patients and assist in the delivery of essential information from the dentist to the laboratory.

## Dentsply Sirona Digital Prescription

Dentsply Sirona can help to simplify the denture process guiding the dental office through the key information laboratories need to make a high-quality denture. The Dentsply Sirona Digital Prescription App provides reliable options for teeth, moulds, and denture base; therefore, providing greater denture prescription detail from clinicians to dental laboratories and helping labs to more precisely manage tooth inventories. Download the app today!



## Asymmetry and its influence on tooth arrangement

Another aspect of interest in tooth arrangement is the relationship of facial asymmetry. Few faces will be observed with true symmetry of the left and right side. Many faces which appear on first observation to be symmetrical, on closer study will be found to have differences. Similarly, these differences may be observed in the arrangement of the teeth. (Compare Figure 21 with Figure 22.)

Asymmetry may be brought about by as little as the depression or rotation of a canine. At times it may be accompanied by a difference in the size of the laterals, or by positioning one central slightly anterior to the other. This is shown in natural dentition (Figure 22).

Characterization of artificial tooth arrangements - using asymmetry, spacing, crowding, lapping, and grinding modifications - should be approached with caution. Pre-extraction study casts and photographs are the best guides for these individualized touches. This is an area of complete denture treatment which is more in the realm of the artistic than the scientific and requires patient acceptance.

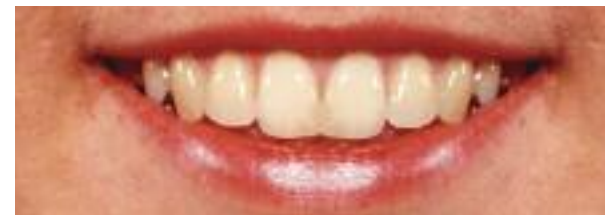

Figure 21. Smile created using only the right side of the natural smile in Figure 22.

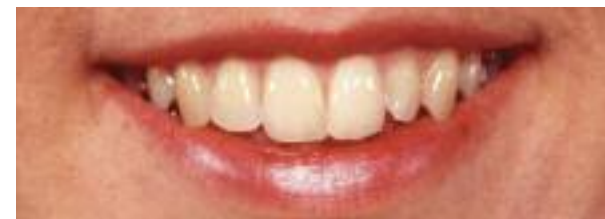
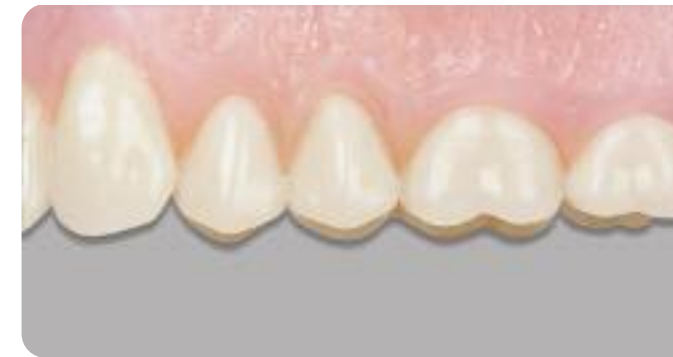
Figure 22. Natural smile showing asymmetry.



# Lingualized Occlusion Posteriors

## Description:

A posterior arrangement method that eliminates tooth contact points on the buccal cusps to assure seating and minimize tipping of the lower denture upon contact.

## Indications For Use:

Ideal for use with full dentures.

## Ridge Type:

- 30° or 33° - Healthy ridge with minor resorption.
- 22° - Moderately resorbed ridge.
- 0° or 10° - Advanced ridge resorption.

## Background and Objective

Lingualized occlusion\* was first documented in dental literature in 1927 by one of the founding-fathers of articulation, Dr. Alfred Gysi, of Switzerland. It is defined as, "setting the upper posterior teeth in a turned-out position (cusps toward the cheeks), so that only the lingual cusps of the maxillary teeth contact the center of the occlusal table (the fossa) of the mandibular posterior teeth" (see Figure 1 below).

The focus of this posterior arrangement method is on elimination of the tooth contact points on the buccal cusps. Thus, the occlusal contacts are moved as far lingually as practical, while still maintaining the physiologic positioning of the prosthetic teeth. Preservation of the lingual contacts assures seating and minimizes tipping of the lower denture upon tooth contact and during function.

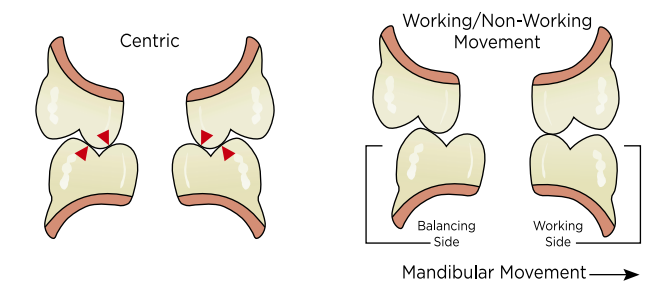


Figure 1. Lingualized Set-Up

Within practical limits, it is aesthetically optimal when denture teeth are arranged close to where the natural teeth were originally located, prior to ridge resorption. Radiographs and pre-edentulous photographs of the patient are important in determining this position. However, patients with resorbed ridges and restricted neutral zones (the channel where the teeth are located that should not be affected by tongue, lip and cheek forces which could unseat the denture) may determine the extent to which aesthetics will be sacrificed for functional improvements. In such cases, lingualized occlusion minimizes aesthetic compromises and optimizes functionality.

## Lingualized Set-up Techniques

For a lingualized occlusion, select a higher degree cusp angle on the upper posterior teeth than the degree of cusp angle of the lower posterior teeth.

We recommend that the maxillary posterior teeth be a 30° occlusal slope or greater and that the mandibular posterior teeth be a 22° slope or less. However, when proper lingualized articulation techniques are used, almost any combination of teeth will function properly.

Dentsply Sirona suggests the following process for lingualized articulation and arrangement of posterior teeth to achieve function, comfort, and aesthetics for a fully edentulous patient.

1. Set the upper arch first with ideal Curve of Spee, Curve of Wilson, and Lingual Curve except when a linear arrangement is desired.

NOTE: Set the anterior denture teeth in their physiologic position for aesthetic and phonetic reasons. Posterior teeth can be set over the resorbed ridge when adequate tongue space exists, or facial to the ridge when aesthetics require facial placement of the teeth (Figure 2).

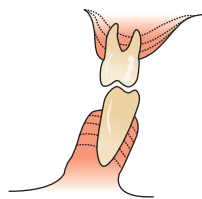


Figure 2. Posterior Resorption

2. If a lingualized arrangement is desired, when all maxillary teeth have been set insert an object the approximate thickness of a 2mm ruler between the buccal cusps of the posterior teeth and the table while the set-up wax is still soft (Figure 3). Apply pressure. This technique will elevate the maxillary buccal cusps to the right position for proper contact between the opposing stamp cusps. This also eliminates any contact between the maxillary buccal cusp and the opposing mandibular buccal cusp in the working movement.

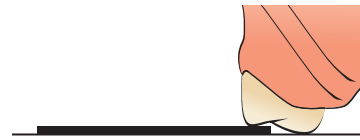


Figure 3.

3. Begin setting the mandibular arch with the first molars. The mandibular first molars are the “key to occlusion” (Figures 4, 5). Use the mesiolingual maxillary cusp as the stamp cusp. A stamp cusp is a working cusp, which occludes into a fossa in the opposing dentition. In lingualized occlusion the maxillary stamp cusps are preserved. No grinding should occur on these teeth. Use the rule of **BULL** for adjustments: if needed, occlusal grinding should eliminate contact on the **B**uccal cusps of the **U**pper teeth and remove premature contact from **L**ingual cusps of the **L**ower teeth. Set the remaining mandibular posterior teeth.

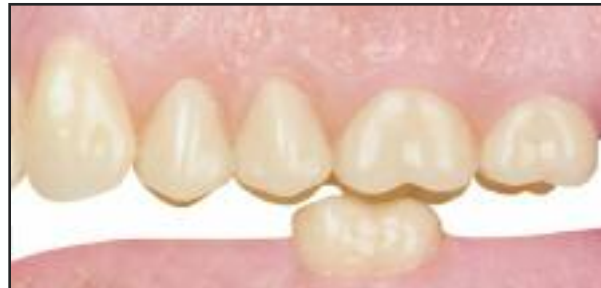

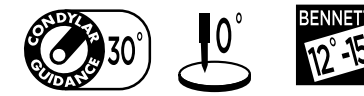
Figure 4. Mandibular first molar- Buccal View

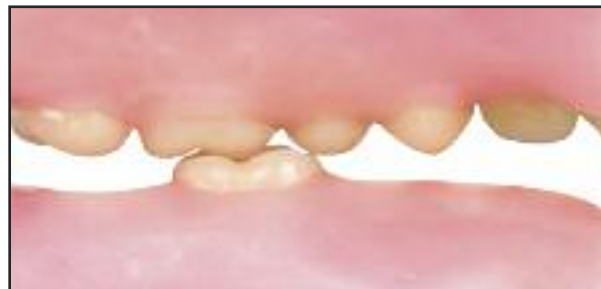

Figure 5. Mandibular first molar- Lingual View

4. **Grind-in option:** You also have the option to grind in occlusion. Prior to setting the mandibular teeth, open the articulator pin 1mm. Grind a saucer shape approximately 2mm wide to accommodate the stamp cusps. The saucer shape is developed by marking both centric and eccentric occlusion with articulating paper. Continue to develop the saucers until the pin contacts the incisal guide table.

## Arranging Portrait® IPN® Posteriors (33° Maxillary Posteriors with 22° Mandibular Posteriors)



1. Place the 33° maxillary premolars with their long axes at right angles to the occlusal plane (Figure 6). The lingual cusps should touch the plane and the buccal cusps should be raised approximately 1/2 mm above the plane (Figures 6 and 7). A straight edge may be used to align the lingual cusps as shown previously.
2. The first and second molars may be set with their long axes inclined slightly mesially (Figure 6).

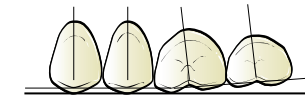


Figure 6.

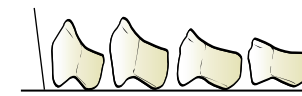
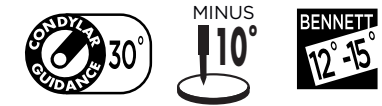
Figure 7.

3. The mesiolingual cusp of the first molar touches the plane, and the mesiobuccal cusp is approximately 1/2 mm above the plane. The distolingual cusp is slightly above the plane, and the distobuccal cusp is approximately 1 mm above (Figures 6 and 7).
4. The second molar is set to follow the same angle or plane of the first molar. The distolingual cusp is approximately 1-1/2 mm above the plane, and the distobuccal cusp is approximately 2 mm above the plane (Figures 6 and 7).
5. Follow the same procedure in placing the posterior teeth on the opposite side.
6. Occlude the central fossae area of the mandibular 22° teeth to the lingual cusps of the maxillary 33° teeth. A typical relationship of upper to lower is illustrated in Figure 8. The relationships of the completed arrangement are shown in Figures 9-17 on page 12.

## Arranging Portrait IPN 33° Maxillary Posteriors with Portrait IPN 0° Mandibular Posteriors



7. Occlude the central fossae area of the mandibular 0° teeth to the lingual cusps of the maxillary 33° teeth. A typical relationship of upper to lower is illustrated in Fig. 8. The relationships of the completed arrangement are shown in Figures 18-26 on page 13.

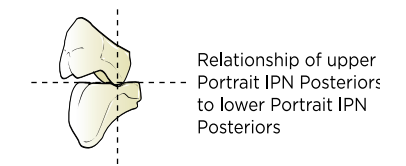


Figure 8.

Key Tip

If a “deeper” or “tighter” occlusion is desired, some slight grinding modification in the developmental groove areas of the 0° lower posteriors will permit a more intimate lingualized relationship with the lingual cusps of the upper 33° posteriors. The modification may be done with small, mounted points.

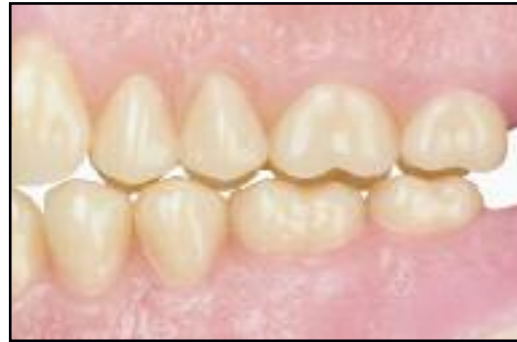More Sources

Lingualized Occlusion Video Reference # DP-0000130

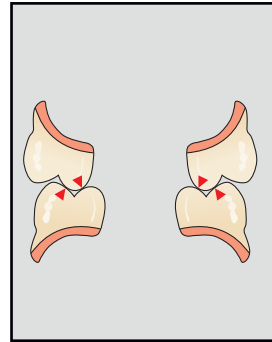
## Portrait® IPN® Teeth - 33° / 22° Example for Lingualized Occlusion

A simplified approach to tooth selection, ordering and set-up.

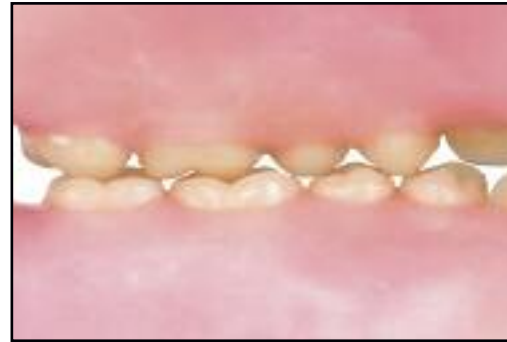### Tooth Arrangement In All Relations



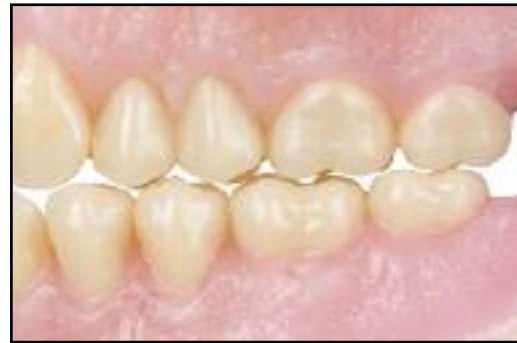**Figure 9.** Portrait IPN Lingualized balanced arrangement in centric occlusion, buccal view.



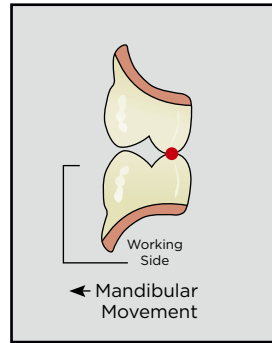
**Figure 10.** Cross section of centric occlusion.



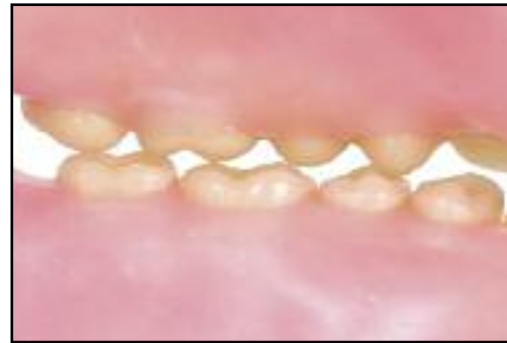**Figure 11.** Centric occlusion, lingual view.



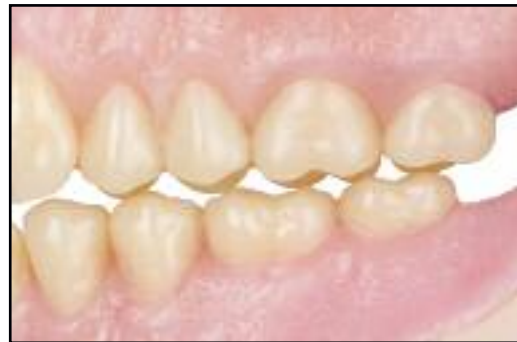**Figure 12.** Working occlusion, buccal view.



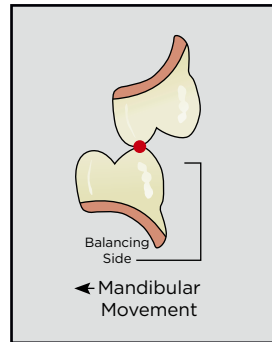
**Figure 13.** Cross section of working occlusion.



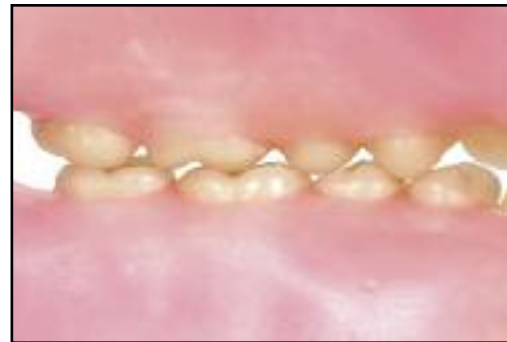**Figure 14.** Working occlusion, lingual view.



**Figure 15.** Balancing occlusion, buccal view.



**Figure 16.** Cross section of balancing occlusion.



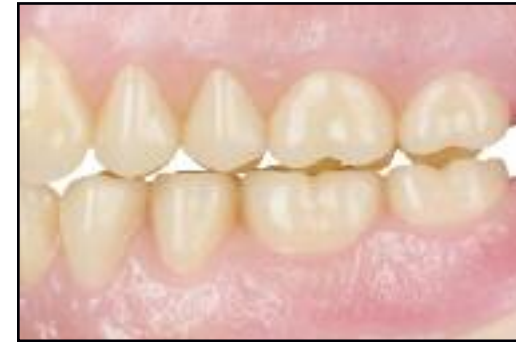**Figure 17.** Balancing occlusion, lingual view.

Note: Arrangements shown are average. Modifications may be made as needed for a given situation.

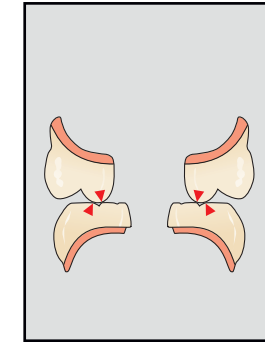
## Portrait® IPN® Teeth - 33° / 0° Example for Unlingualized Occlusion

An alternative for lingualized cases requiring flat mandibular occlusion.

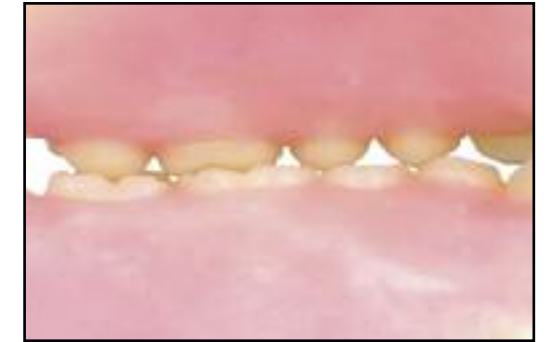### Tooth Arrangement In All Relations



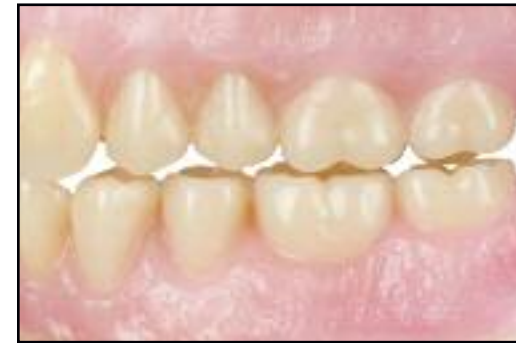**Figure 18.** Centric occlusion, buccal view.



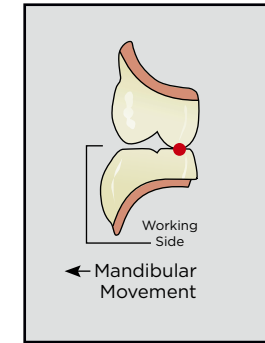
**Figure 19.** Cross section of centric occlusion.



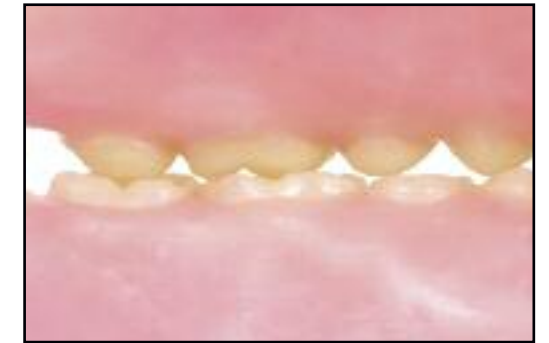**Figure 20.** Centric occlusion, lingual view.



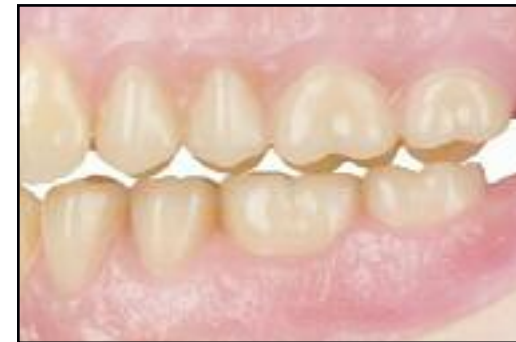**Figure 21.** Working occlusion, buccal view.



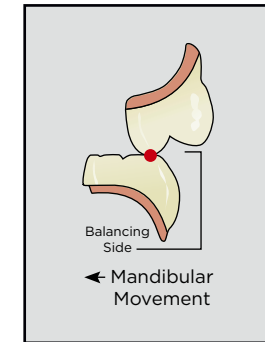
**Figure 22.** Cross section of working occlusion.



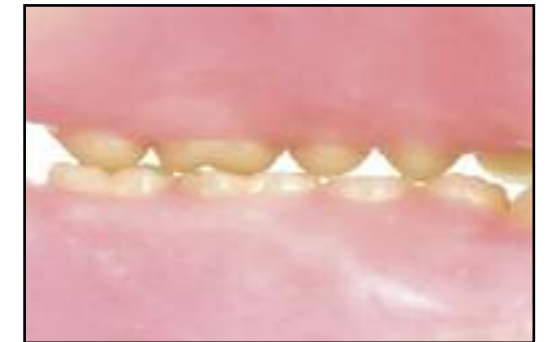**Figure 23.** Working occlusion, lingual view.



**Figure 24.** Balancing occlusion, buccal view.



**Figure 25.** Cross section of balancing occlusion.



**Figure 26.** Balancing occlusion, lingual view.

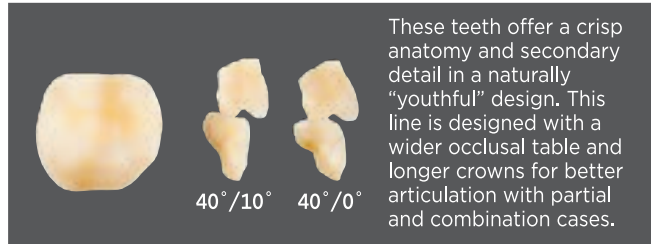


## Lingualized Occlusal Options from Dentsply Sirona

Dentsply Sirona provides a large selection of posterior tooth options to assure that technicians will have a variety of predictable ways to approach lingualized occlusion - with the cutting edge on top and the food table below.

Lingualized arrangements can be successfully accomplished for each of the mould combinations illustrated below.

### Portrait® IPN® 40° Posteriors (EuroLine®)

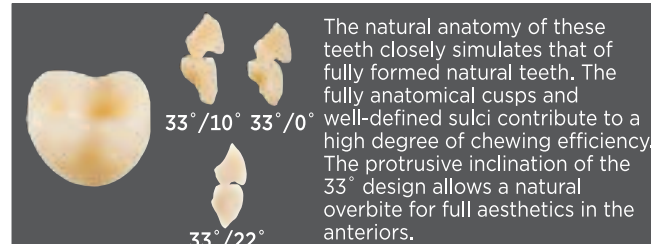


These teeth offer a crisp anatomy and secondary detail in a naturally "youthful" design. This line is designed with a wider occlusal table and longer crowns for better articulation with partial and combination cases.

40°/10° 40°/0°

Can be set in the following: 40°/10° and 40°/Portrait 0°

### IPN® 33° Posteriors

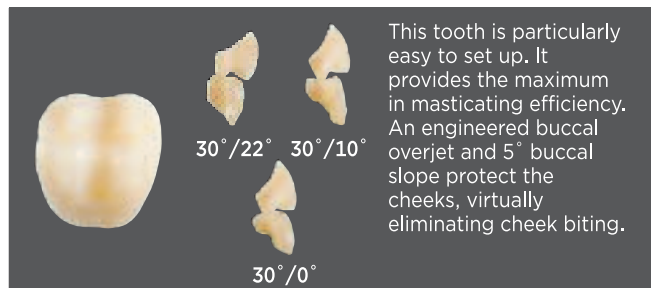


The natural anatomy of these teeth closely simulates that of fully formed natural teeth. The fully anatomical cusps and well-defined sulci contribute to a high degree of chewing efficiency. The protrusive inclination of the 33° design allows a natural overbite for full aesthetics in the anteriors.

33°/10° 33°/0°  
33°/22°

Can be set in the following: 33°/22°, 33°/10° and 33°/Portrait 0°

### IPN® 30° Posteriors (Pilkington-Turner®)

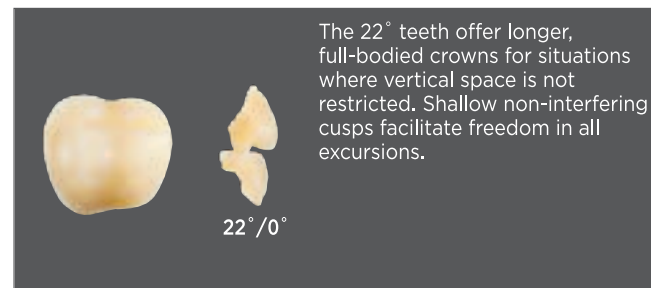


This tooth is particularly easy to set up. It provides the maximum in masticating efficiency. An engineered buccal overjet and 5° buccal slope protect the cheeks, virtually eliminating cheek biting.

30°/22° 30°/10°  
30°/0°

Can be set in the following: 33°/22°, 33°/10° and 33°/Portrait 0°

### Portrait® IPN® 22° Posteriors (BioStabil®)

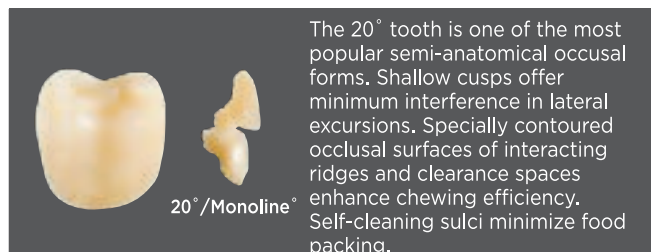


The 22° teeth offer longer, full-bodied crowns for situations where vertical space is not restricted. Shallow non-interfering cusps facilitate freedom in all excursions.

22°/0°

Can be set in the following: 22°/Portrait 0°

### IPN® 20° Posteriors

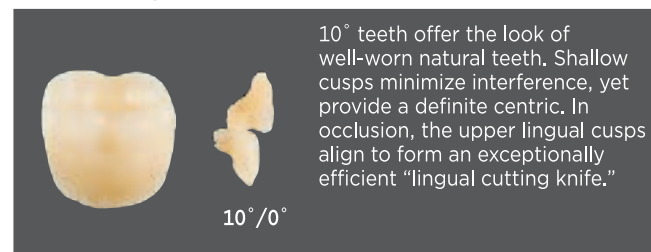


The 20° tooth is one of the most popular semi-anatomical occlusal forms. Shallow cusps offer minimum interference in lateral excursions. Specially contoured occlusal surfaces of interacting ridges and clearance spaces enhance chewing efficiency. Self-cleaning sulci minimize food packing.

20°/Monoline®

Can be set in the following: 20°/0°

### IPN® 10°/IPN® Posteriors (Anatoline®)

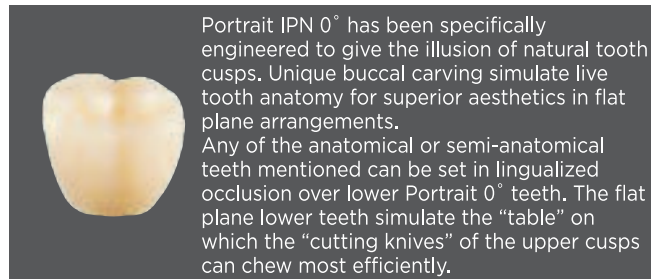


10° teeth offer the look of well-worn natural teeth. Shallow cusps minimize interference, yet provide a definite centric. In occlusion, the upper lingual cusps align to form an exceptionally efficient "lingual cutting knife."

10°/0°

Can be set in the following: 10°/Portrait 0°

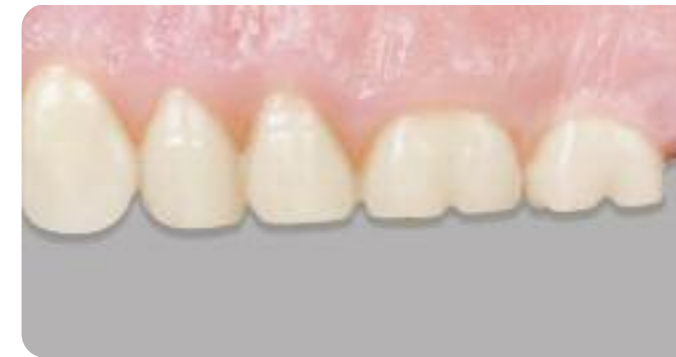### Portrait® IPN® 0° Posteriors (Monoline®)



Portrait IPN 0° has been specifically engineered to give the illusion of natural tooth cusps. Unique buccal carving simulate live tooth anatomy for superior aesthetics in flat plane arrangements. Any of the anatomical or semi-anatomical teeth mentioned can be set in lingualized occlusion over lower Portrait 0° teeth. The flat plane lower teeth simulate the "table" on which the "cutting knives" of the upper cusps can chew most efficiently.

For more detailed tooth arrangement options, contact your Dentsply Sirona Representative or call Customer Service at 1-800-786-0085 to receive a copy of "Individualized Anterior Arrangements of Dentsply Sirona Teeth" Reference #3900.

[More Sources](#)



## Posteriors 0° (Monoline® 0°)

### Description:

Non-anatomical, with the illusion of well-worn anatomical teeth. Zero degree cusps are non-interfering and provide complete freedom in lateral excursions.

### Indications For Use:

Ideal for use with full dentures. Open occlusal angles permit a lingualized set-up with semi or fully anatomical upper posteriors.

### Ridge Type:

Advanced ridge resorption.

### Recommended Technique:

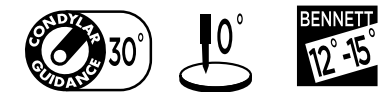
Bilateral Balanced, Linear Occlusion, and Lingualized Occlusion.

Dentsply Sirona® Portrait® IPN® 0° Posterior teeth are the first flat plane posterior teeth to be rated superior in overall aesthetic appearance. They are suitable for complete dentures where a zero degree tooth is indicated or preferred. A wider bucco-lingual table promotes efficient function and ease of set-up. Zero degree cusp areas are non-interfering and provide complete freedom in lateral excursions. When viewed in the mouth, the mesiofacial appearance of 0° teeth resemble well-worn natural teeth. A modified rational occlusal design gives the illusion of anatomical teeth.

Portrait IPN 0° teeth may be arranged for continuous bilateral balanced occlusion with the proper compensating curve or in flat linear occlusion. Open occlusal angles are ideal for lingualized set-up with semi or fully anatomical upper posteriors, especially "even-dimensioned" 10° and 33° posteriors. To aid in arrangement, the maxillary teeth may be positioned with the lingual surfaces set to a straight edge. This positioning automatically provides a proper degree of buccal contour for good aesthetic appearance and function.

All Dentsply Sirona 0° Posterior teeth follow the same suggested arrangement and articulation guidelines as Portrait IPN 0° Posterior teeth.

### Arranging Dentsply Sirona Flat Plane IPN Posteriors in linear occlusion



1. Place the maxillary premolars and molars with their long axes at right angles to the occlusal plane (Figure 1). The buccal and lingual cusp areas should touch the plane (Figures 1 and 2).

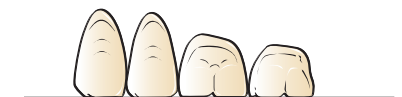

Figure 1.

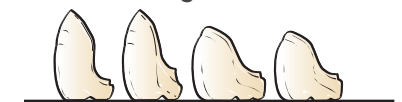

Figure 2.

2. A straight edge may be used to align the lingual cusps of all four posteriors to a straight line (Figures 3 and 4). When this is done, a proper buccal contour results.

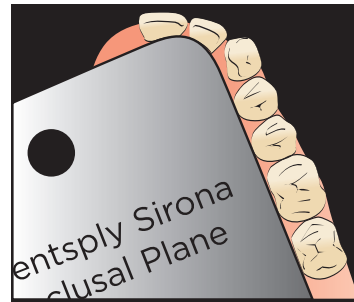


Figure 3.

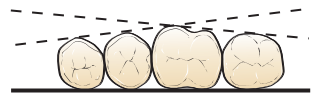

Figure 4.

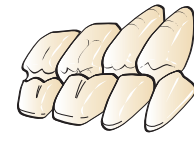

Figure 5.

The arrangement illustrated here was done with a 30° condylar inclination and a 0° incisal inclination. Other guidance factors may be used as individual conditions indicate. In this type occlusion with 0° Posteriors, there will normally be no contact in balancing positions.

Note: The maxillary and mandibular teeth do not interdigitate. They may be set end-to-end as shown in Figure 6. It is possible to position premolars to oppose molars because there is no interdigitation of the cusps.

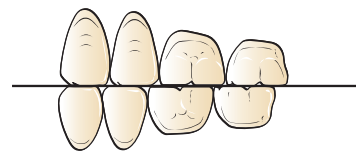


Figure 6.

3. Follow the same procedure in placing the posteriors on the opposite side.
4. Then, occlude the mandibular teeth to the maxillary teeth (Figures 7-15). There should be approximately 1.5 mm of buccal overjet by the maxillary teeth as shown in Figure 5. This buccal overjet is essential to prevent "cheek biting".

### 0° Posteriors: The Completed Tooth Arrangement In All Relations In Linear Occlusion

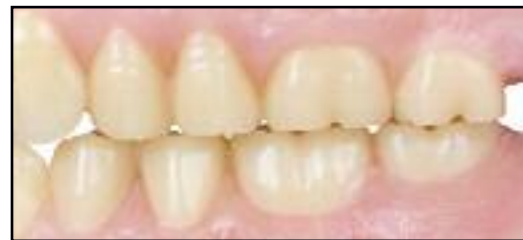

Figure 7. Portrait IPN 0° flat linear type tooth arrangement in centric occlusion, buccal view.

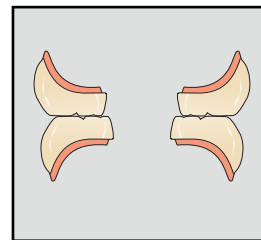


Figure 8. Cross section of centric occlusion.

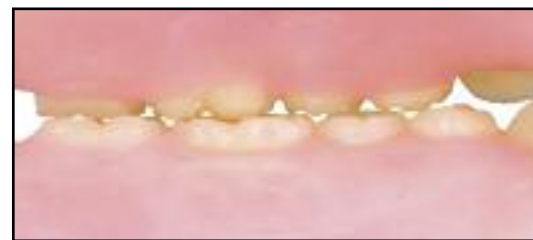

Figure 9. Centric occlusion, lingual view.

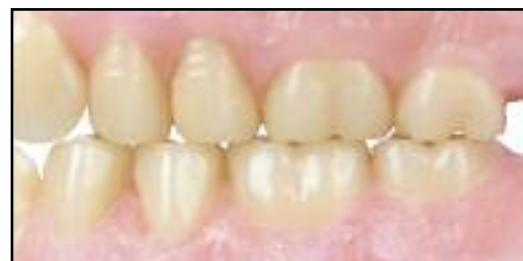

Figure 10. Working occlusion, buccal view.

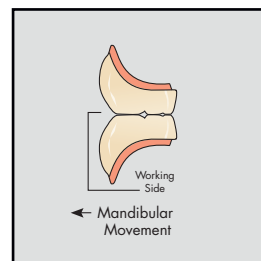


Figure 11. Cross section of working occlusion.

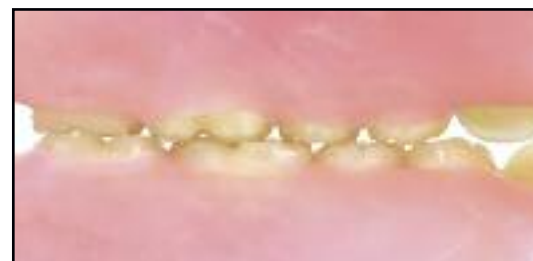

Figure 12. Working occlusion, lingual view.

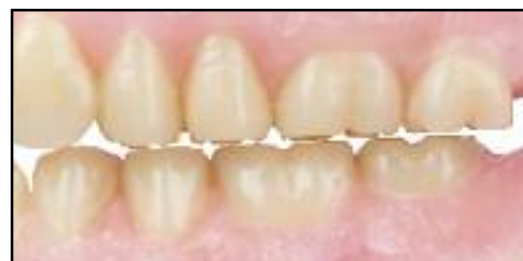

Figure 13. Balancing position, buccal view.

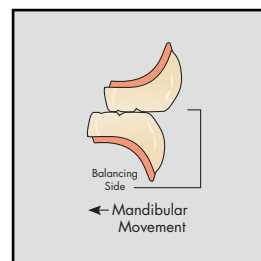


Figure 14. Cross section of balancing occlusion.

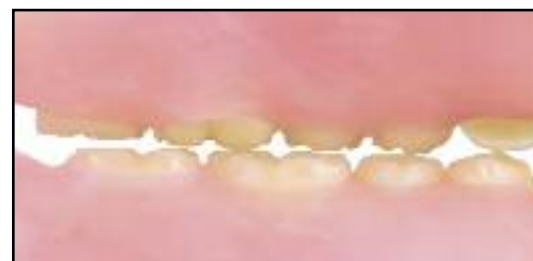

Figure 15. Balancing position, lingual view.

### Arranging Flat Plane Posteriors in bilateral balanced occlusion

1. Place the maxillary premolars with their long axes at right angles to the occlusal plane (Figure 16). The lingual cusp areas should touch the plane, and the buccal cusp areas of the premolars should be raised approximately 1/2 mm above the plane (Figures 16 and 17).



Figure 16.

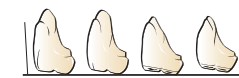

Figure 17.

A straight edge may be used to align the lingual tooth surfaces as shown previously (Figures 3 and 4).

2. The first and second molars may be set with their long axes inclined very slightly toward the mesial (Figure 16).
3. Position the first molar with the mesiolingual cusp area touching the plane, and the mesiobuccal cusp area approximately 1/2 mm above the plane. The distobuccal cusp area should be approximately 1 mm above the plane (Figures 16 and 17).

4. The second molar is set to follow the same angle or plane of the first molar. The mesiolingual cusp should be about 1 mm above the plane, and the mesiobuccal and distolingual cusp areas approximately 2 mm off the plane.
5. Follow the same procedure in placing the posterior teeth on the opposite side.
6. Then, occlude the mandibular teeth to the maxillary teeth (Figures 18-26). A 30° condylar inclination and 0° incisal inclination were used in this arrangement. Other guidance factors may be used as individual conditions indicate.

When using flat plane posteriors, it is advisable to modify the canines so that the incisal edges tend toward bluntness rather than a sharp point. A somewhat blunted canine enhances the appearance of the contact area and embrasure between the canine and the first premolar.

To ensure the best occlusal efficiency, there should be close contact of the occlusal surfaces when viewed from the lingual, as well as the buccal.

### 0° Posteriors: The Completed Tooth Arrangement In All Relations In Bilateral Balanced Occlusion

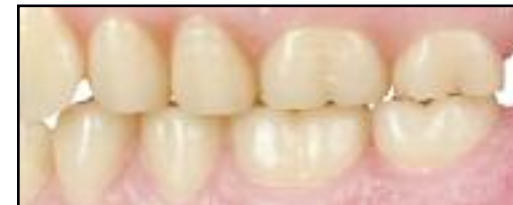

Figure 18. Portrait IPN 0° balancing arrangement, in centric occlusion, buccal view.

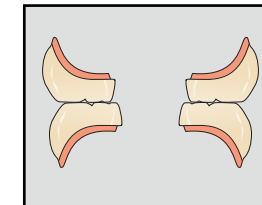


Figure 19. Cross section of centric occlusion.

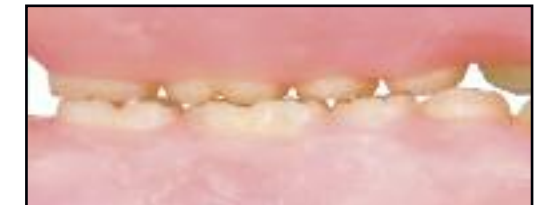

Figure 20. Centric occlusion, lingual view.

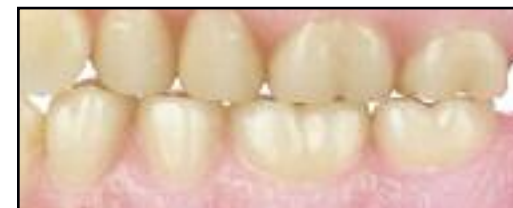

Figure 21. Working occlusion, buccal view.

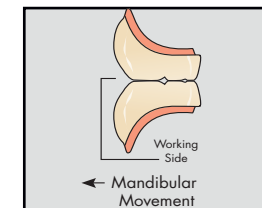


Figure 22. Cross section of working occlusion.

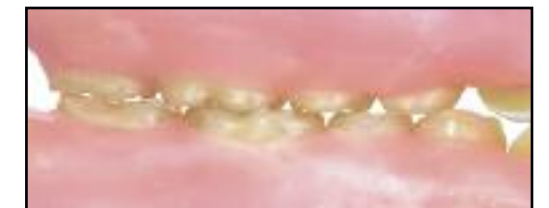

Figure 23. Working occlusion, lingual view.

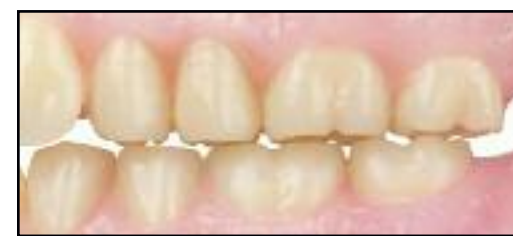

Figure 24. Balancing position, buccal view.

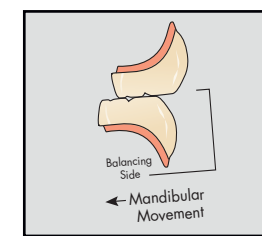


Figure 25. Cross section of balancing occlusion.

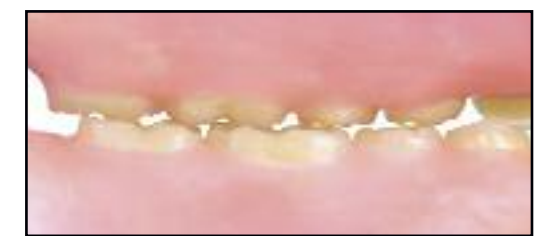
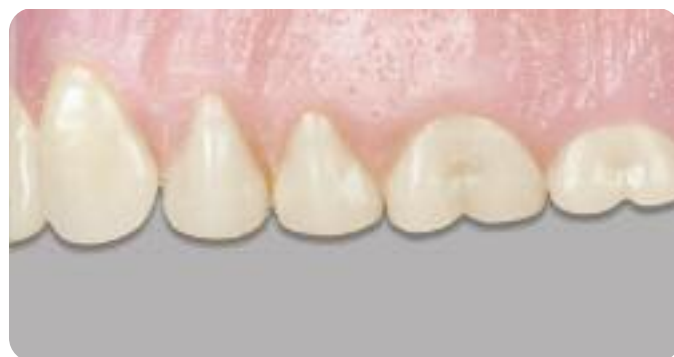
Figure 26. Balancing position, lingual view.

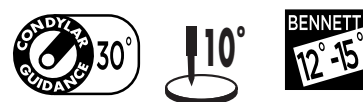

Dentsply Sirona IPN 10° Posterior teeth are a beautifully carved tooth form with moderately inclined cuspal slopes. Their natural anatomic form makes them aesthetically and functionally well suited for use in complete and partial dentures.

10° Posteriors resemble well-worn natural teeth, but with well-defined sluiceways and ridges to promote good chewing efficiency without packing - important for patient comfort. Cusps are shallow and non-interfering to facilitate freedom in excursions. A slight protrusive lift allows anterior overbite for improved aesthetics.

These teeth may be arranged in a linear type occlusion or with a compensating curve for continuous bilateral balanced occlusion. For convenience in tooth arrangement in both configurations, when viewed from the occlusal aspect, the maxillary teeth may be set with the lingual surfaces set to a straight edge. This automatically provides a proper degree of buccal curvature.

Arranging Dentsply Sirona 10° posteriors in linear occlusion



1. Place the maxillary premolars and molars with their long axes at right angles to the occlusal plane (Figure 1). The buccal and lingual cusps should touch the plane (Figures 1 and 2).

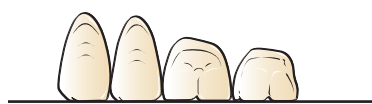


Figure 1.

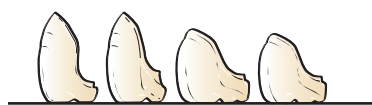

Figure 2.

2. A straight edge may be used to align the lingual cusps of all four posteriors to a straight line (Figure 3).



Figure 3.

# Posteriors 10°

(Anatoline®/Functional®)

## Description:

Semi-anatomical, with the look of well-worn natural teeth. Shallow cusps minimize interference, yet provide a definite centric.

## Indications For Use:

Ideal for use with full dentures. In occlusion the upper lingual cusps align to form an efficient lingual "cutting knife".

## Ridge Type:

Semi to fully resorbed ridge.

## Recommended Technique:

Bilateral Balanced, Lingualized and Linear Occlusion.

When this is done, a proper degree of buccal curvature results (Figure 4).

This also aligns the lingual cusps to, in effect, form a lingual knife for exceptional cutting efficiency.

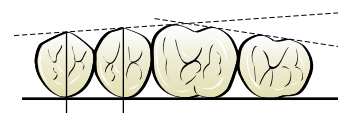


Figure 4.

3. Follow the same procedure in placing the posteriors on the opposite side.
4. Then, occlude the mandibular teeth to the maxillary teeth as shown in Figures 5-10. This arrangement was done with a 30° condylar inclination, and a 10° incisal inclination. Other guidance factors may be used as conditions indicate.

## 10° Posteriors: The Completed Tooth Arrangement In All Relations

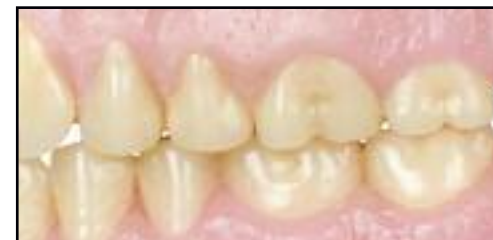

Figure 5. 10° linear arrangement in centric occlusion, buccal view.

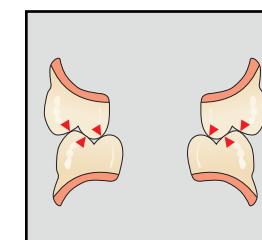


Figure 6. Cross section of centric occlusion.

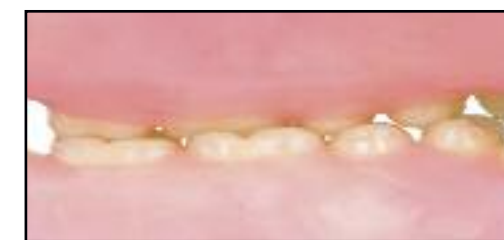

Figure 7. The linear arrangement in centric occlusion, lingual view.

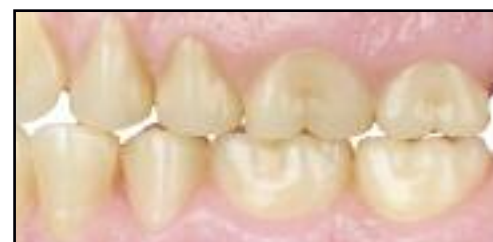

Figure 8. The linear arrangement in working occlusion, buccal view.

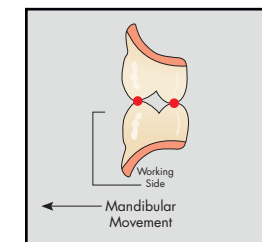


Figure 9. Cross section of working occlusion.

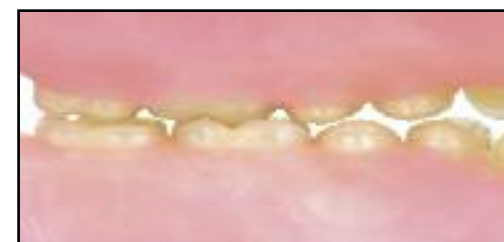

Figure 10. The linear arrangement in working occlusion, lingual view.

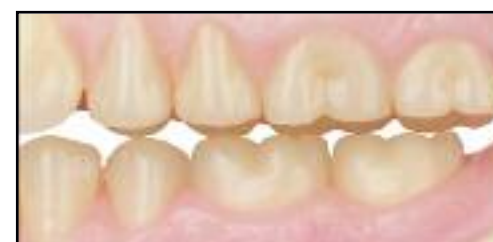

Figure 11. The linear arrangement in balancing position, buccal view.

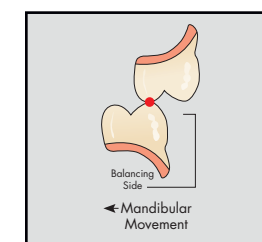
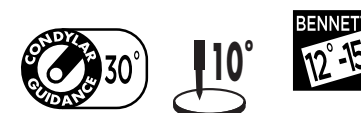


Figure 12. Cross section of balancing occlusion.

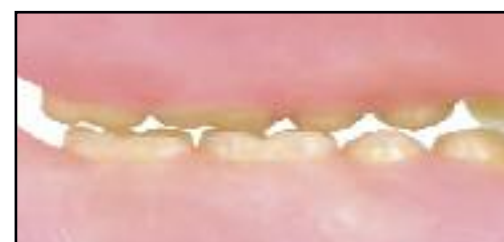

Figure 13. The linear arrangement in balancing position, lingual view. Balancing contacts may be minimal.

## Arranging 10° posteriors in bilateral balanced occlusion



1. Place the maxillary premolars with their long axes at right angles to the occlusal plane (Figure 14). The lingual cusps should touch the plane and the buccal cusps should be raised approximately 1/2 mm above the plane (Figures 14 and 15). A straight edge may be used to align the lingual cusps as shown previously (Figures 3 and 4).

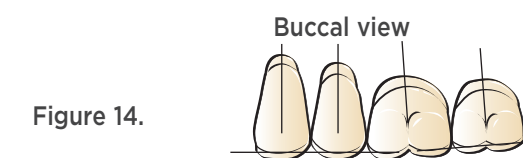


Figure 14.

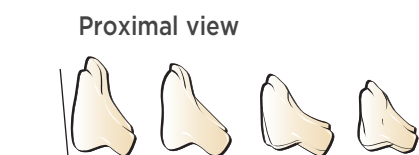

Figure 15.

- The first and second molars may be set with their long axes inclined slightly mesially (Figure 14).
- The mesiolingual cusp of the first molar touches the plane, and the mesiobuccal cusp is approximately 1/2 mm above the plane. The distolingual cusp is slightly above the plane, and the distobuccal cusp is approximately 1 mm above the plane (Figures 14 and 15).
- The second molar is set to follow the same angle or plane of the first molar. The distolingual cusp is approximately 1-1/2 mm above the plane, and the distobuccal cusp is approximately 2 mm above the plane (Figures 14 and 15).
- Follow the same procedure in placing the posterior teeth on the opposite side.
- Then, occlude mandibular teeth to the maxillary teeth (Figures 16-24). A 30° condylar inclination and a 10° incisal inclination are recommended. However, other guidance factors may be used as individual conditions indicate.

### 10° Posteriors: The Completed Tooth Arrangement In All Relations

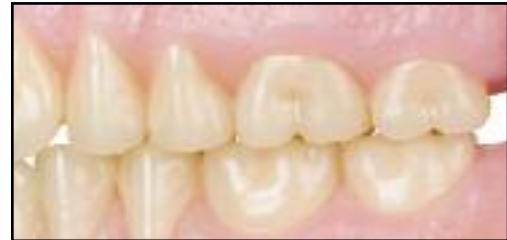

Figure 16. The balancing arrangement in centric occlusion, buccal view.

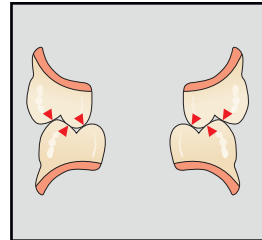


Figure 17. Cross section of centric occlusion.

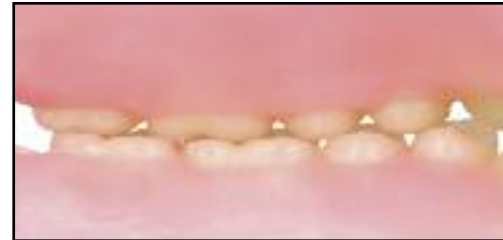

Figure 18. The balancing arrangement in centric occlusion, lingual view.

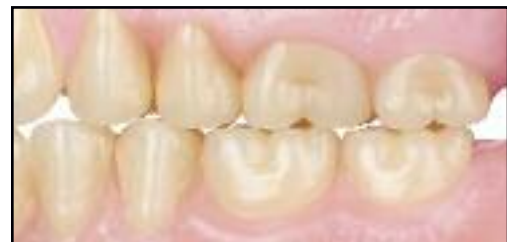

Figure 19. In working occlusion, buccal view.

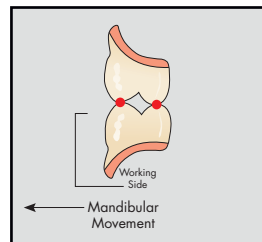


Figure 20. Cross section of working occlusion.

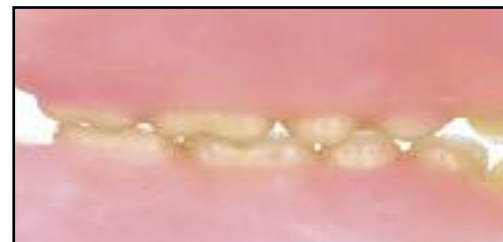

Figure 21. In working occlusion, lingual view.

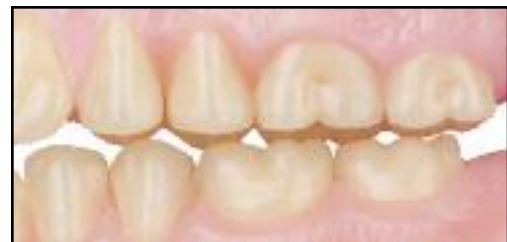

Figure 22. In balancing position, buccal view.

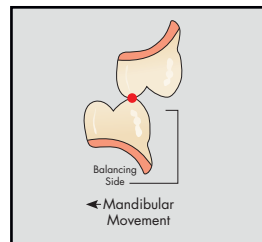


Figure 23. Cross section of balancing occlusion.

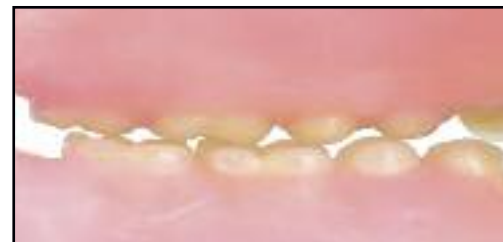
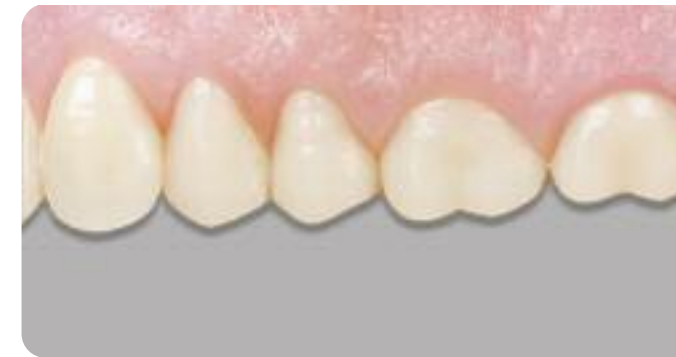
Figure 24. In balancing position, lingual view.

Note: Arrangements shown are average. Modifications may be made as needed for a given situation.



## Posteriors 20°

### Description:

Semi-anatomical, shallow 20° cusps offer minimal interference and interacting ridges with clearance spaces to enhance chewing efficiency.

### Indications For Use:

Ideal for use with full dentures, when ease of set-up and uninterrupted function is desired.

### Ridge Type:

Semi-resorbed ridge.

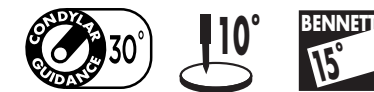
### Recommended Technique:

Bilateral Balanced and/or Lingualized Occlusion.

Dentsply Sirona 20° Posteriors are designed to overcome certain problems of the edentulous patient by utilizing shallow cusp angles as an aid in reducing lateral thrust forces. Because the occlusal surfaces have interacting ridges and intercommunicating clearance spaces, masticating efficiency is greatly enhanced. Dentsply Sirona 20° Posteriors will be found desirable for use whenever a semi-anatomical cuspal design is preferred or indicated.

- DESIGNED to function in accordance with anatomical requirements of mandibular movements.
- ENGINEERED for increased masticating efficiency with shallow cusp inclinations, interacting ridges and intercommunicating clearance ways.
- A CORRECT AXIS for each tooth to direct masticating forces and to assist in stability and retention of the denture.
- SELF-CLEANSING SULCI to help prevent food packing on chewing surfaces and to maintain a high degree of masticating efficiency.
- READILY ADAPTABLE to both steep and shallow condyle paths without destructive change in the occlusal surface.

### Arranging Dentsply Sirona 20° maxillary posteriors



Theoretical positions of the upper posteriors are shown in the following diagrams:

- Place the maxillary first premolar with its long axis at right angles to the occlusal plane. The buccal and lingual cusps are placed on the plane.
- Place the maxillary second premolar in a similar manner.

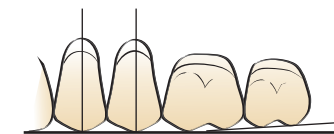


Figure 1. Buccal view

- The mesiobuccal and mesiolingual cusps of the upper first molar touch the occlusal plane. The distobuccal cusp is raised about 1/2 mm and the distolingual cusp will be raised accordingly (see Figure 2 next page).

- All the cusps of the second molar are raised from the lower occlusal plane following the same angle or plane of the first molar. The mesiobuccal cusp should be about 1 mm from the occlusal plane (see Figure 2 below).

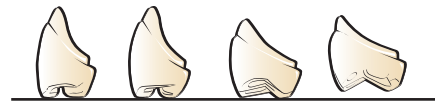

Figure 2. Interproximal view

- A straight edge may be used to align the labial ridge of the canine, the buccal ridges of the first and second premolars, and the mesiobuccal ridge of the first molar. The buccal ridges of the molars are similarly aligned, but angled slightly inward (see Figure 3).
- Follow the same procedure in placing the posteriors on the opposite side.

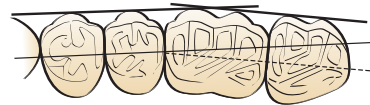


Figure 3. Use of straight edge, occlusal view.

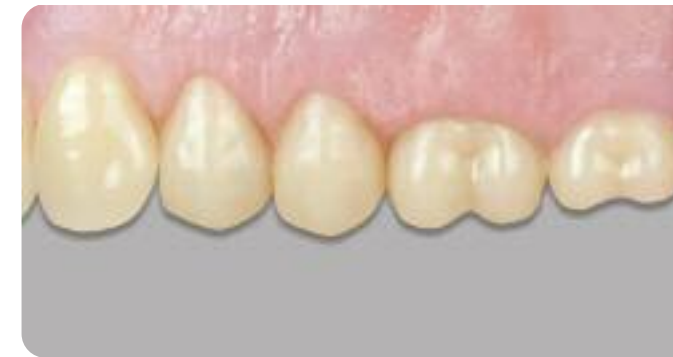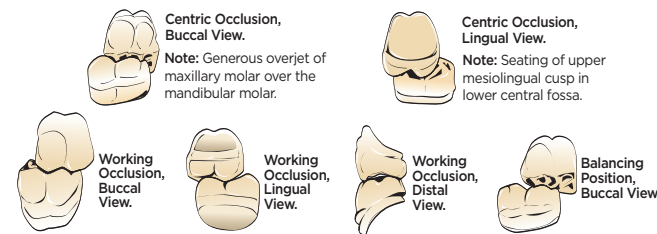
## Articulation of mandibular first molar

Bilateral balanced occlusion contributes greatly to the comfort and efficiency of complete dentures. Without balanced occlusion there may be greater resorption, less mastication efficiency, and a recurrence of sore spots. This can be accomplished with a minimum of effort if each tooth is brought into function.

If careful attention is paid to the positioning of the mandibular first molar, articulation of the remaining posteriors will be greatly facilitated.

## Relation of the maxillary and mandibular first molar

The first molars are the keystone to posterior occlusion. Illustrated here are ideal relationships.



# Posteriors 22° (BioStabil)

## Description:

Semi-anatomical, long crown forms with moderately inclined cuspal slopes.

## Indications For Use:

Ideal for use with partial dentures, in combination cases and implant overdentures; also for use in full dentures.

## Ridge Type:

Moderately resorbed ridge.

## Recommended Technique:

Bilateral Balanced and/or Lingualized Occlusion.

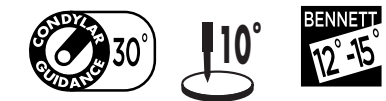Dentsply Sirona 22° Posterior teeth mimic natural dentition with moderately inclined cuspal slopes. Their natural anatomic form makes them aesthetically and functionally well suited for use in complete dentures, as well as for removable partial dentures.

The 22° Posteriors resemble well-worn natural teeth, but with well defined sluiceways and ridges to promote good chewing efficiency without packing food - important for patient comfort. Cusps are shallow and non-interfering to facilitate freedom in excursions, yet provide a definite point of centric contact. A slight protrusive lift allows anterior overbite for improved aesthetics.

These teeth may be arranged with a compensating curve for continuous bilateral balanced occlusion. For convenience in tooth arrangement, when viewed from the occlusal aspect, the maxillary teeth may be set with the lingual surfaces set to a straight edge. This automatically provides a proper degree of buccal curvature.

## Arranging Dentsply Sirona 22° Posteriors in bilateral balanced occlusion

- Place the maxillary premolars with their long axes



at right angles to the occlusal plane (Figure 1). The buccal cusps should touch the plane and the lingual cusp of the maxillary 1st premolar should be raised approximately 1/2 mm to 1 mm above the plane (Figures 1 and 2).

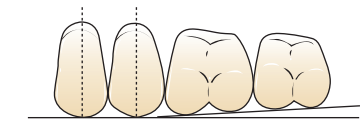


Figure 1. Buccal view

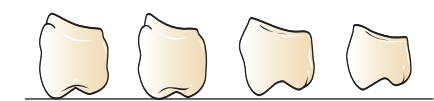

Figure 2. Proximal view

## 20° Posteriors - The Completed Tooth Arrangement In all Relations

The remaining teeth are inter-digitated in a similar manner. Check the centric and lateral relationships of each tooth as it is positioned - as well as the completed tooth arrangement in all relations.

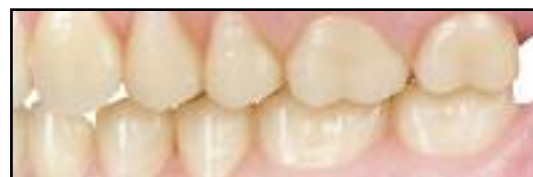

Figure 4. In centric occlusion, buccal view.

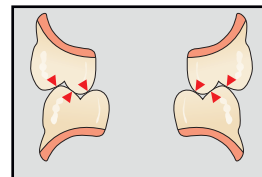


Figure 5. Cross section of centric occlusion.

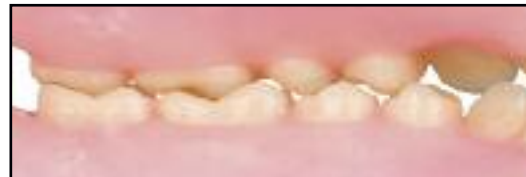

Figure 6. In centric occlusion, lingual view.

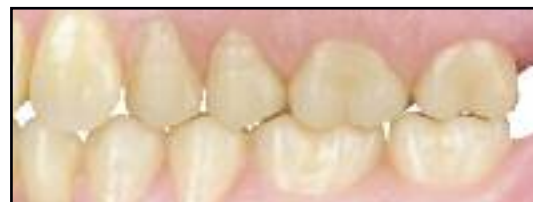

Figure 7. In working occlusion, buccal view.

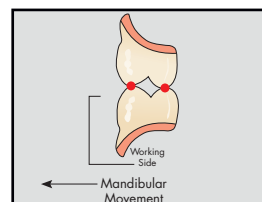


Figure 8. Cross section of working occlusion.

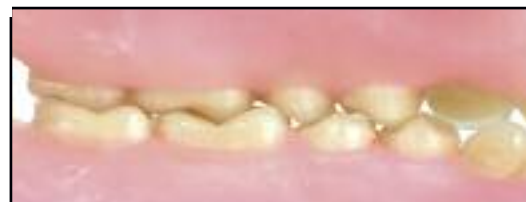

Figure 9. In working occlusion, lingual view.

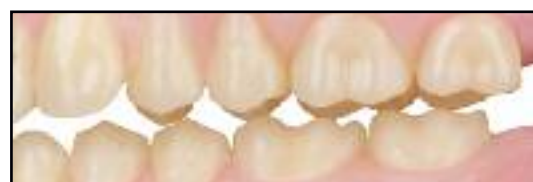

Figure 10. In balancing relation, buccal view.

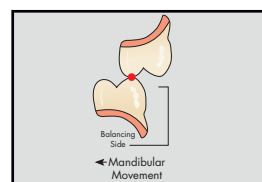


Figure 11. Cross section of balancing occlusion.

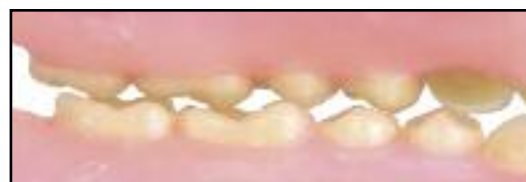

Figure 12. In balancing relation, lingual view.

Note: Arrangements shown are average. Modifications may be made as needed for a given situation.

A straight edge may be used to align the lingual cusps of all four posteriors to a straight line. When this is done, a proper degree of buccal curvature results (Figure 3).

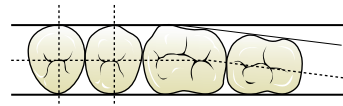



Figure 3.

2. The first and second molars may be set with their long axes inclined slightly mesially.
3. The mesiobuccal cusp of the first molar is approximately 1/2 to 3/4 mm above the plane. The mesiolingual cusp of the first molar is approximately 3/4 to 1 mm above the plane (Figures 1 and 2).

4. The second molar is set to follow the same angle or plane of the first molar. The distolingual cusp and the distobuccal cusp are approximately 1-1/2 mm above the plane (Figures 1 and 2).
5. Follow the same procedure in placing the posterior teeth on the opposite side.
6. Then, occlude mandibular teeth to the maxillary teeth (Figures 4-9).

 For the lingualized occlusion technique using 33° posteriors over 22° posteriors, and 33° over 0°, see pages 9-14.

### 22° Posteriors: The Completed Tooth Arrangement In All Relations

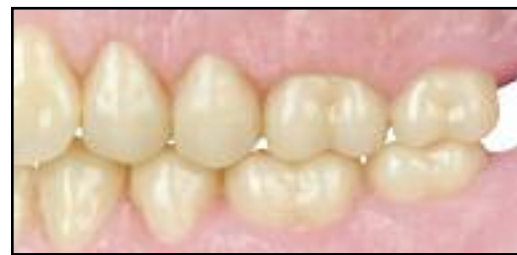

Figure 4. Centric occlusion, buccal view.

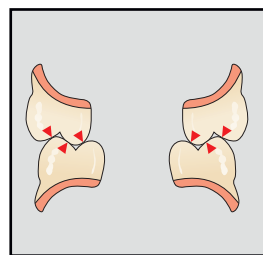


Figure 5. Cross section of centric occlusion.

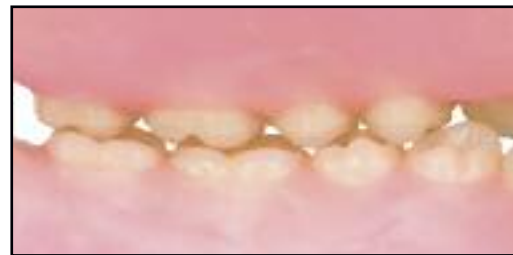

Figure 6. Centric occlusion, lingual view.

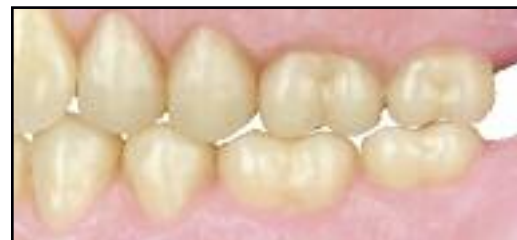

Figure 7. Working occlusion, buccal view.

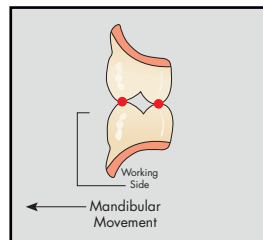


Figure 8. Cross section of working occlusion.

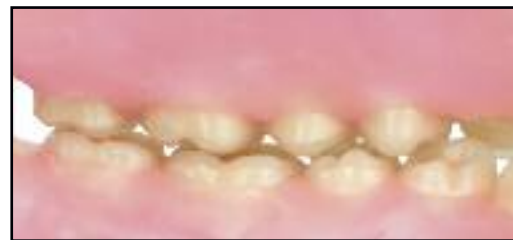

Figure 9. Working occlusion, lingual view.

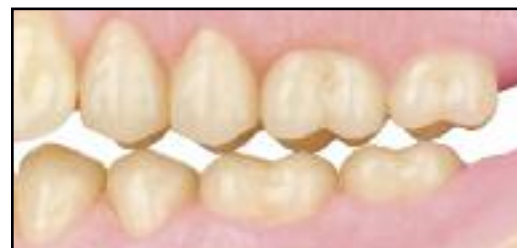

Figure 10. Balancing position, buccal view.

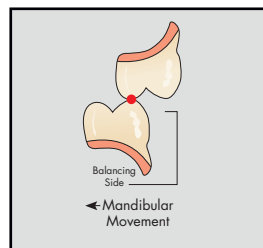


Figure 11. Cross section of balancing occlusion.

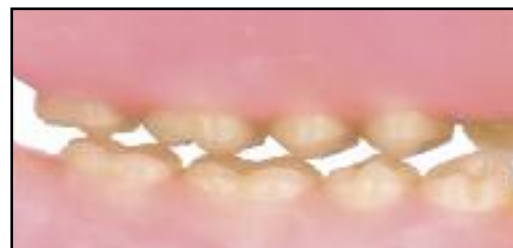
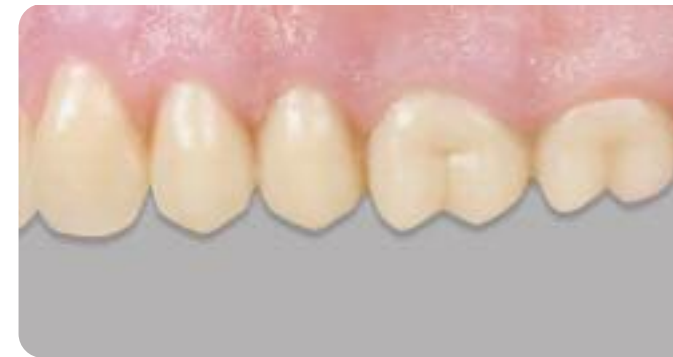
Figure 12. Balancing position, lingual view.

Note: Arrangements shown are average. Modifications may be made as needed for a given situation.



## Posteriors 30° (Pilkington-Turner®)

### Description:

Fully anatomical, long crown forms and long buccal-short bite moulds available.

### Indications For Use:

Ideal for use with partial dentures, in combination cases and implant overdentures; also for use in full dentures.

### Ridge Type:

Healthy ridge with minor resorption.

### Recommended Technique:

Bilateral Balanced and/or Lingualized Occlusion.

Dentsply Sirona 30° Posteriors are designed to meet the anatomical requirements of the mandibular movements of the majority of patients. They are particularly suitable for partial and complete dentures which oppose natural teeth, and for complete dentures in which a cuspal form is preferred.

When the teeth are properly occluded, they will have bilateral balance without cuspal interference. The 5° buccal slope and the engineered buccal overjet protects the cheeks and helps to virtually eliminate cheek biting.

The natural form and function of the 5° buccal slope



The 30° Posteriors are designed with a 5° buccal slope of the maxillary premolars, which follows nature's plan and greatly improves the aesthetics of finished dentures. Studies of thousands of natural teeth reveal the importance of this 5° slope in aesthetics. Figure 1 below shows two representative natural maxillary pre-molars compared with the 30° premolars. Note how closely the 5° buccal slope follows nature's plan.

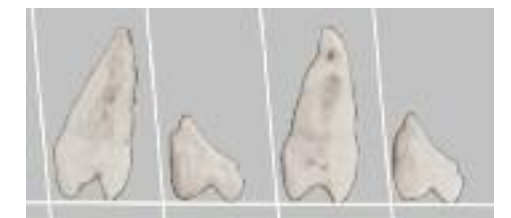


Figure 1.

A greater degree of comfort and efficiency for the patient

An important feature of the 30° Posteriors is the adequate food table and narrow occlusal contact. Greater stability of the denture is provided by the shallow transverse or lateral angle of the teeth. Mastication is made easier and more efficient, assuring a new and greater degree of comfort to the patient.



**Figure 2.** Showing the ample food table provided in the occlusal design of the premolars and molars.

### Natural conformation and size are ideal for removable partial dentures

30° Posteriors conform closely in size and shape to natural teeth. Buccolingually, their width closely approximates that of natural teeth. Mesiodistally, they are provided in sizes harmonious with natural teeth which they may replace.

### Procedures to be observed in arranging 30° Posteriors

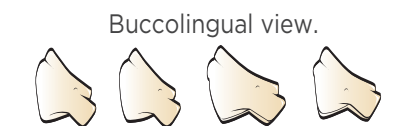Bilateral balanced occlusion is an important element in securing maximum comfort and efficiency in complete dentures. Without balance, there may be more resorption of the ridges, lessening of masticating efficiency and greater recurrence of tender, sore tissue.

Balanced occlusion can be accomplished by emphasis on two factors:

- A. The correct positioning of the upper teeth.
- B. The correct arrangement and individual positioning of each lower tooth in a functioning relationship to the uppers.

A major advantage in the arrangement and articulation of the 30° Posteriors lies in their adaptability to most techniques and the ease with which balanced occlusion may be obtained.

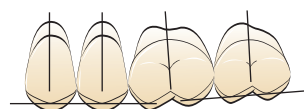
Following are suggestions for the arrangement and articulation of the 30° Posteriors. These suggested procedures follow generally observed principles.



Buccolingual view.

**Figure 3.** This buccolingual sketch of each posterior tooth shows the individual relationship to the occlusal plane. Note that the lingual cusp of the first and second premolars and the mesiolingual cusp of the first molar touch the occlusal plane. The buccal cusps are raised approximately 1/2 mm. The molars also follow this proportionate relation. The arrangement of posterior teeth in this manner forms the compensating curve (Curve of Wilson), the counterpart of the Curve of Spee in a natural dentition.

Buccal view.

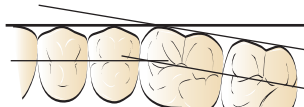


**Figure 4.** The long axis of the premolars should be at right angles to the occlusal plane, while the molars incline very slightly toward the mesial.

The mesiobuccal cusp of the first molar is raised 1/2 mm to position it out of contact with the occlusal plane. The mesiolingual cusp touches the plane. The distobuccal cusp should be raised approximately 1 mm.

The mesiobuccal cusp of the second molar should be raised about 1 mm, while the distobuccal cusp should be raised approximately 1-1/2 mm.

Occlusal view.



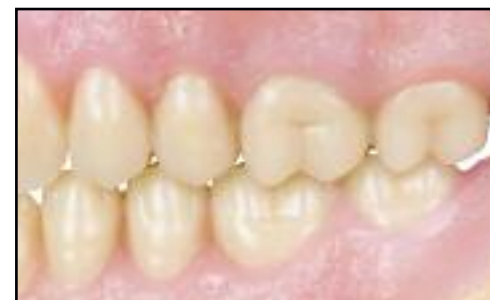**Figure 5.** Illustrated is an occlusal view of the setting of the maxillary posteriors.

### 30° Posteriors - Articulation of mandibular first molar

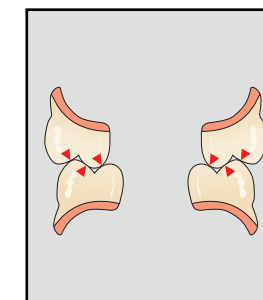
Balanced articulation contributes greatly to the comfort and efficiency of complete dentures. Without balance there may be greater resorption, less efficiency, and a recurrence of sore spots. Balanced occlusion can be accomplished with a minimum of effort if each tooth is brought into function.

Bear in mind that the mandibular first molar is a key tooth in articulation. If careful attention is paid to the positioning of this tooth, articulation of the remaining posteriors will be greatly facilitated.

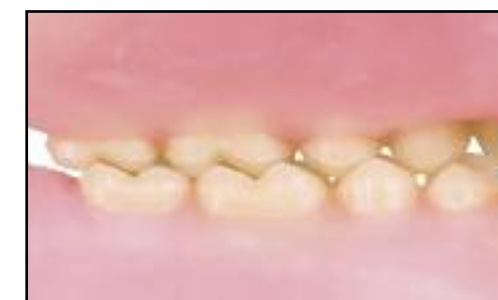### 30° Posteriors: The Completed Tooth Arrangement In All Relations



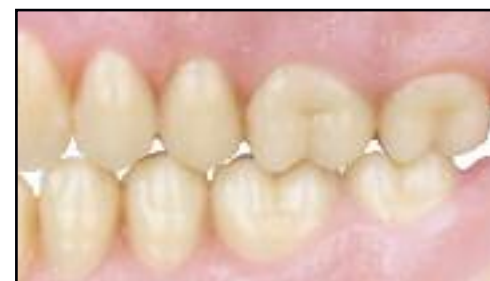**Figure 6.** Centric occlusion, buccal view.



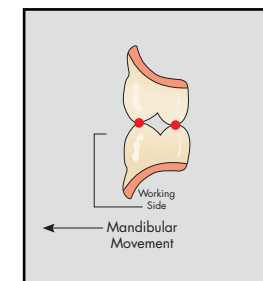
**Figure 7.** Cross section of centric occlusion.



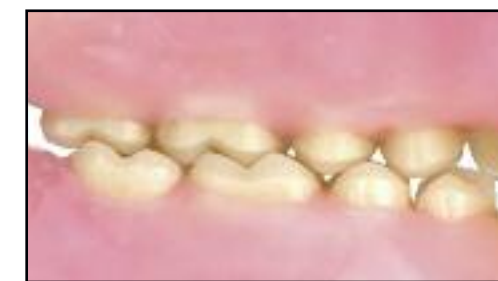**Figure 8.** Centric occlusion, lingual view.



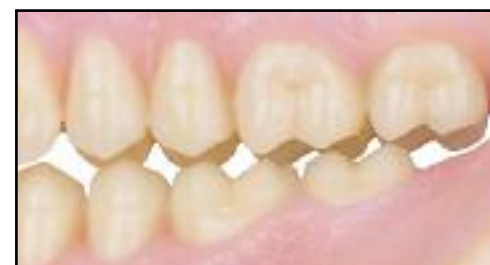**Figure 9.** Working occlusion, buccal view.



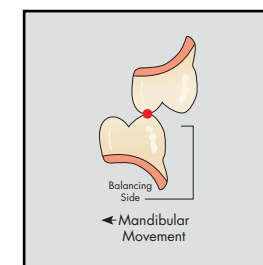
**Figure 10.** Cross section of working occlusion.



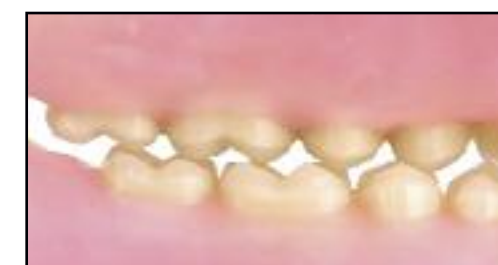**Figure 11.** Working occlusion, lingual view.



**Figure 12.** Balancing occlusion, buccal view.

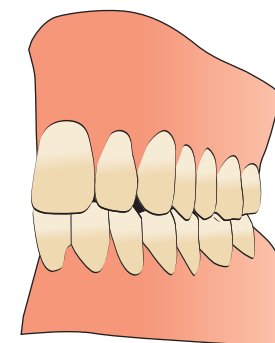


**Figure 13.** Cross section of balancing occlusion.

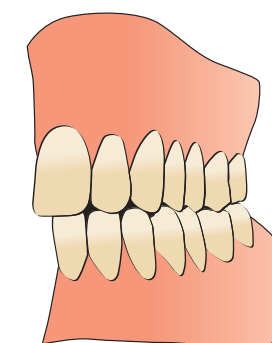


**Figure 14.** Balancing occlusion, lingual view.

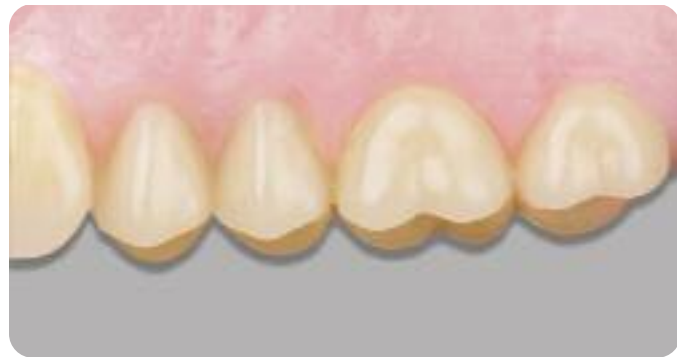Note: Arrangements shown are average. Modifications may be made as needed for a given situation.



**Figure 15.** Centric.



**Figure 16.** Working. No Cuspal Disclusion.



Dentsply Sirona 33° Posteriors are ideally designed for complete dentures and removable partial dentures which oppose natural teeth. They are a standard of excellence for maxillary and mandibular complete dentures where an anatomical tooth form is preferred or indicated.

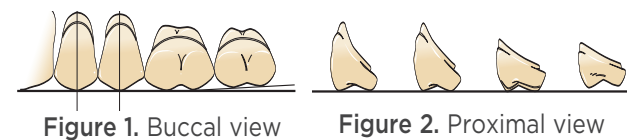
Cuspal contours are comparable to those of moderately worn natural teeth. Their inclinations and well defined sulci provide pathways which are adaptable to most requirements in complete and partial denture construction.

### Arranging Dentsply Sirona 33° maxillary posterior teeth

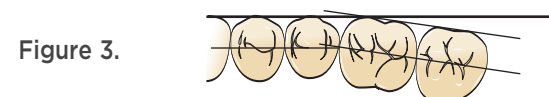


The procedures described are normal methods. Occasionally, compromises must be made for mechanical reasons dictated by the conditions present. It may be necessary, for the purpose of creating required tongue room, to alter the position of the posterior teeth.

The master carvings of Dentsply Sirona 33° posterior teeth were planned to simplify occlusion and articulation. The relationship of the various cusps of the maxillary posterior teeth should be related to a flat occlusal plane for easy initial positioning and later occlusion and articulation with the mandibular posterior teeth. An illustration of initial positioning of each tooth and the relationship of each cusp to a flat occlusal plane is shown in Figures 1 and 2.



1. Place the maxillary first premolar with its long axis at right angles to the occlusal plane. The buccal and lingual cusps are placed on the plane.
2. Place the maxillary second premolar in a similar manner. Align the buccal surfaces of the premolars and the canine with the edge of an occlusal plane (see Figure 3).



**Please note:** Portrait® IPN® 33° posteriors can be aligned with a straight edge on the lingual for faster set-ups (see 10°, page 18).

# Posteriors 33°

## Description:

Fully anatomical, long crown forms and long buccal-short bite moulds available.

## Indications For Use:

Ideal for use with partial dentures, in combination cases and implant overdentures; also for use in full dentures.

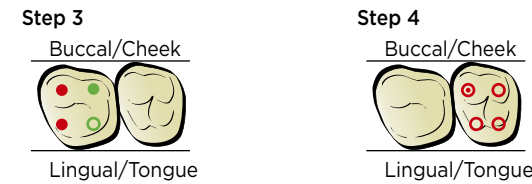
## Ridge Type:

Healthy ridge with minor resorption.

## Recommended Technique:

Bilateral Balanced and/or Lingualized Occlusion.

3. The mesiobuccal and mesiolingual cusps of the maxillary first molar touch the occlusal plane (red dots in Step 3). The distobuccal cusp (green dot) is raised about 1/2 mm and the distolingual cusp (green circle) is raised about 1/2 to 3/4 mm above the plane.



4. All the cusps of the second molar are raised from the occlusal plane following the position of the first molar (red circles). The mesiobuccal cusp (red dot) should be about 1 mm from the occlusal plane.
5. Follow the same procedure in placing the posteriors on the opposite side.
6. An occlusal view of the positioning of Dentsply Sirona 33° maxillary posteriors is illustrated in Figure 3, Page 28.

A straight edge may be used to align the labial ridge of the canine, the buccal ridge of the first and second premolars, and the mesiobuccal ridge of the first molar.

The buccal ridges of the molars may be similarly aligned, but angled slightly inward. This is an average arrangement, and modifications can be made as individual conditions indicate.



For the lingualized occlusion technique using 33° posteriors over 22° posteriors, see pages 9 and 14.

## Dentsply Sirona 33° Posteriors - Articulation of mandibular first molar

Bilateral balanced occlusion contributes greatly to the comfort and efficiency of complete dentures. Without balance there may be greater resorption, less efficiency, and a recurrence of sore spots. Balanced occlusion can be accomplished with a minimum of effort if each tooth is brought into function.

Keep in mind that the mandibular first molar is a key tooth in articulation. If careful attention is paid to the positioning of this tooth, articulation of the remaining posteriors will be greatly facilitated.

## 33° Posteriors: The Completed Tooth Arrangement In All Relations

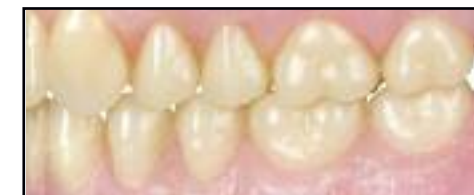

Figure 4. Centric occlusion, buccal view.

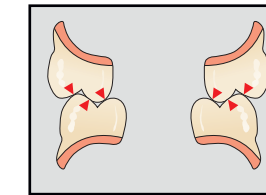


Figure 5. Cross section of centric occlusion.

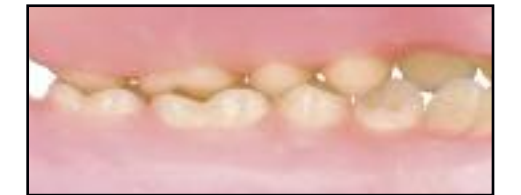

Figure 6. Centric occlusion, lingual view.

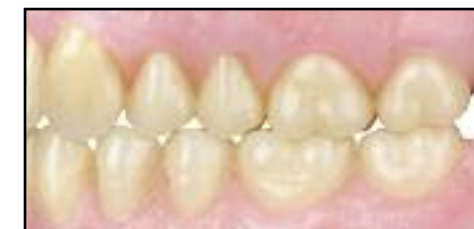

Figure 7. Working occlusion, buccal view.

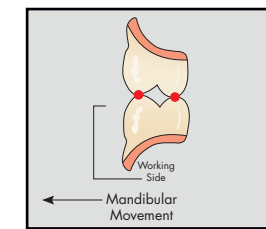


Figure 8. Cross section of working occlusion.

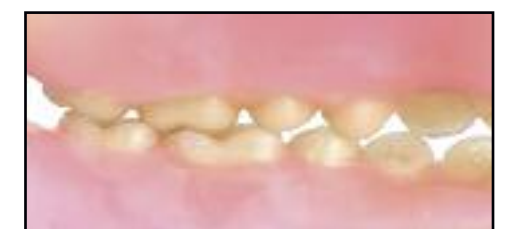

Figure 9. Working occlusion, lingual view.

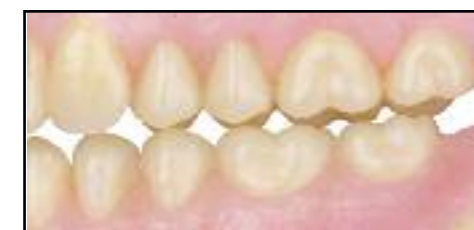

Figure 10. Balancing contact, buccal view.

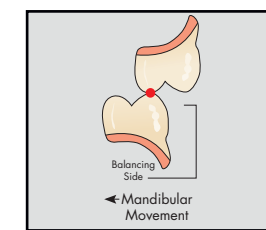


Figure 11. Cross section of balancing occlusion.

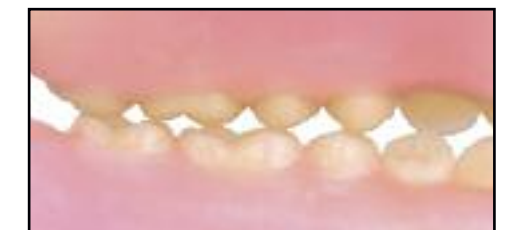
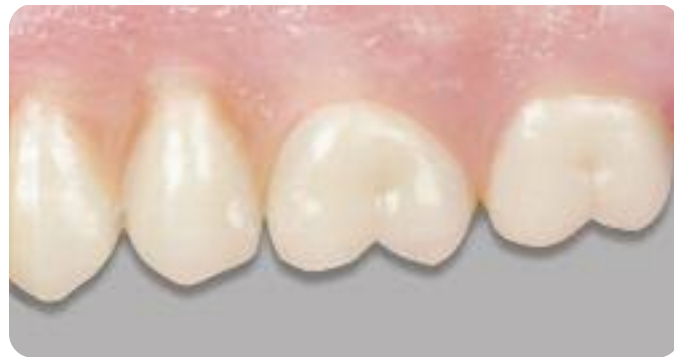
Figure 12. Balancing contact, lingual view.

Note: Arrangements shown are average. Modifications may be made as needed for a given situation.





# Posteriors 40°

(EuroLine®)

## Description:

Fully anatomical, long crown form.

## Indications For Use:

Ideal for use with partial dentures, in combination cases and implant overdentures; also for use in full dentures.

## Ridge Type:

Healthy ridge with minor resorption.

## Recommended Technique:

Bilateral Balanced and/or Lingualized Occlusion.

Designed by master dental technicians in Europe, Dentsply Sirona Portrait® IPN® 40° posterior teeth are fully anatomical. Their wider, deeper occlusal table and longer crown form integrate more completely with natural dentition. This young anatomic form makes them ideally suited for use in removable partial dentures and combination cases.

Portrait 40° Posteriors are similar to the 22° posteriors in bucco-lingual and ridge lap design. This full-form tooth will fill a space and fit on a natural ridge with more stability and will more easily interdigitate with opposing natural dentition and fixed bridge restorations.

Using 30° incisal and condylar guidance, the deep cusp/fossa angles can be arranged to maximize efficiency and minimize interference. A definite occlusal stop in the central fossa area and an open ridge-groove pathway provide more freedom of movement in lateral excursions, as compared to other European posterior designs.

These teeth may be arranged with a compensating curve for bilateral balanced occlusion with complete dentures. Balancing contacts may be achieved on all teeth except the first bicuspid. Either the lowers or the uppers can be set first. When setting the upper teeth first, follow the directions provided here. If setting the lower teeth first, use a Dentsply Sirona 20° Template.

Arranging Portrait IPN 40° Posteriors in a bilateral balanced occlusion



The relationship of the cusps of the maxillary posterior teeth may be related to a flat occlusal plane for easy initial positioning and later occlusion and articulation with the mandibular posterior teeth, if necessary. An illustration of initial positioning of each tooth and the relationship of each cusp to a flat plane are shown in Figures 1 and 2.

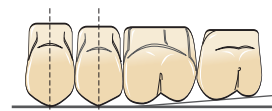


Figure 1. Buccal view

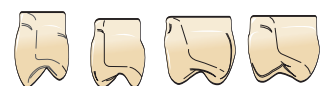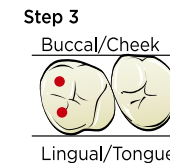


Figure 2. Proximal view

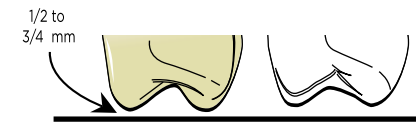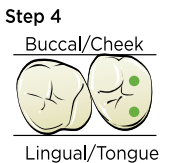


Figure 2B. Cusp view

1. Place the maxillary premolars with their long axes at right angles to the occlusal plane (Figure 1). A slight mesial inclination is also acceptable. The buccal cusps of the premolars should touch the plane and the lingual cusp of the maxillary 1st premolar should be raised approximately 1/2 to 1 mm above the plane (Figures 1 and 2).
2. The first and second molars may be set with their long axes inclined slightly mesially.
3. The mesiobuccal cusp and the mesiolingual cusp of the first molar (red dots) are approximately 1/2 to 3/4 mm above the plane (Figures 1, 2, 2B and Step 3 illustration).



4. The second molar is set to follow the position of the first molar. The distolingual cusp and the distobuccal cusps (green dots) are approximately 1-1/2 mm above the plane (Figures 1, 2, 2B and Step 4 illustration).



5. Follow the same procedure in placing the posterior teeth on the opposite side.

A straight edge may be used on the facial to align the buccal ridge of the first and second premolars and the mesiobuccal ridge of the first molar (Figure 3). The buccal ridges of the molars may be similarly aligned, but angled slightly inward. This is an average arrangement and modifications can be made as individual conditions indicate.

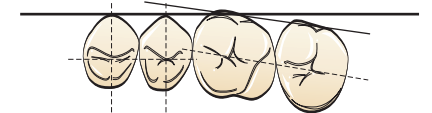


Figure 3. Occlusal surface view

## 40° Posteriors: The Completed Tooth Arrangement In All Relations

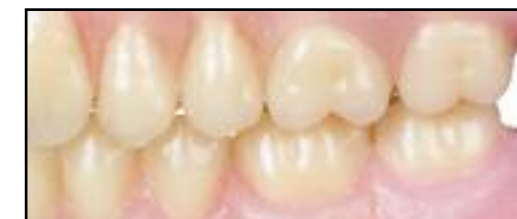

Figure 4. Centric occlusion, buccal view.

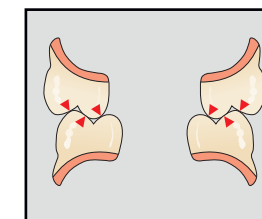


Figure 5. Cross section of centric occlusion.

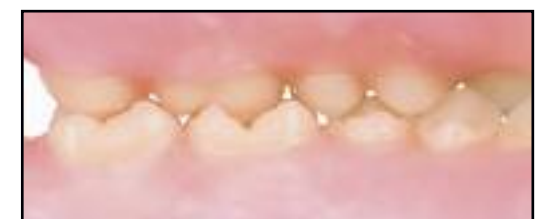

Figure 6. Centric occlusion, lingual view.

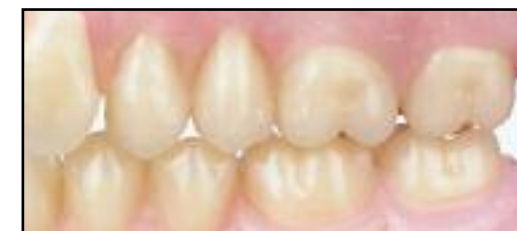

Figure 7. Working occlusion, buccal view.

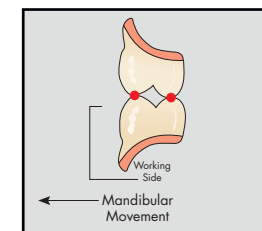


Figure 8. Cross section of working occlusion.

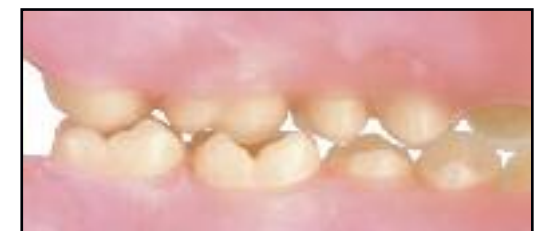

Figure 9. Working occlusion, lingual view.

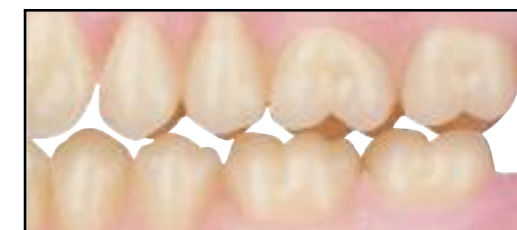

Figure 10. Balancing position, buccal view.

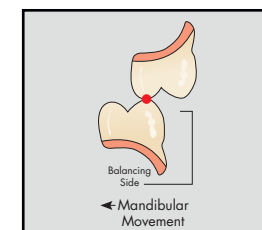


Figure 11. Cross section of balancing occlusion.

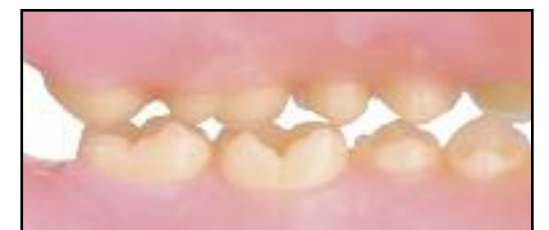
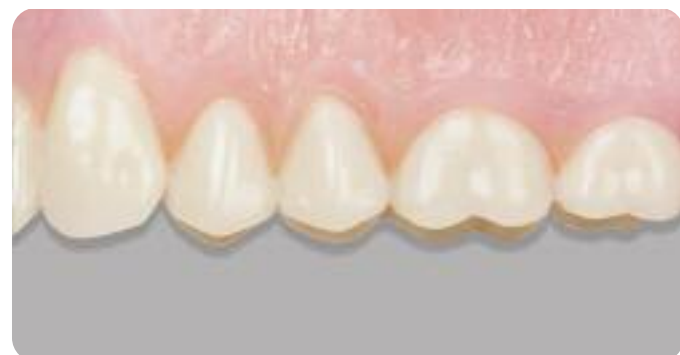
Figure 12. Balancing position, lingual view.

Note: Arrangements shown are average. Modifications may be made as needed for a given situation.



# Appendix for Related Information

## Stabilized Baseplates

## Wax Occlusion Rims

## Tooth Morphology

This chapter contains selected information and procedures that are important to routinely achieving successful denture tooth arrangement.

**Stabilized Baseplate** – The purpose of a stabilized baseplate is to provide a foundation representing the base of a complete denture, which is used for making jaw relation records and arranging denture teeth. Baseplates should be strong and rigid, fit accurately, and be stable without rocking. The baseplate borders should be full and rounded as in the finished denture. If desired, a post-dam or posterior palatal seal can be added to the upper to give additional stability when placed in the mouth.

**Wax Occlusion Rims** – The purpose of occlusion rims is to define the position, size and shape of the teeth to be replaced. They enable dental professionals to establish and record the correct vertical dimension of occlusion, the occlusal registration and provide a positioning template to set denture teeth for proper lip support.

In overall design, the wax occlusal rims should be smooth, centered buccolingually over and parallel to the residual ridge crest, and properly contoured. In the anterior, use a millimeter ruler to measure the distance from the mucobuccal fold to the occlusal plane: 22mm on the upper and 18mm on the lower. (These measurements are for the “average” patient and may be increased or decreased by the dentist.) The anterior upper should extend horizontally about 6 to 8mm from the middle of the incisive papilla.

The posterior plane of occlusion should not exceed 2/3 of the retromolar pad height on the lower and 8mm up from the tuberosity on the upper. The anterior occlusal width should be about 3 to 4mm, and the posterior width at the first molar region should be between 8 to 10mm.



**Figure 1.** Mark and smooth/trim the wax to these dimensions.



**Figure 2.** The anterior portion of the maxillary occlusal rim is labially oriented, i.e. it slants to the anterior.

**Figure 3.** The posterior areas of the wax rims should be trimmed at a 30° angle to eliminate potential interference during bite registration procedures.

## Posterior Mould/Shade Availability

### 0° Non-Anatomical (Flat-Plane) Posteriors

	Moulds	Shades
Portrait® IPN® 0°	630 632 634	Portrait IPN Shades (All Shades): P1, P2, P3, P3.5, P4, P11, P12, P13, P14, P21, P22, P23, P24, P32, P33, P34, P59, P62, P65, P66, P67, P69, P77, P81, PW2, PW4, PW7
Bioform® IPN® 0° (Monoline®)	429 431 433	Bioform IPN Shades (All Shades): B51, B52, B53, B54, B55, B56, B59, B62, B63, B65, B66, B67, B69, B77, B81, B83, B84, B85, B91, B92, B93, B94, B95, B96
TruExpression® MXL 0°	429 431 433 630 632 634	TruExpression Shades (All Shades): A1, A2, A3, A3.5, A4, B1, B2, B3, B4, C1, C2, C3, C4, D2, D3, D4, i2, i4
Classic® 0°	29M 31M 33M	Classic Shades (All Shades): A1, A2, A3, A3.5, A4, B1, B2, B3, B4, C1, C2, C3, C4, D2, D3, D4, 59C, 62C, 65C, 66C, 67C, 69C, 77C, 81C, CW2

\*Supplied in sets of 1x8 only (consisting of 2 blocks of 4 right and left - upper or lower).

## Posterior Mould/Shade Availability

### 10° Semi-Anatomical Posteriors

	Moulds	Shades
Portrait® IPN® 10° (Anatoline®)	330 332 334 336	Portrait IPN Shades (All Shades): P1, P2, P3, P3.5, P4, P11, P12, P13, P14, P21, P22, P23, P24, P32, P33, P34, P59, P62, P65, P66, P67, P69, P77, P81, PW2, PW4, PW7
Bioform® IPN® 10° (Anatoline®)	330 332 334	Bioform IPN Shades (All Shades): B51, B52, B53, B54, B55, B56, B59, B62, B63, B65, B66, B67, B69, B77, B81, B83, B84, B85, B91, B92, B93, B94, B95, B96
TruExpression® MXL 10°	330 332 334	TruExpression Shades (All Shades): A1, A2, A3, A3.5, A4, B1, B2, B3, B4, C1, C2, C3, C4, D2, D3, D4, i2, i4
Classic® 10°	F30 F32 F33	Classic Shades (All Shades): A1, A2, A3, A3.5, A4, B1, B2, B3, B4, C1, C2, C3, C4, D2, D3, D4, 59C, 62C, 65C, 66C, 67C, 69C, 77C, 81C, CW2

## Posterior Mould/Shade Availability

### 20° Semi-Anatomical Posteriors

	Moulds	Shades
Portrait® IPN® 20°	29M, L 31M, L 33M, L 35M	Portrait IPN Shades (All Shades): P1, P2, P3, P3.5, P4, P11, P12, P13, P14, P21, P22, P23, P24, P32, P33, P34, P59, P62, P65, P66, P67, P69, P77, P81, PW2, PW4, PW7
Bioform® IPN® 20° *	29S, M, L 31S, M, L 33M, L	Bioform Shades (All Shades): B51, B52, B53, B54, B55, B56, B59, B62, B63, B65, B66, B67, B69, B77, B81, B83, B84, B85, B91, B92, B93, B94, B95, B96
TruExpression® MXL 20°	29M 31M 33M	TruExpression Shades (All Shades): A1, A2, A3, A3.5, A4, B1, B2, B3, B4, C1, C2, C3, C4, D2, D3, D4, i2, i4
Classic® 20°	29M, L 31M, L 33M	Classic Shades (All Shades): A1, A2, A3, A3.5, A4, B1, B2, B3, B4, C1, C2, C3, C4, D2, D3, D4, 59C, 62C, 65C, 66C, 67C, 69C, 77C, 81C, CW2



Figure 1.

**Figure 1:** \*Bioform IPN 20° moulds are long buccal-short lingual moulds. They are specially designed for short bite and partial cases. They are engineered with a “scooped-out” ridge lap which eliminates unnecessary bulk and reduces grinding to a minimum.

## Posterior Mould/Shade Availability

### 22° Posteriors (BioStabil®)

	Moulds	Shades
Portrait® IPN®	530 532 533 536*	Portrait IPN Shades (All Shades) P1, P2, P3, P3.5, P4, P11, P12, P13, P14, P21, P22, P23, P24, P32, P33, P34, P59, P62, P65, P66, P67, P69, P77, P81, PW2, PW4, PW7
	* Special large fully contoured mould ideal for implant and partial cases where indicated.	

### 30° Posteriors

Bioform® IPN® 30°  
(Pilkington-Turner®)

Moulds	Shades
230S, M, L, LS† 233M, L	Bioform IPN Shades (Limited) B59, B62, B65, B66, B67, B69, B77, B81



Figure 2.

**Figure 2:** †Bioform IPN 33° mould 230LS is specially designed for short bite and partial cases. It is engineered with a “scooped-out” ridge lap which eliminates unnecessary bulk and reduces grinding to a minimum.

## Posterior Mould/Shade Availability

### 33° Posteriors

	Moulds	Shades
Portrait® IPN® 33°	30M, L 32M, L 34M, L	Portrait IPN Shades (All Shades) P1, P2, P3, P3.5, P4, P11, P12, P13, P14, P21, P22, P23, P24, P32, P33, P34, P59, P62, P65, P66, P67, P69, P77, P81, PW2, PW4, PW7
Bioform® IPN® 33°	30M, L 32M, L 34M, L	Bioform IPN Shades (All Shades) B51, B52, B53, B54, B55, B56, B59, B62, B63, B65, B66, B67, B69, B77, B81, B83, B84, B85, B91, B92, B93, B94, B95, B96
TruExpression® MXL 33°	30M 32M 34M	TruExpression Shades (All Shades): A1, A2, A3, A3.5, A4, B1, B2, B3, B4, C1, C2, C3, C4, D2, D3, D4, i2, i4
Classic® 33°	30M, L, LS* 32M, L, LS* 34M, L, LS*	Classic Shades (All Shades) A1, A2, A3, A3.5, A4, B1, B2, B3, B4, C1, C2, C3, C4, D2, D3, D4, 59C, 62C, 65C, 66C, 67C, 69C, 77C, 81C, CW2



Figure 3.

**Figure 3:** \*Classic 33° moulds 30LS, 32LS, and 34LS are specially designed for short bite cases. They are engineered with a “scooped-out” ridge lap which eliminates unnecessary bulk and reduces grinding to a minimum.

### 40° Posteriors

	Moulds	Shades
Portrait® IPN® 40° (EuroLine®)	730 732 734	Portrait IPN Shades (All Shades) P1, P2, P3, P3.5, P4, P11, P12, P13, P14, P21, P22, P23, P24, P32, P33, P34, P59, P62, P65, P66, P67, P69, P77, P81, PW2, PW4, PW7
TruExpression® MXL 40°	c31 c34 c36 c34R** c36R** c34XR† c36XR† c34XL† c36XL†	TruExpression Shades (All Shades): A1, A2, A3, A3.5, A4, B2, B3, B1, B2, B3, B4, C1, C2, C3, C4, D2, D3, D4, i2, i4

\*\*R Variation: Exactly the same dimensions as normal moulds, except for a reduction in the ridge laps.

†XL/XR Variation: Enlarged premolars, molar size is unchanged.

## Portrait® IPN® and Bioform® IPN® Combination Table

Select upper anterior mould form, and use table to determine recommended lower anterior and posterior options.

Portrait® IPN® and Bioform® IPN® Anteriors		Portrait® IPN® and Bioform® IPN® Posteriors Moulds							
Anterior Upper Mould No.	Articulates - With Anterior Lower	Non-Anatomical		Semi-Anatomical			Anatomical		
		Portrait IPN 0°	Bioform IPN 0° Mondline	Portrait IPN 10°/ Bioform IPN Anatoline	Portrait IPN/ Bioform IPN 20°	Portrait IPN 22°	Bioform IPN PT 30°	Portrait IPN/ Bioform IPN 33°	Portrait IPN 40° EuroLine
11G	R	632	433	332	33M	532	233L	32L	732
11H	S, W	634	433	334, 336 <sup>1</sup>	33M, 35M1	533, 536	233M, 233L	34M	734
12E	M, N	632	431	332	31M	532	230L, 233M	32L	732
12F	N	632	431	332	31M, 31L	532	233M	32L	732
12G	G, R, V	634	433	334	33M	533	233M	34M	734
13D	B, C	630	431	330	31S, 31M	530	230M	30L, 30LS	730
13E	H	630	431	330	31M	530	230L	30L	730
21C	C	630	429	330	29M, 29L	530	230L	30L	730
21D	F	630	429	330	29L	530	230L	30L	730
21E	O	632	431	332	31L, 33L	532	233L	32L	732
21F	L	632	431	332	31M, 31L	532	230L	30L	732
21G	W	634	433	334	33L	533	233L	34L	734
21J	I, K1, Rx	634	433	334, 336	33M, 35M	533, 536	233M, 233L	34L	734
21X	P	632	431	332	31M	532	233M	32M	732
22C	C	630	429	330	29M	530	230M	30M	730
22E	H	630	429	330	29L	530	230L	30L	730
22G	O, P	632	431	332	31M	532	233M	32M	732
22H	P	634	433	334	33M	533	233L	34L	734
24F	F, G, H	632	431	332	31M	532	230L	32L	732
25G	R	634	433	334	33M	533	233M	34L	734
31F	J, O, P, S	632	433	332	31L, 33L	532	233L	32L	732
32B	C	630	429	330	29M	530	230M	30M	730
32E	H	632	431	332	31M	532	230M	32M	732
32G	S	634	433	334	33M	533	233M	34L	734
35E	G	632	431	332	31M, 31L	532	230L	30L	732
36F	N, X	632	433	332	33M	532	233M	32L	732
41J <sup>2</sup>	I, K1, Rx	634	433	336	35M	536	233L	34L	734
42D	F	630	429	330	29M, 29L	530	230L	30L	730
42F	H	632	431	332	31M	532	230L	32L	732
42G	O, P	632	431	332	31M, 33M	532	233M	32M	732
43D	C	630	429	330	29M, 29L	530	230L	30L	730
43F	M, N, X	632	431	332	31M	532	230L	32M	732
45F	J, O	632	431	332	31L	532	233M	32L	732
45H	R, V	634	433	334	33M	533	233L	34L	734
52C	C, D	630	429	330	29M	530	230M	30M	730
54F	J, N	632	431	332	31L	532	230L	32L	732
55D	E	630	429	330	29M	530	230M	30M	730
55F	M	632	431	332	31M	532	230L	32L	732
56G	P, V	632	433	332	31M, 33M	533	233M	32M	732
62D	F	630	429	330	29L	530	230L	30L	730
62E	F	630	431	330	31M, 31L	530	230L	30L	730
62G	K1, R, Rx	634	433	334, 336	33M, 35M	533	233L	34L	734
65G	J, O	634	433	334	33M	533	233M	34L	734
65H	S, U	634	433	334	33M, 33L	533	233M, 233L	32L	734
74E	L	630	429	330	29M, 29L	530	230L	30L	730
74H	K1	634	433	334, 336	33M, 33L	533	233L	34L	734
75E	N	630	429	330	29L	530	230L	30L	730
75G	R, V	632	431	332	31M	532	230L	32L	732
76D	C	630	429	330	29M	530	230M	30M	730
A84	N	632	431	332	31M	532	230L	32L	732

<sup>1</sup> Indicated for upper denture combinations only. <sup>2</sup> Softening the canine cusps may yield the best aesthetic results for certain posteriors.

## TruExpression® Combination Table

Select upper anterior mould form, and use table to determine recommended lower anterior and posterior options.

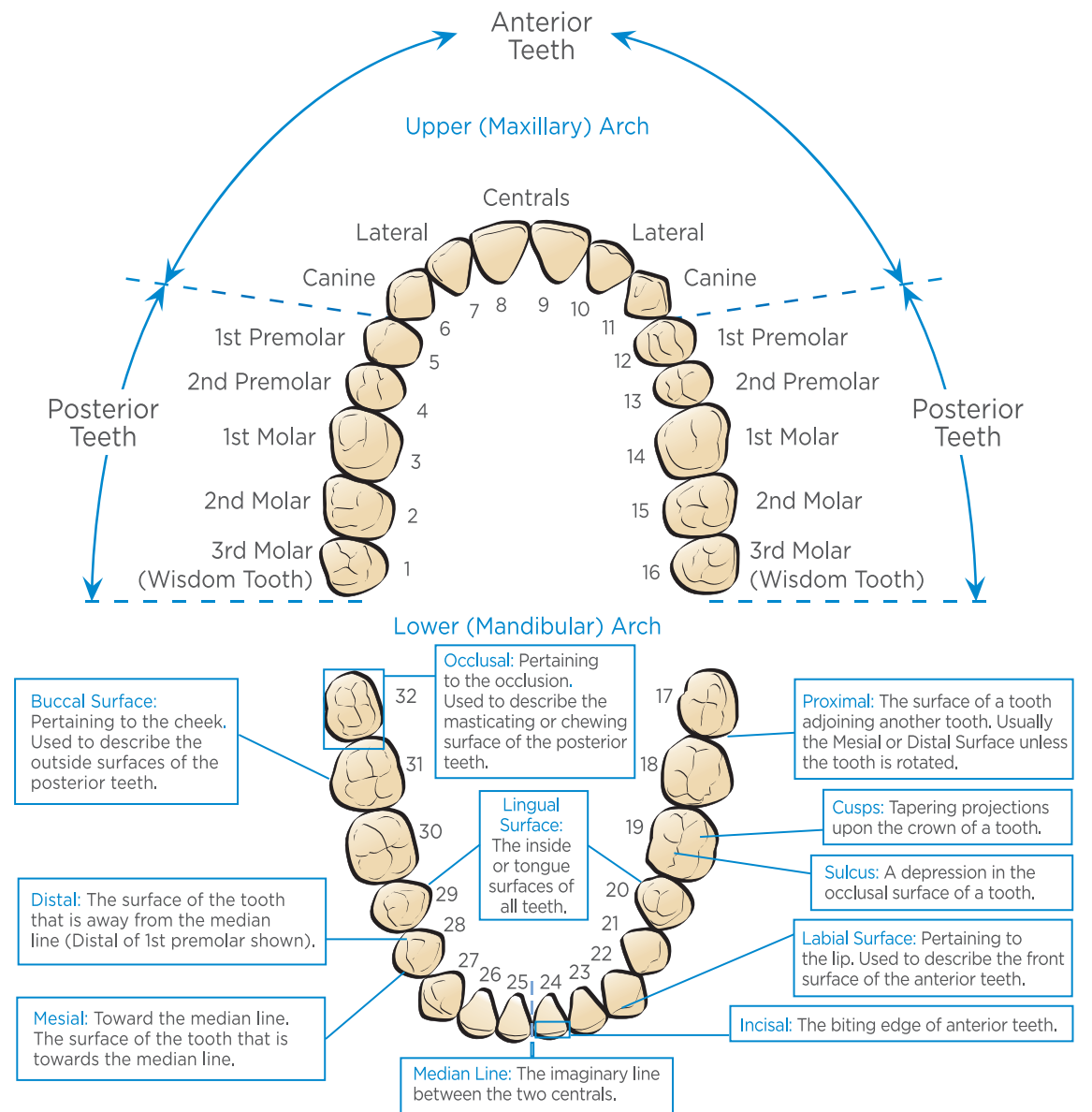
TruExpression® Anteriors		TruExpression® Posterior Moulds				
Anterior Upper Mould No.	Articulates with Anterior Lower	Non-Anatomical	Semi-Anatomical		Anatomical	
		0°	10°	20°	33°	40°
11H	S	433, 634	334	33M	34M	c36, c36R, c36XL, c36XR
12E	N	431, 632	332	31M	32M	c34, c34R, c34XL, c34XR
12G	R	433, 632	334	33M	34M	c36, c36R, c36XL, c36XR
13E	H	431, 630	330	31M	30M	c31, c34XL, c34XR
14G	Hc, Lc	433	334	33M	34M	c34, c34R, c34XL, c34XR
14J	Lc, Tc	433	334	33M	34M	c36, c36R, c36XL, c36XR
15FX	Dc, Fc, Hc	431	332	31M	32M	c34, c34R, c34XL, c34XR
21C	C	429, 630	330	29M	30M	c31, c34XL, c34XR
21D	F	429, 630	330	29M	30M	c31, c34XL, c34XR
21J	K1	433, 634	334	33M	34M	c36, c36R, c36XL, c36XR
22E	H	429, 630	330	29M	30M	c31, c34XL, c34XR
24F	F, H	431, 632	332	31M	32M	c34, c34R, c34XL, c34XR
24G	Hc, Lc	433	334	33M	34M	c34, c34R, c34XL, c34XR
25FX	Dc, Fc, Hc	433	334	33M	34M	c34, c34R, c34XL, c34XR
26D	Bc, Fc	431	330	31M	30M	c31
26E	Dc, Fc, Hc	431	332	31M	32M	c34, c34R, c34XL, c34XR
26FX	Bc, Dc	431	332	31M	32M	c31
32E	H	431, 632	332	31M	32M	c34, c34R, c34XL, c34XR
42D	F	429, 630	330	29M	30M	c31, c34XL, c34XR
42F	H	431, 632	332	31M	32M	c34, c34R, c34XL, c34XR
42G	P	431, 632	332	31M	32M	c34, c34R, c34XL, c34XR
45H	R	433, 634	334	33M	34M	c36, c36R, c36XL, c36XR
55D	E	429, 630	330	29M	30M	c31, c34XL, c34XR
62G	K1, R	433, 634	334	33M	34M	c36, c36R, c36XL, c36XR
65G	Dc, Hc	433, 634	334	33M	34M	c36, c36R, c36XL, c36XR
75E	N	429, 630	330	29M	30M	c31, c34XL, c34XR

## Classic® Combination Table

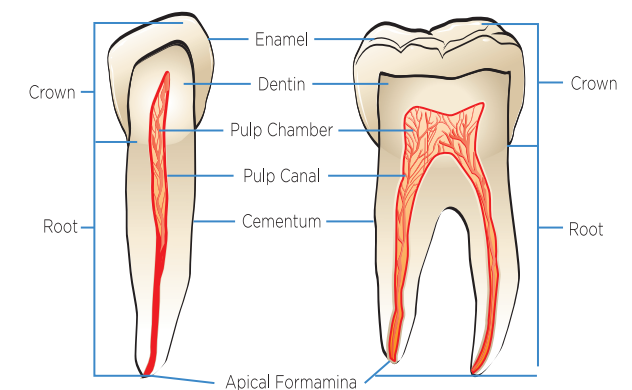
Select upper anterior mould form, and use table to determine recommended lower anterior and posterior options.

Classic® Anteriors		Classic® Posteriors			
Upper Mould No.	Articulates with Lower Mould	Combines with 33° Posterior Mould	Combines with 20° Posterior Mould	Combines with 10° Posterior Mould	Combines with 0° Posterior Mould
133	2C	30M	29M	F30	29M
134	3D	30M	31M	F33	31M
135	46	32M	33M	F33	33M
136	46	34M	33M	F33	33M
2D	2D	30L	29L	F32	29M
3D	3D	30M	31M	F33	31M
1N	46	30L	31M	F32	31M
2N	2N	30L	29L	F30	29M
2P	2P	30L	31L	F33	31M
A24	3N	30M	29M	F30	29M
A25	2E	30M	31M	F33	31M
A26	46	30M	31M	F33	31M
3M	3M	30M	29M	F30	29M
3N	3N	30L	31M	F32	31M
3P	3P	34M	33M	F33	33M
4M	3M	30M	29M	F30	29M
4N	2N	30L	31M	F30	31M
263	2N	30M	29L	F32	29M
264	2E	30M	31L	F33	31M
266	26	34L	33M	F33	33M
267	3R	34L	33M	F33	33M
268	3R	34L	31L	F33	33M

## Tooth Anatomy Chart



## Anatomy of Natural Teeth



DENTSPLY International  
570 West College Ave, York PA 17401  
www.dentsplysirona.com  
(800) 243-1942

©2017 Dentsply Sirona. All rights reserved.

CE 0086 Rx<sup>only</sup>  
4087-A Rev.4 (08/2017)

