

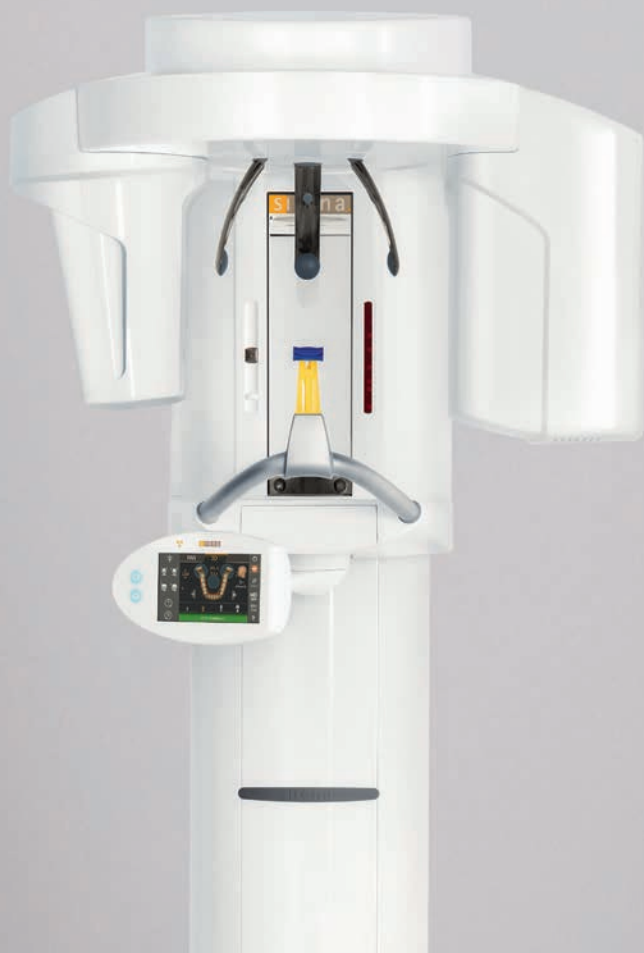THE DENTAL
SOLUTIONS
COMPANY™



Orthophos SL – as versatile as practice life.

Cases in practice

www.dentsplysirona.com



Contents

- 03 | Jörg Haist: Editorial
- 04 | Dr. Björn Ludwig: Easy treatment monitoring through DVT
- 06 | Dr. Dr. Dieter Hültenschmidt: On the safe side thanks to Low Dose
- 08 | Dr. Gerd Frahsek, Carolin Müller: Reliable planning for an optimal workflow
- 10 | Marcin Wojtunik: SICAT Air and OPTISLEEP allow 3D analysis and therapy of the upper airways
- 12 | Guido Pawlik: SICAT Air and OPTISLEEP: Successful therapy of obstructive sleep apnea
- 14 | Dr. Tomas Lang: 3D Endo™ software – safely through planning
- 16 | Dr. Dae-Hyun Lee: Optimum restoration in cases of root resorption
- 18 | PD Dr. Dr. Lutz Ritter: Lowest possible radiation exposure in pediatrics: The Low Dose mode
- 20 | Dr. Kaveer Ratan and Dr. Clifford Yudelman: Confident decision-making in treating dental traumas
- 22 | Jörg Haist: Stand-alone is out – Connectivity is now in

Dear readers,



Progressive technical developments present dentists with new opportunities to optimize their work in the practice and to improve results. X-raying is a good example of this: The switch from analog to digital X-ray brings many advantages. However, the rich variety leads to uncertainty regarding the equipment required for the best X-ray results. The answer depends on the indication at hand: 2D X-ray images are adequate for many indications for others not. For implant planning, the suspicion of misplaced teeth or other orthodontic or endodontic applications, the use of a 3D image is recommended, as the additional dimension offers more assurance with the diagnosis.

To be optimally prepared for different treatment situations, Dentsply Sirona provides the practitioner with the greatest flexibility with Orthophos SL, the complete X-ray solution. Orthophos SL has three modes that you can use according to the indication and which offer you the best combination of image quality and dose level: High definition images reveal the finest details, while standard definition optimizes dose exposure for images, and the new low dose mode allows 3D images with dosage in the 2D range for a large number of clinical situa-

tions. This versatility helps in routinely meeting the highest demands, even for complex diagnoses and adhering to the ALARA (As Low As Reasonably Achievable) principle.

With this brochure, we would like to inform you about the varied applications for Orthophos SL based on brief user reports. Here we present you different cases from the areas of implantology, orthodontics, the use of low doses for follow-up care and for treating sleep apnea, which help demonstrate the advantage of a complete X-ray solution for routine work in the dental practice.

Wishing you pleasant reading.

A handwritten signature in black ink that reads "Jörg Haist". The signature is written in a cursive, slightly slanted style.

Jörg Haist
Head of Product Management
Imaging Systems

Easy treatment monitoring through DVT

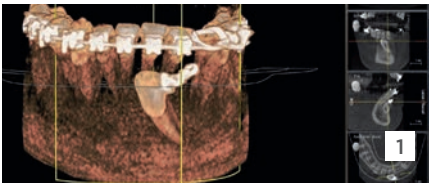
Author Dr. Björn Ludwig, Traben Trarbach, Germany

3D diagnostics has increased considerably in significance in recent years. More and more dentists of widely differing specializations are discovering the benefits of digital volume tomography (DVT) in diagnostics and the numerous innovative options they provide for planning and conducting therapies. The Low Dose mode unlocks a simple option for treatment monitoring with low dose radiation.

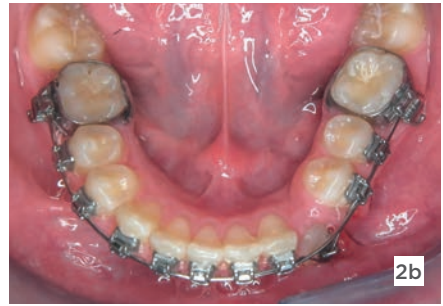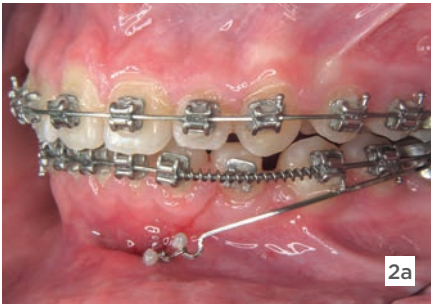
Impacted and displaced teeth are no rarity at an orthodontic practice. Third molars and upper canines are most often affected. Surgical exposure upper canines and the following orthodontic tooth alignment are routine surgeries in dentistry. To make the procedure as atraumatic as possible, the position of canines should be precisely determined and verified by means of a DVT to ensure problem-free treatment, as shown in the following case report.

Particularly in growing patients, which represent the majority of orthodontic patients, the radiation exposure should be selected as low as possible. Here the Low Dose Mode offers a new radiation-minimizing option.

In this particular young patient, the lower left canine was diagnosed and found to be displaced. Many such cases require orthodontic therapy to elongate the impacted tooth and align it correctly into the dental arch. For the further treatment of the displaced tooth, the attending oral surgeon opted to align the tooth by means of a fixed device using mechanical extrusion and a double arch technique, and took corresponding action by attaching brackets.



1 Preoperative DVT in the Orthophos SL Low Dose mode.



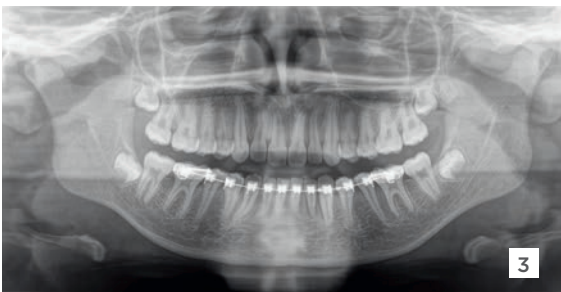2 Orthodontic alignment of the surgically exposed canine.

The perpendicular movement of a tooth requires the introduction of a vectorially directed, constantly acting force. The treatment is minimally invasive, time-saving, and atraumatic and is almost painless. Correspondingly, an extrusion pin was inserted on the displaced tooth and fixed to the tooth using a bonding technique and composite. The extrusion bar was fastened onto the brackets of the adjacent teeth.

Because of the determination of the position of canine-crown in relation to the roots of mandibular incisors (here: DVT in Low Dose Mode) orthodontic bio-mechanics could be used, that prevented a damage of neighboring roots almost comple-

tely (fig. 1). Therefore, all the risks could be assessed beforehand and the procedure made as atraumatic as possible for the patient. Thanks to the extrusion bar, the tooth was able to be successfully removed from the jaw (fig. 3).

Using radiation-reduced DVT datasets was advantageous with displaced canines in the treated case as it can supply valuable findings as to the risks and prognoses of a possible attempt at alignment. Despite the X-ray dose being low, a clinician can get information which is impossible from 2D imaging. The procedure is easier to justify to patients and shows that a physician's duty of care is upheld.



3 X-ray overview image (Orthophos SL) after alignment of the left-hand lower canine and alignment.

On the safe side thanks to Low Dose

Author Dr. med. Dr. med. dent. Dieter Hültenschmidt, Karlsruhe, Germany

Implantation in the mandible following poor preparation can give rise to grave complications in extreme cases. 3D diagnostics and planning using DVT provides us with a reliable instrument for this. If the clinical examination produces doubts about whether the jaw displays anomalies or if there is sufficient bone volume, we recommend that 3D planning should be carried out – even if this immediately involves radiation protection considerations being raised as a limiting factor.

If an additional postoperative control image is considered, DVT at the standard settings exceeds the justifiable dose for a implantation. The Low Dose Mode developed by Dentsply Sirona for the 2D/3D hybrid unit Orthophos SL crucially now enables us to make postoperative 3D control images at dose

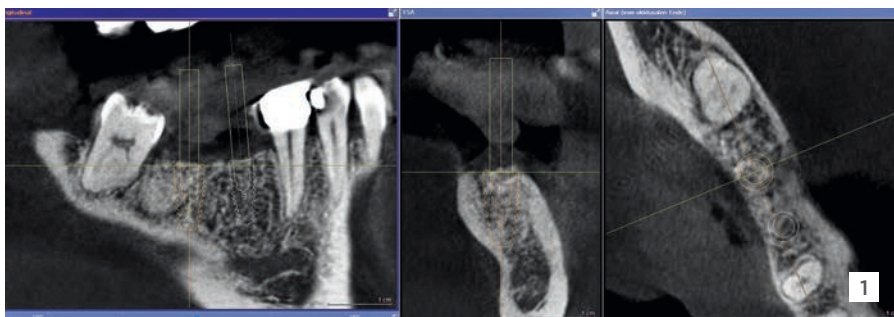
an additional reduction in the radiation dose.

In this case an approx. 55 year old patient was referred to me to have two implants inserted into regions 46 and 47. Using an Orthophos SL 3D image we identified that there was a strong reduction in bone volume towards distal in the mandible. In the Galileos Implant planning software I was able to visualize the implant, a Straumann Bone Level Tapered with an enossal diameter of 4.1 mm and a length of 10 mm, and align it in the 3D dataset in such a way as to be certain that there would be no risk of perforating the jaw. Based on the planning data a drilling template can then be ordered from SICAT in Bonn and manufactured there according to the Optiguide technique.

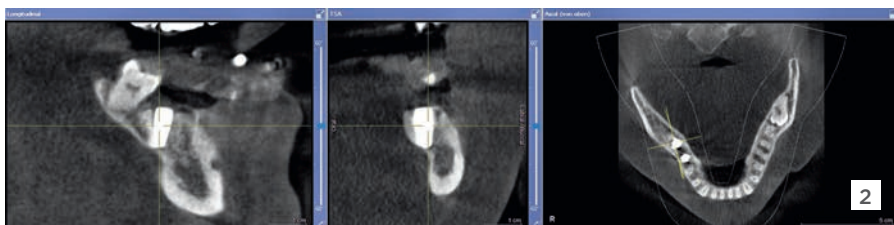
“With Low Dose and the option of limiting volume, we achieve an effective reduction in radiation dose.”

levels below those of a conventional OPG. Furthermore, the X-ray system offers the option of limiting volume to 5 cm x 5 cm and so of achieving

To check the implant position, we made a Low Dose image. In the most extreme case, perforation of the lingual cortical bone could have



1 3D planning in Galileos Implant.



2 Low dose image for follow-up.

provoked injury to the lingual nerve or a mouth floor hematoma with subsequent obstruction of the airways. Therefore here the concern was not only prompt detection of acute threatening complications, but also verification of the anatomically correctly inserted implant. Only within a limited time window after implantation is it possible to correct a less than ideally inserted implant with relatively little effort. If an implant is well osseointegrated after a few months, correction is only possible by means of consi-

derably complex surgery. In this case the control image showed that planning had been successfully implemented. As the dose was lower than with OPG, the patient was pleased to consent to the control image and her being very content with the documented result allowed me to discharge her to the referring dentist.

Reliable planning for an optimal workflow

Author Dr. Gerd Frahsek, Carolin Müller, Velbert, Germany

An unfavorable bone situation, unexpected nerve canal pathways or constricted upper airways – anatomical conditions differ from patient to patient. 3D images are invaluable in a large number of diagnoses to still be in a position to ensure good treatment. Orthophos SL 3D from Dentsply Sirona, as a complete X-ray solution, addresses this fact: Whether extremely sharp 2D panoramic images, full flexibility in 3D volumes by virtue of selectable volumes or simple, reliable patient positioning for perfect images, Orthophos SL 3D offers top image quality and a perfect workflow. Together with the Galileos Implant software, prosthetic proposals from the CEREC software can be combined with Galileos or Orthophos 3D X-ray data. The above, as well as the advantages of the integrated workflow are illustrated by the following case:

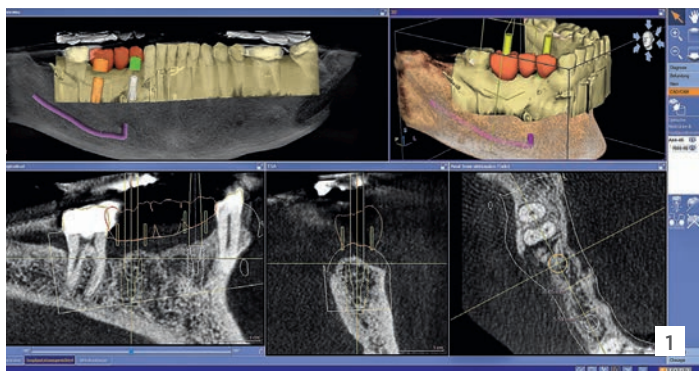
A 52-year-old male patient presented to our practice with the wish for restoration of the tooth gap in region 45 to 47. In order to analyze the starting situation and for further planning, a panoramic scanning dental X-ray (OPG) was taken with Orthophos SL 3D and planning models were fabricated. On account of the wide span, a bridge restora-

tion was problematic, so the patient decided on inserting two implants and subsequent fabrication of an implant-supported bridge.

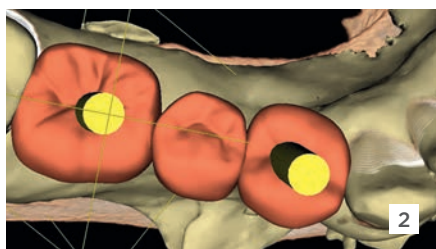
We performed digital backward planning using CEREC Integration so as to correctly predict the position of the implants. A DVT, also produced with Orthophos SL 3D, was merged with the digital impression from CEREC and a digital bridge construction. With the aid of these data, implantation could be planned in the Galileos Implant software. To ensure accurate implementation of planning and also because this case was the first undertaken by a young colleague, we chose a guided implantation technique for which we fabricated a CEREC Guide 2 drilling template. The drilling template was then milled on inLab MC X5 in the practice laboratory.

Following implantation, a DVT was produced with the Orthophos SL 3D in low dose mode for control purposes. This allowed the exact position of the implants to be determined despite the low radiation exposure (less than 50% of an OPG). The final restoration was achieved with hybrid abutments on TiBase.

Orthophos SL 3D offers an efficient, time-saving workflow that not only

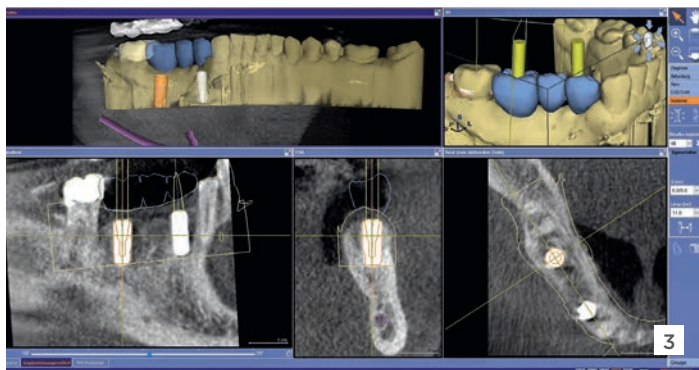


1 Matching of Orthophos SL 3D data with the prosthetic proposal in Galileos Implant.



2 Prosthetic alignment of the implant in planning.

3 By means of a low-dose recording, the implant was checked three-dimensionally.



guarantees the practitioner absolute peace of mind during treatment, but also with regard to monitoring and documentation of the case. Patients are also glad about perfect results in fewer sittings.

SICAT Air and OPTISLEEP allow 3D analysis and therapy of the upper airways

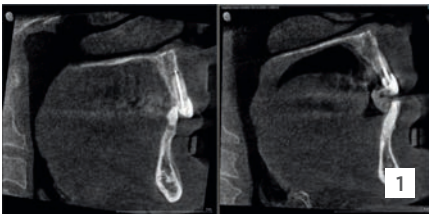
Author Dentist and Oral Surgeon Marcin Wojtunik, Pfronten, Germany

According to the German Sleep Society (DGSM), 9 percent of the German population suffers from sleep apnea. Ear, nose and throat doctors and sleep laboratories usually prescribe a breathing mask in such cases. This can now be replaced by a more pleasant form of therapy. A protrusion splint is intended to help keep the lower jaw in a forward position during sleep. In conjunction with 3D X-ray data, SICAT Air offers dentists a digital workflow to make ordering fast and simple.

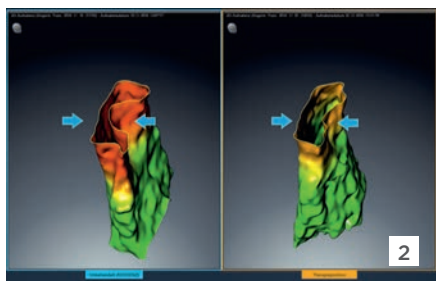
Restful sleep is vital for us as humans. However, every tenth person wakes in the morning feeling stressed. One reason may be sleep apnea – dangerous cessation of breathing during sleep. Sleep apnea is the most common form of sleep-related

disease and can have a serious impact on health: Besides poor concentration, irritability and depression, the lack of oxygen while breathing stops can lead to serious cardiovascular diseases like strokes.

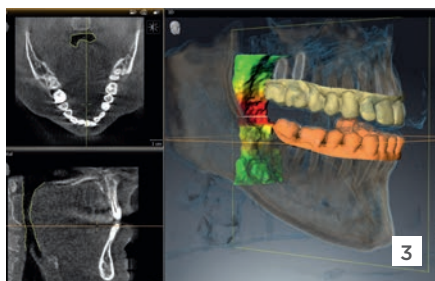
Anatomical circumstances, such as restricted airways or loss of muscle tone in the tongue and throat muscles, are common cause of sleep apnea. They causes blockage of the upper airways during sleep. A frequently occurring symptom of sleep apnea is snoring, but not all snoring is a sign of sleep apnea. Comprehensive diagnostics are indispensable and are usually performed by medical specialists or in the sleep laboratory. A suspected diagnosis can already be made by specialized dentists through screening by outpatient sonography devices. The use of a breathing mask (commonly: Continuous Positive Airway Pressure (CPAP) device) is recommended as a standard treatment. The respiratory masks used are often only accepted by patients to a limited extent to a limited extent. With SICAT Air, dentists have a more pleasant form of therapy at their disposal: With the help of a protrusion splint, the lower jaw can be shifted forward thus creating space in the throat and preventing



1 Comparison of the airways created with Orthophos SL Low Dose using the Compare function.

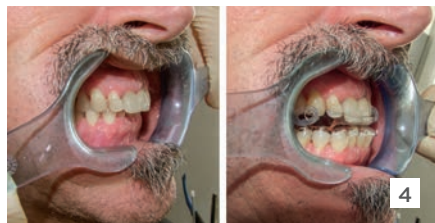

2 Analysis of the Orthophos SL Low Dose images before and after use of the construction bite.



3 Orthophos SL Low Dose data record (11 cm x 10 cm, 20 µSv) for planning the final splint after the analysis.

4 Jaw position without and with the protrusion splint.



closure of the upper airways. The OPTISLEEP splint can be planned, fabricated and incorporated with SICAT Air in just two sittings. The following case of a 55-year-old male patient with typical symptoms of sleep apnea illustrates the advantages of the digital workflow.

Two low dose images were taken with Orthophos SL to plan the therapy: one image in the untreated state and one in the therapy position with the lower jaw protruding after use of the construction bite. The Compare function clearly shows how the protrusion of the lower jaw brings about expansion of the airways. In the second step, a comparative analysis of the two images is performed with SICAT Air, whereby the airways are segmented. The colored representation of the airway profile allows a better assessment of whether therapy using a protrusion

splint is likely to succeed. If this is the case, the jaw is digitalized by means of an intraoral scan (CEREC) or by scanning the plaster model, and is transferred to SICAT Air. The splint can then be digitally planned and ordered online from Sicat.

Conclusion: The try-in with the patient showed that the OPTISLEEP splint fit perfectly. At the next visit, the patient reported that his well-being had since improved significantly. A subsequent sonographic follow-up revealed a reduction in the relevant respiratory disturbance index (RDI) and in his snoring behavior. He feels more rested and is glad to have accepted the splint therapy.

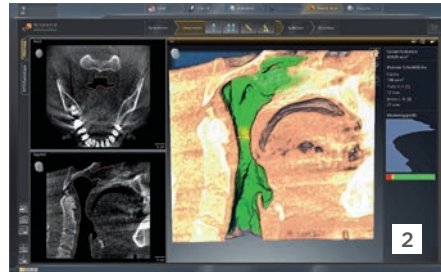
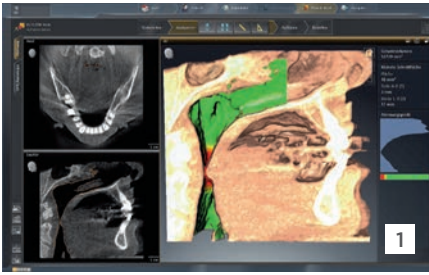
SICAT Air and OPTISLEEP: Successful therapy of obstructive sleep apnea

Author Dentist Guido Pawlik, Berlin, Germany

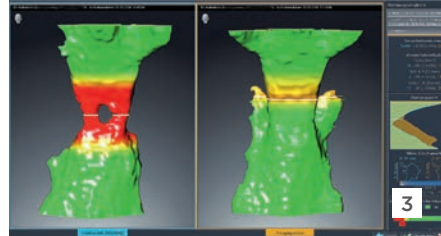
The close link between the cranio-mandibular and musculoskeletal system is now universally recognized. From an overall perspective dentists can therefore assume greater responsibility for a patient's health - to their mutual benefit. Obstructive sleep apnea is a special area for which they can offer their patients new treatment options thanks to groundbreaking technology.

SICAT Air gives dentists the opportunity to include a new, medically highly relevant and economically attractive indication area in their treatment portfolio by using Orthophos SL or Galileos and CEREC. This provides an opportunity to create a unique SICAT Air is able to fully digitize the process from the patient's diagnostic findings through to the manufacturing of a splint which can be made available to the patient within two sessions. The following case illustrates the possibility of such a treatment.

A 70 year old patient was afflicted with comprehensive general physical symptoms centering on cardiovascular disorders. The initial findings showed a sunken vertical bite registration with long-term chronic functional disorders, highly increased blood pressure, severe sleep disturbances with snoring and breathing cessation, as well as myofunctional disorder. Following a detailed medical history the first session for analyzing the airways involved a Low Dose mode 3D image being created of the jaw and throat in a natural lower jaw position.



The second session involved a Low Dose mode 3D image being used to determine the optimized mandibular breathing position and and its effect examined with respect to the therapy of the myofunctional airway obstruction. Digital impressions were taken of the maxilla and mandible with CEREC and the data was then overlaid with the X-ray image in the therapeutic bite position in SICAT Air. The data-set could now be used to order the SICAT OPTISLEEP splint.

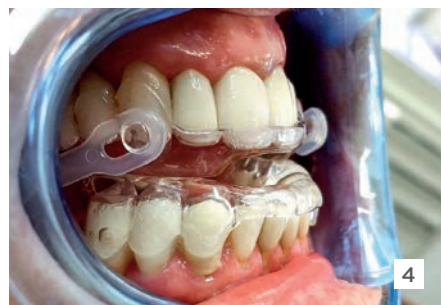


1 Orthophos SL Low Dose images (11 cm x 10 cm, 20 μ Sv) visualize the throat and airways in a habitual ...

2 ... and therapeutic lower jaw position.

3 Comparison of the 3D airways visualization in habitual and therapeutic lower jaw position.

Using SICAT Air it is realizable to manufacture chairside a patient-individualized splint within two sessions. The mandibular advancement splint thus created is a perfect fit, can be worn comfortably compared to a breathing mask and thus improves patient compliance for optimized therapy outcomes. The successful and highly efficient therapy of myofunctional airway obstruction lets us empower dentists so that they can take more responsibility for the overall physical health of our patients.



4 Patient with a SICAT OPTISLEEP mandibular advancement splint.

3D Endo™ Software – Safety Through Planning

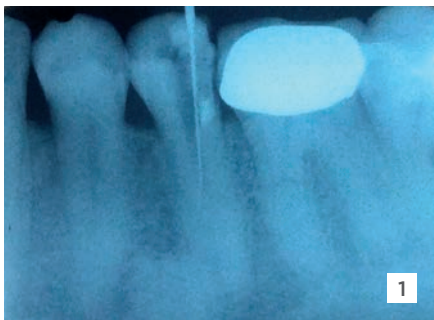
Author Dr. Tomas Lang, Essen, Germany

For over ten years now DVT technology has enabled high fidelity 3D X-ray imaging in dental at a reasonable exposure to radiation. In conjunction with the new endodontics software 3D Endo™ this type of imaging can provide even greater added value in planning root canal treatment. Using the 3D data and visualization in the endodontics software, case-specific requirements for dental root canal treatment can be identified and root canal shapes very well analyzed.

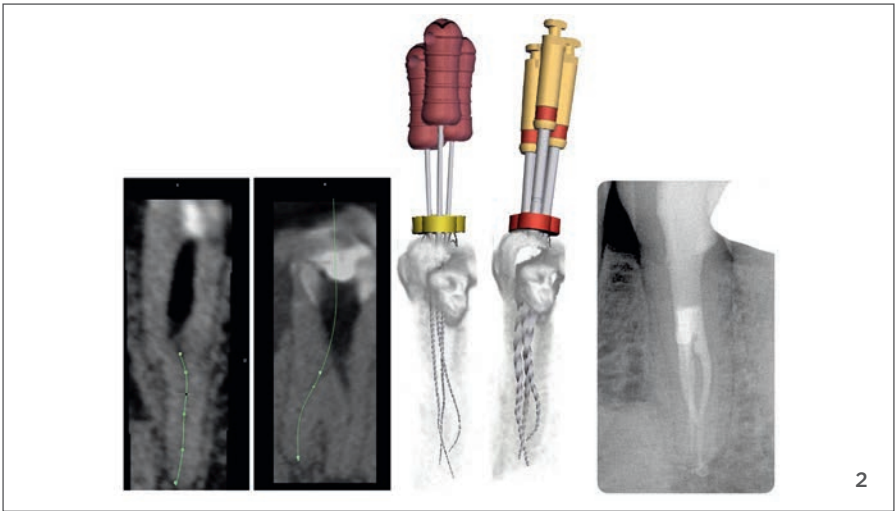
This is exemplified by the case of a 52-year-old patient who was suffering from acute symptoms arising from Caries penetrans. The family dentist removed the caries and started the endodontic treat-

ment. During the treatment, he did not manage to deploy the instrument over the entire working length of the root canal (fig. 1). An intraoral measurement image did not clarify the result, therefore the patient was referred to us. The result has to be analyzed from a different perspective. This was done by preparing an eccentric intraoral image enabling two vestibular root canals to be depicted. The image fueled the suspicion that there would have to be a third additional root canal toward lingual. A focused field of view volume (Orthophos SL, Dentsply Sirona) was prepared for verification.

Initially, the tooth was separated manually in the software to show it without jaw teeth and adjacent teeth. The root canal entrances and the apical foramina are then marked in the axial plane prior to the software automatically seeking the shape of the root canal (fig. 2). This can be adjusted manually. As a help, a unique visualization and layered navigation through the volume is available, perpendicular to the actual course of the root canal. This allows the length and depth of the root canal to be clearly recognized. By placing rasps in the canals, it is possible to check beforehand whether the root is fractured as a



1 Intraoral image from the referring dentist.

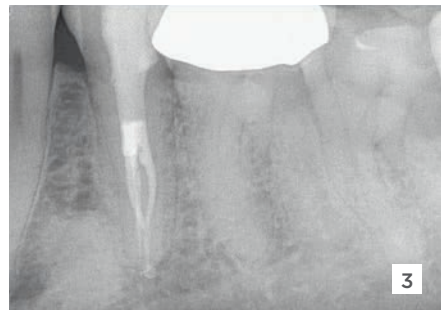

2 Orthophos SL DVT in 3D Endo software and intraoral image following the root canal filling: the displayed three-dimensional case planning helps step by step in virtual simulation and clinical application.

result of the axial expansion of the file during treatment. The selection of the file from the integrated rasp database and the transparent visualization of the tooth substance allow the spatial shape of the instruments to become visible (fig. 3). Any stresses for the instruments are promptly detected. Straight access can be planned and the risk of file fracture minimized. The software even proposes a minimally invasive design and depth of the access cavity. Insight is gained relating to the control image that can be expected after filling the root canal – already before the opening of the Trepanation.

Combining the high-resolution 3D X-ray data from Orthophos SL and the 3D Endo™ software functions enabled a clinically perfect treatment. With the virtual pre-planning,

such complex cases can be resolved in a clinically efficient manner. The result is that a complex case could be resolved in an economic and efficient manner reducing stress on the patient.



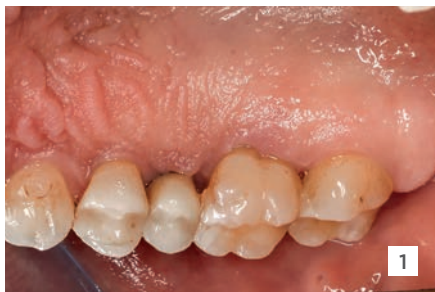3 Intraoral image following the root canal filling matches all the details of the planning.

Optimum restoration in cases of root resorption

Author Dr. Dae-Hyun Lee, Hong Kong

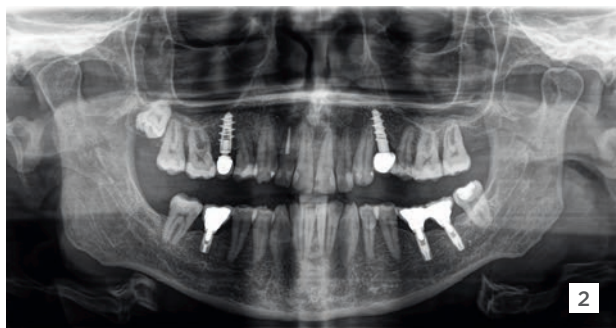In treating periodontal disease it is essential to assess the spread of the disease, particularly if it involves rescuing a tooth or its root. DVT images are a major asset in this.

Assessment of the periodontium by 2D X-ray imaging is challenging especially in multi-rooted teeth. In diagnosing a chronic root resorption which can give rise to a dental nerve inflammation and at worst to necrosis of the nerve, using a DVT offers distinct benefits: The volume permits a unique appraisal of how far the disease has spread. With its high-resolution imaging and efficient metal artifact reduction, Orthophos SL 3D provides generalists and specialized periodontologists with an optimum tool for diagnosis and therapy planning. This is implemented successfully by the possibility of visualizing the defect in slices in the Sidexis 4 software. The case report below will demonstrate how.

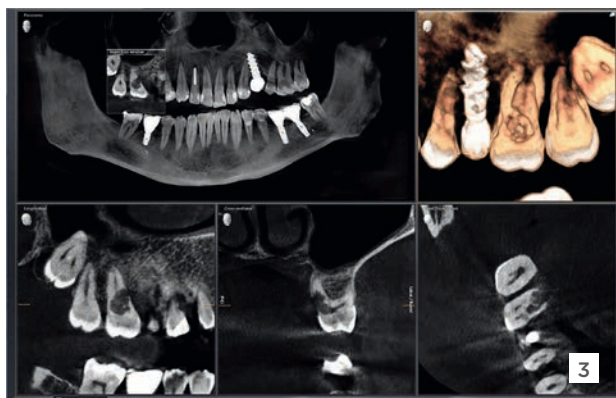


1 There are no visible signs of inflammation or swellings in the palatal area of tooth 16.

A 54-year-old patient came into the practice with a referral from a dentist and requested a periodontal examination. In the initial examination of the patient there were no recognizable signs of inflammation or swelling in the palatal region of tooth 16 (fig. 1). A 2D image made with Orthophos SL showed the presence of four implants which were placed over 20 years ago (fig. 2). As the interradicular extension of the resorptive defect at the palatal root and the prognosis for preserving tooth 16 was unclear, a 3D image of



2 Panorama image of the full jaw.



3 Orthophos SL DVT provides a good basis for a clear diagnosis.

the jaw was made in HD mode. The "Creative Interactive Clipping Pane" analytical tool was used for planning the further therapy. This involved planning the removal of the palatal root using a 3D aspect and precisely defining the extent of the root resorption prior to the operation. Therefore it was already possible to evaluate and gauge the result of the root resection before the operation.

To prevent the resorption process from progressing, root canal treatment and root resection of the palatal root were performed. The root was then filled with glass-ionomer. Thanks to the comprehensive therapy planning, the treat-

ment proceeded without any trouble. For further treatment the patient was sent to a specialist in endodontics for root canal treatment on the mesio-buccal and disto-buccal roots.

Lowest possible radiation exposure in pediatric dentistry: The 3D Low Dose mode

Author PD Dr. Dr. Lutz Ritter, Hennef, Germany

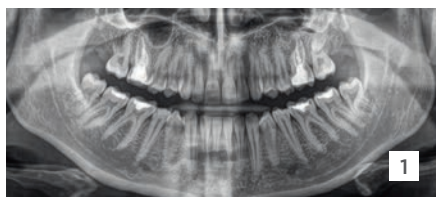
Radiation protection has a key role to play in pediatrics and orthodontics. It is important to keep radiation doses as low as possible for young patients. But to be able to make a precise diagnosis, it is also important to achieve good quality imaging of the symptoms. Orthophos SL 3D's Low Dose mode is therefore an outstanding match for use with children and young persons: Despite its low radiation dose, it delivers radiographic images of a suitable diagnostic quality.

X-ray examinations place particular demands in the case of children and young persons and especially in the orthodontic treatment of children. The imaging systems operate with radiation doses, adjusted to generate high-quality images for clear diagnosis and effective treatment planning in adults. Such a dose can often be too high for children as they are more susceptible to radiation-induced cancers. Therefore global guidelines ensure special radiation protection in pediatric radiology. Adhering to these guidelines and creating high-quality images is a major challenge, which can be ameliorated in two ways: restricting the volume size, and limi-

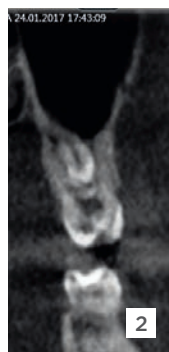ting the radiation exposure. Orthophos SL 3D makes both possible: It can be used optionally with volumes measuring 8 cm x 8 cm, 11 cm x 10 cm or 5 cm x 5.5 cm. In addition, the Low Dose mode enables, for example, the arrangement and the precise position of teeth to be imaged; which can lower the radiation level by up to 85 percent in comparison with conventional 3D images. The image quality and various application options required for each indication are thus easily combined, as shown in the example below.

A young patient presented to the practice with lower jaw symptoms which – as it turned out – originated from difficult dentition (Dentitio difficilis) affecting tooth 38. To prepare the X-ray findings, an initial panorama image was made using the 2D mode of the 2D/3D hybrid X-ray system Orthophos SL, which showed the Canalis mandibularis covering the root (fig. 1). There was also an incidental finding: Tooth 28 was displaced - with ambiguous resorption of the roots of teeth 38 and 48 with the mandibular canal. There was also a suspected inflammation of the root tip (apical osteitis) at tooth 26.

To produce unambiguous diagnoses, we made a DTV in the Low



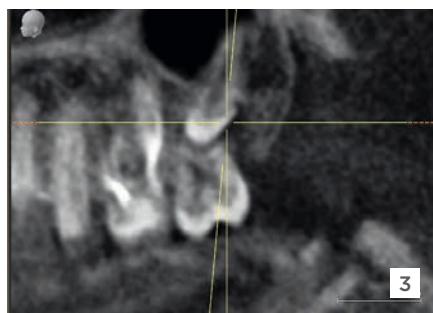
1 The generated panorama image shows the displacement of tooth 28.



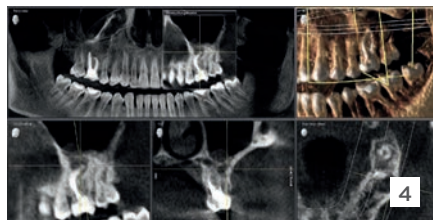
2 According to the transversal slice image (TSI) of the Low Dose scan the displaced tooth 28 shows no signs of its roots being resorbed.

Dose mode of Orthophos SL. Different volumetric images generated from the volume were able to reveal the interradicular position of tooth 28 without any sign of the roots of tooth 27 being resorbed (fig. 2), and also signs of bone loss (osteolysis) distally from tooth 27 (fig. 3). In addition, it was shown which of the three roots of tooth 26 was infected: the strongly curved mesial root of 26 (fig. 4). The positional relationship of tooth 38 to the mandibular canal could be unambiguously imaged by using differing perspectives.

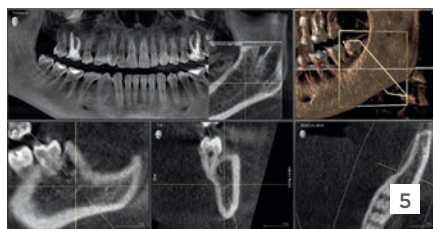
Result: Even at a reduced dose, the image is of suitable quality to show the precise position of displaced teeth and their positional relationship to other anatomical structures thereby enabling a therapy plan to be worked out. 3D imaging of tooth 26 thus made it possible to clearly establish that treatment was required and also which root was affected. The full diagnosis meant a gain in terms of safety for the clinician and improved patient communication because the patient could be briefed about potential risks more meaningfully and precisely while better demonstrating the therapy proposal.



3 The first signs of osteolysis are recognizable.



4 The image confirms the suspicion of apical osteitis of the mesial root.



5 Positional relationship of tooth 38 to the mandibular canal.

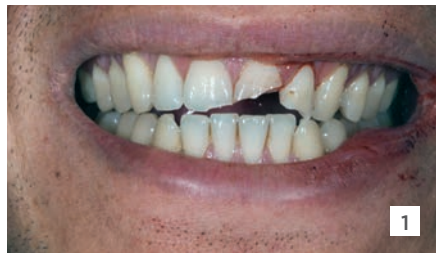Confident decision-making in treating dental traumas

Authors Dr. Kaveer Ratan and Dr. Clifford Yudelman, Sea Point near Cape Town, South Africa

In the day-to-day work routines of practicing dentists, dental traumas – as gauged against other daily activity – are a rather rare indication which often impose their own special challenges. Thanks to its flexibility Orthophos SL supports safe and minimally invasive diagnostics providing an optimum basis for planning therapy.

Dental traumas create demanding challenges upon clinicians: Every case is different and there is rarely a current protocol at hand which can assist as to when and how reconstruction, repositioning and replantation should take place. In decision-making, DVT images are particularly helpful as they provide a second plane of reference in treating dental traumas. For example, risks to adjacent structures, potentially caused by the trauma, can be illustrated. Orthophos SL also offers the possibility of generating different views of the different slices in order to be able to make an informed decision, as illustrated in the following case.

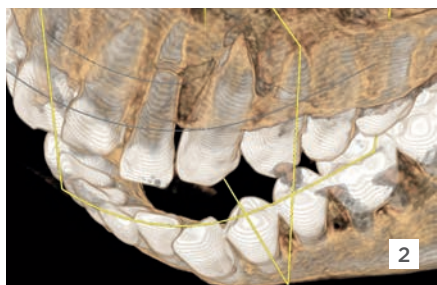After an accident the 31 year old patient came into the practice as an emergency, exhibiting the following



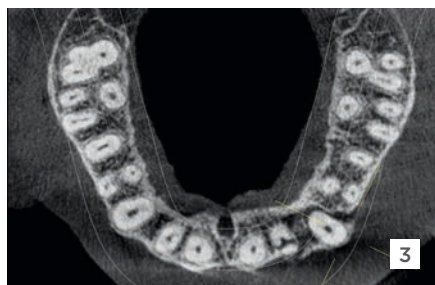1 Dental trauma to the patient after a surfing accident.

visible injuries: lesions to the lower and upper lip mucosa, minor splintering of the incisal edge of tooth 11, crown fracture and resultant exposure of the pulp of tooth 21, loosening of teeth 22 and 23, and also an edema in the second quadrant's buccal vestibulum.

A DVT was made with the Orthophos SL in the first session in order to check the injuries in the jaw. It showed that tooth 22 had suffered a vertical fracture extending from the middle down to the apical root of tooth 22. Canine 23 showed a lateral luxation injury causing the incisal edge to be slightly displaced towards palatal. A fracture of the buccal bone plate in regions 22 and 23 was also revealed, showing the top edge no longer to be in contact with the alveolar bone. During the



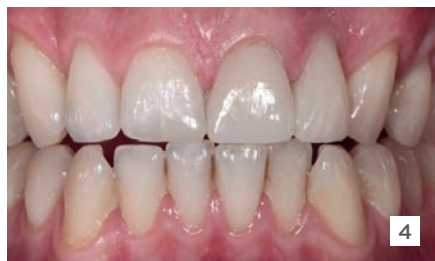2 Diagnostic findings in the first DVT.



3 The Orthophos SL slice image very clearly shows the fracture of tooth 22 and the displacement of tooth 23.

first session, the injuries to the lip were sutured. Additionally the root canals of teeth 21 and 23 were treated and tooth 11 was temporarily restored. After the root treatment, tooth 21 was also reconstructed while we took out tooth 22 in two pieces. The patient's crown was then used to make a pontic while a fiber-reinforced splint was placed from tooth 21 to 24. The patient then wore it for six weeks. In the second session, a second DVT was made in order to identify the extent to which bone healing had progressed along the fracture. The splint was then removed and tooth 21 was prepared for a dual-pontic free-end bridge. The tooth situation was scanned with the CEREC Omnicam. The data were sent to our lab technician Shane Hanson at Di-Ceram laboratory, where CAD/CAM was used in preparing a milled and manually veneered bridge. This was then fitted into the patient one week later as a long-term temporary restoration, while Shane fabricated the final bridge using e.max.

Result: All things considered, treatment of a dental trauma is simplified by Orthophos SL's image quality. Furthermore, the 3D data during therapy planning gives greater confidence in decision-making. The images showed that the current status of the dental trauma prevented the possibility of implantation. In this case, implant treatment was not carried out at this time, as it was not financially viable for the patient. But nevertheless he needed a good aesthetic result prior to travelling overseas. Which is why a conservative approach was taken and the decision was made to use a free-end bridge.



4 Thanks to a clear diagnosis it was possible to restore the maxilla.

Connectivity is now

Author Jörg Haist, Head of Product Management Imaging Systems, Bensheim

Until just a few years ago dentists based their investment decisions on just one device. That was certainly understandable because the questions of whether they should, for example, pursue computer-aided restorative dentistry or try implantology had no bearing. This is now all fundamentally different: New findings and new technologies in medicine and dentistry have strengthened the outlook for interdependencies between individual disciplines and have therefore also made completely new treatment approaches possible.

The requirement for this is that the various technologies are perfectly matched and can intercommunicate. This is now possible thanks to digitization, provided that software and hardware developers consider the bigger picture and understand where there are points of contact between particular fields and systems and then link them via innovative solutions - meaning „connectivity“. More than virtually any other company, Dentsply Sirona is in a position here to offer cross-platform solutions because the company has spent decades in the vanguard of almost all subsectors of dentistry. Through the merger of Dentsply and Sirona know-how in dentistry and dental technology

has become even more expansive. It has created the possibility to fuse leading systems, technologies and consumables into integrated workflows. The result is solutions which are thought through all the way from diagnosis determination to the final restoration. This is special because integrated, complete solutions provide more comfort, reliability, and time and cost saving for clinicians and patients in everyday practice. Clinicians can plan their work more flexibly and thus produce better results.

Imaging systems are now already being used successfully for treatments in implantology, orthodontics, surgery, endodontics, as well as in restorative dentistry and in treating obstructive sleep apnea. The indications that are candidates for treatment based chiefly on three-dimensional imaging are becoming ever more numerous and extensive. Dentists are often deciding not on whether to use integrated digital methods, rather on which ones. The choices then are subject to the treatment type, individual knowledge and preference, patients' wishes, and timeframe and cost. As a global leader in innovation, with an international team of over 600 developers and engineers, Dentsply Sirona continues to push

this trend towards connectivity and ensures that more and more sectors of dentistry benefit from the advantages of 3D imaging in conjunction with other digital technologies.

Publisher

Dentsply Sirona
Sirona Straße 1
A-5071 Wals/Salzburg (Austria)
E-Mail: contact@dentsplysirona.com
Telefon: +43 (0) 662 24 50-0
Telefax: +43 (0) 662 24 50-510
www.dentsplysirona.com

Responsible under german press law

Vincent Kummer, Marion Par-Weixlberger,
Dentsply Sirona, in Wals/Salzburg
(Austria)

Editorial and design

Edelman.ergo GmbH
Agrippinawerft 28
D-50678 Köln
www.edelmanergo.com

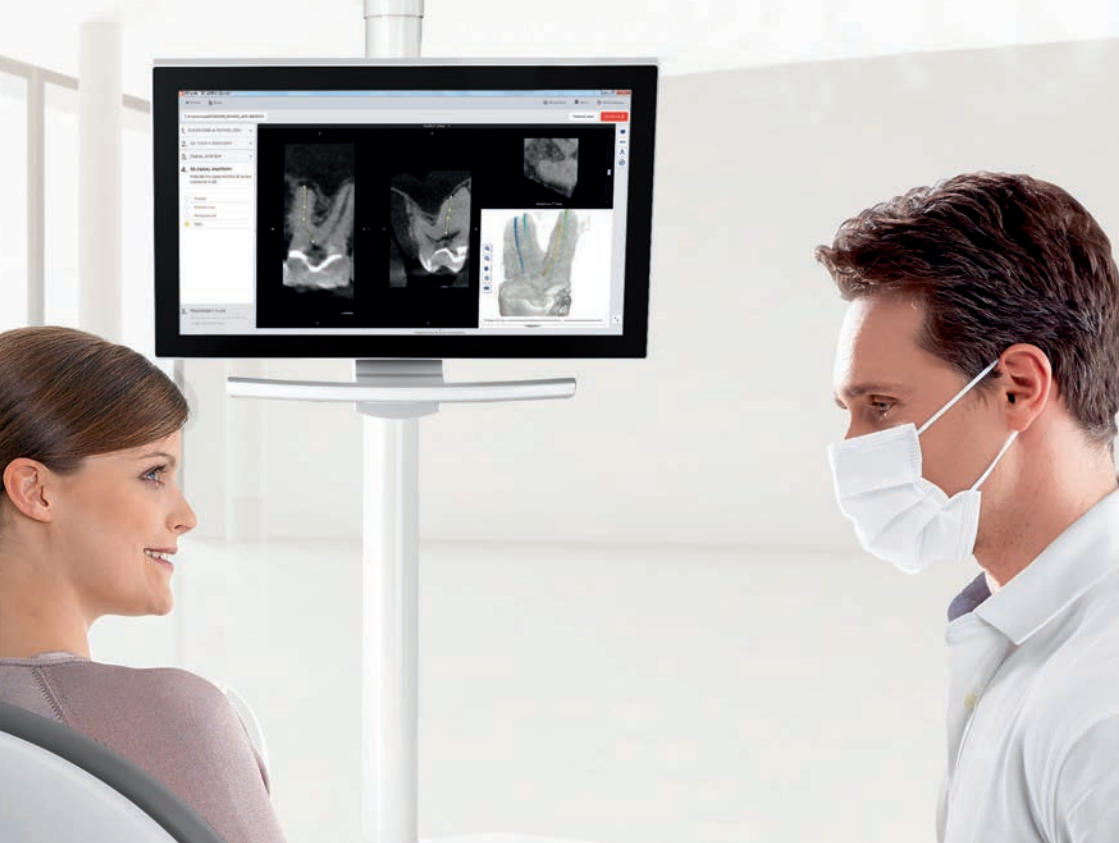Special thanks also to:

Dr. Gerd Frahsek, Dr. Dr. Dieter Hültenschmidt,
Dr. Dae-Hyun Lee, Dr. Tomas Lang, Dr. Björn
Ludwig, Carolin Müller, FZA Guido Pawlik,
Dr. Kaveer Ratan, PD Dr. Dr. Lutz Ritter,
Dr. Clifford Yudelman, FZA Marcin Wojtunik

Printing

schmitz druck & medien GmbH & Co. KG
Weihersfeld 41
D-41379 Brüggen
Telefon: +49 (0) 2163 95093-0

We reserve the right to make technical
modifications, typographical errors
and mistakes.



Complex cases, nothing left to hide?

The first CBCT based software designed to improve endodontic treatment planning for more predictability.

3D Endo™
Software

A91100-M47-C073-01-7600

THE DENTAL
SOLUTIONS
COMPANY™

 Dentsply
Sirona