

Xive[®] implant system – Clinical documentation

The Xive implant system is designed with flexibility and user-friendliness in mind. An intuitive surgical and prosthetic workflow coupled with a complete range of prefabricated and patient specific components gives a system that remains a faithful companion for both the first-time user and the expert.

Well documented, reliable and safe

- Long-term documentation with up to 15 years of follow-up¹⁻¹⁶
- 98% implant survival rate at 10 years²⁻⁷
- Long-term prospective studies show predictable results for immediate loading⁶⁻⁹

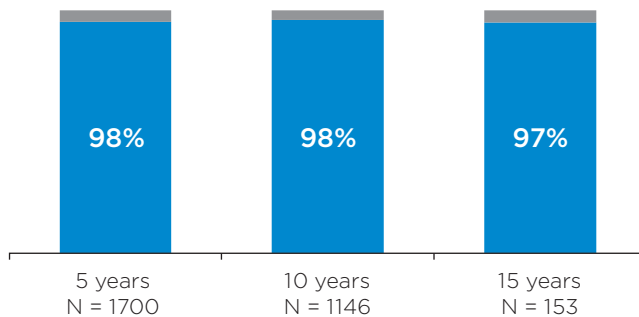


Fig. 1 Implant survival compiled from 15 long-term studies that report on survival²⁻¹⁶. N is the number of implants entering the studies and survival is measured on implant level.

A versatile and intuitive system with good primary stability

Three prominent features behind the clinical success:

- Friadent Plus surface gives early osseointegration^{17, 18}
- Platform switch supports preservation of bone levels^{19, 20}
- ActiveBoneControl™, designed for high primary stability

In multiple studies immediate loading of the Xive implant system shows predictable results^{6-9, 21-36}, which is supported by the fact that the Xive implant is routinely placed with good primary stability^{35, 37, 38}.

Studies indicate that treatment with Xive implants is safe and predictable for a variety of indications such as: single-tooth restorations^{32-34, 39-45}, overdentures^{10, 11, 29} and fixed full/partial restorations^{22-28, 46-48} also with angulated implant placement^{26, 48}. There is also support for placement in extraction sockets^{34, 35, 38-41, 49, 50} as well as grafted sites^{34, 39, 42, 50-54} including grafted sites in oncology patients^{55, 56}.

In narrow spaces, Xive 3.0 implants (Ø 3.0 mm), show good primary stability and predictable clinical outcome^{4, 10, 28, 32, 33, 38}.

Conclusion

Studies following more than 5000 implants in 2800 patients for up to 15 years show that the Xive implant system offers safe and predictable treatment outcomes with high implant survival rates in all loading situations.

To read more Scientific Reviews please see:
www.dentsplysirona.com/implants/science

References

1. Keeve PL, Khoury F. Long-term results of peri-implant conditions in periodontally compromised patients following lateral bone augmentation. *Int J Oral Maxillofac Implants* 2017;32(1):137-46. [Abstract in PubMed](#)
2. Garlini GC, V. D'Amato S, Marco Redemagni. A long term follow-up of single-tooth Xive implant: 15 year results. *Dental, Oral and Craniofacial Research* 2016;3(1). [Abstract in PubMed](#)
3. Konstantinidis IK, Siompaas KD, Kotsiotou-Siormpa E, et al. Long-Term Esthetic Evaluation of the Roll Flap Technique in the Implant Rehabilitation of Patients with Agenesis of Maxillary Lateral Incisors: 10-Year Follow-Up. *Int J Oral Maxillofac Implants* 2016;31(4):820-6. [Abstract in PubMed](#)
4. Arisan V, Bolukbasi N, Ersanli S, et al. Evaluation of 316 narrow diameter implants followed for 5-10 years: a clinical and radiographic retrospective study. *Clin Oral Implants Res* 2010;21(3):296-307. [Abstract in PubMed](#)
5. Khoury F, Keller P, Keeve PL. Stability of Grafted Implant Placement Sites After Sinus Floor Elevation Using a Layering Technique: 10-Year Clinical and Radiographic Results. *Int J Oral Maxillofac Implants* 2017;32(5):1086-96. [Abstract in PubMed](#)
6. Degidi M, Nardi D, Piattelli A. 10-year prospective cohort follow-up of immediately restored XIVE implants. *Clin Oral Implants Res* 2016;27(6):694-700. [Abstract in PubMed](#)
7. Heschl A, Payer M, Platzer S, et al. Immediate rehabilitation of the edentulous mandible with screw type implants: results after up to 10 years of clinical function. *Clin Oral Implants Res* 2012;23(10):1217-23. [Abstract in PubMed](#)
8. Degidi M, Nardi D, Piattelli A. A six-year follow-up of full-arch immediate restorations fabricated with an intraoral welding technique. *Implant Dent* 2013;22(3):224-31. [Abstract in PubMed](#)
9. Payer M, Heschl A, Wimmer G, et al. Immediate provisional restoration of screw-type implants in the posterior mandible: results after 5 years of clinical function. *Clin Oral Implants Res* 2010;21(8):815-21. [Abstract in PubMed](#)
10. Geckili O, Mumcu E, Bilhan H. Radiographic evaluation of narrow diameter implants after 5 years of clinical function: a retrospective study. *J Oral Implantol* 2013;39(5):273-79. [Abstract in PubMed](#)
11. Heschl A, Payer M, Clar V, et al. Overdentures in the edentulous mandible supported by implants and retained by a Dolder bar: a 5-year prospective study. *Clin Implant Dent Relat Res* 2013;15(4):589-99. [Abstract in PubMed](#)
12. Merli M, Moscatelli M, Mariotti G, et al. Bone level variation after vertical ridge augmentation: resorbable barriers versus titanium-reinforced barriers. A 6-year double-blind randomized clinical trial. *Int J Oral Maxillofac Implants* 2014;29(4):905-13. [Abstract in PubMed](#)
13. Moeintaghavi A, Radvar M, Arab H, et al. Evaluation of 3- to 8-year treatment outcomes and success rates with six implant brands in partially edentulous patients. *J Oral Implantol* 2012;38(s1):441-48. [Abstract in PubMed](#)
14. Chrcanovic BR, Kisch J, Albrektsson T, et al. Factors influencing the fracture of dental implants. *Clin Implant Dent Relat Res* 2017;E-pub Dec 6, doi: 10.1111/cid.12572. [Abstract in PubMed](#)
15. Gjelvold B, Chrcanovic BR, Bagewitz IC, et al. Esthetic and Patient-Centered Outcomes of Single Implants: A Retrospective Study. *Int J Oral Maxillofac Implants* 2017;32(5):1065-73. [Abstract in PubMed](#)
16. Wu S, Wu X, Shrestha R, et al. Clinical and Radiologic Outcomes of Submerged and Nonsubmerged Bone-Level Implants with Internal Hexagonal Connections in Immediate Implantation: A 5-Year Retrospective Study. *J Prosthodont* 2017;E-pub Nov 16, doi: 10.1111/jopr.12647. [Abstract in PubMed](#)
17. Degidi M, Scarano A, Iezzi G, et al. Histologic analysis of an immediately loaded implant retrieved after 2 months. *J Oral Implantol* 2005;31(5):247-54. [Abstract in PubMed](#)
18. Iezzi G, Degidi M, Scarano A, et al. Bone response to submerged, unloaded implants inserted in poor bone sites: a histological and histomorphometrical study of 8 titanium implants retrieved from man. *J Oral Implantol* 2005;31(5):225-33. [Abstract in PubMed](#)
19. Ismaïel MD, Elhadry AA. Influence of platform switching concept on marginal bone alteration around dental implant. *J Am Sci* 2012;8(11):546-52. [Abstract in PubMed](#)
20. Zarandi A, Novin M. Marginal bone loss around platform-switched and non-platform switched implants after two years of placement: A clinical trial. *J Dent Res Dent Clin Dent Prospects* 2017;11(1):26-29. [Abstract in PubMed](#)
21. Degidi M, Nardi D, Piattelli A. Immediate rehabilitation of the edentulous mandible with a definitive prosthesis supported by an intraorally welded titanium bar. *Int J Oral Maxillofac Implants* 2009;24(2):342-7. [Abstract in PubMed](#)
22. Degidi M, Nardi D, Piattelli A. A comparison between immediate loading and immediate restoration in cases of partial posterior mandibular edentulism: a 3-year randomized clinical trial. *Clin Oral Implants Res* 2010;21(7):682-87. [Abstract in PubMed](#)
23. Degidi M, Nardi D, Piattelli A. Immediate loading of the edentulous maxilla with a final restoration supported by an intraorally welded titanium bar: a case series of 20 consecutive cases. *J Periodontol* 2008;79(11):2207-13. [Abstract in PubMed](#)
24. Degidi M, Daprile G, Piattelli A. Implants inserted with low insertion torque values for intraoral welded full-arch prosthesis: 1-year follow-up. *Clin Implant Dent Relat Res* 2012;14(Supplement 1):e39-45. [Abstract in PubMed](#)
25. Degidi M, Nardi D, Piattelli A. Immediate definitive rehabilitation of the edentulous patient using an intraorally welded titanium framework: a 3-year prospective study. *Quintessence Int* 2010;41(8):651-9. [Abstract in PubMed](#)
26. Degidi M, Nardi D, Piattelli A. Immediate loading of the edentulous maxilla with a definitive restoration supported by an intraorally welded titanium bar and tilted implants. *Int J Oral Maxillofac Implants* 2010;25(6):1175-82. [Abstract in PubMed](#)
27. Degidi M, Nardi D, Piattelli A, et al. Immediate loading of zygomatic implants using the intraoral welding technique: a 12-month case series. *Int J Periodontics Restorative Dent* 2012;32(5):e154-61. [Abstract in PubMed](#)
28. Degidi M, Nardi D, Piattelli A. Immediate restoration of small-diameter implants in cases of partial posterior edentulism: a 4-year case series. *J Periodontol* 2009;80(6):1006-12. [Abstract in PubMed](#)
29. Degidi M, Piattelli A. Comparative analysis study of 702 dental implants subjected to immediate functional loading and immediate nonfunctional loading to traditional healing periods with a follow-up of up to 24 months. *Int J Oral Maxillofac Implants* 2005;20(1):99-107. [Abstract in PubMed](#)
30. Degidi M, Piattelli A, Carinci F. Parallel screw cylinder implants: comparative analysis between immediate loading and two-stage healing of 1,005 dental implants with a 2-year follow up. *Clin Implant Dent Relat Res* 2006;8(3):151-60. [Abstract in PubMed](#)
31. Degidi M, Piattelli A, Gehrke P, et al. Clinical outcome of 802 immediately loaded 2-stage submerged implants with a new grit-blasted and acid-etched surface: 12-month follow-up. *Int J Oral Maxillofac Implants* 2006;21(5):763-8. [Abstract in PubMed](#)
32. Degidi M, Nardi D, Piattelli A. Immediate versus one-stage restoration of small-diameter implants for a single missing maxillary lateral incisor: a 3-year randomized clinical trial. *J Periodontol* 2009;80(9):1393-8. [Abstract in PubMed](#)
33. Oyama K, Kan JY, Rungcharassaeng K, et al. Immediate provisionalization of 3.0-mm-diameter implants replacing single missing maxillary and mandibular incisors: 1-year prospective study. *Int J Oral Maxillofac Implants* 2012;27(1):173-80. [Abstract in PubMed](#)
34. Redemagni M, Cremonesi S, Garlini G, et al. Soft tissue stability with immediate implants and concave abutments. *Eur J Esthet Dent* 2009;4(4):328-37. [Abstract in PubMed](#)
35. Degidi M, Daprile G, Piattelli A, et al. Evaluation of factors influencing resonance frequency analysis values, at insertion surgery, of implants placed in sinus-augmented and nongrafted sites. *Clin Implant Dent Relat Res* 2007;9(3):144-9. [Abstract in PubMed](#)
36. Vogl S, Stopper M, Hof M, et al. Immediate occlusal versus non-occlusal loading of implants: A randomized clinical pilot study. *Clin Implant Dent Relat Res* 2015;17(3):589-97. [Abstract in PubMed](#)
37. Degidi M, Daprile G, Piattelli A. Determination of primary stability: a comparison of the surgeon's perception and objective measurements. *Int J Oral Maxillofac Implants* 2010;25(3):558-61. [Abstract in PubMed](#)
38. Degidi M, Daprile G, Piattelli A. Primary stability determination by means of insertion torque and RFA in a sample of 4,135 implants. *Clin Implant Dent Relat Res* 2012;14(4):501-07. [Abstract in PubMed](#)
39. Degidi M, Daprile G, Piattelli A. RFA values of implants placed in sinus grafted and nongrafted sites after 6 and 12 months. *Clin Implant Dent Relat Res* 2009;11(3):178-82. [Abstract in PubMed](#)
40. Degidi M, Nardi D, Piattelli A. Peri-implant tissue and radiographic bone levels in the immediately restored single-tooth implant: a retrospective analysis. *J Periodontol* 2008;79(2):252-9. [Abstract in PubMed](#)
41. Degidi M, Novaes AB, Jr, Nardi D, et al. Outcome analysis of immediately placed, immediately restored implants in the esthetic area: the clinical relevance of different interimplant distances. *J Periodontol* 2008;79(6):1056-61. [Abstract in PubMed](#)
42. Merli M, Lombardini F, Esposito M. Vertical ridge augmentation with autogenous bone grafts 3 years after loading: resorbable barriers versus titanium-reinforced barriers. A randomized controlled clinical trial. *Int J Oral Maxillofac Implants* 2010;25(4):801-7. [Abstract in PubMed](#)
43. Nothdurft F, Pospiech P. Prefabricated zirconium dioxide implant abutments for single-tooth replacement in the posterior region: evaluation of peri-implant tissues and superstructures after 12 months of function. *Clin Oral Implants Res* 2010;21(8):857-65. [Abstract in PubMed](#)
44. Nothdurft FP, Nonhoff J, Pospiech PR. Pre-fabricated zirconium dioxide implant abutments for single-tooth replacement in the posterior region: success and failure after 3 years of function. *Acta Odontol Scand* 2014;72(5):392-400. [Abstract in PubMed](#)
45. Payer M, Kirmeier R, Jakse N, et al. Immediate provisional restoration of XIVE screw-type implants in the posterior mandible. *Clin Oral Implants Res* 2008;19(2):160-5. [Abstract in PubMed](#)
46. Turk AG, Ulusoy M, Toksavul S, et al. Marginal bone loss of two implant systems with three different superstructure materials: a randomised clinical trial. *J Oral Rehabil* 2013;40(6):457-63. [Abstract in PubMed](#)
47. Tunkel J, de Stavola L, Khoury F. Changes in soft tissue dimensions following three different techniques of stage-two surgery: a case series report. *Int J Periodontics Restorative Dent* 2013;33(4):411-8. [Abstract in PubMed](#)
48. Tabrizi R, Pourdanesh F, Zare S, et al. Do angulated implants increase the amount of bone loss around implants in the anterior maxilla? *J Oral Maxillofac Surg* 2013;71(2):272-7. [Abstract in PubMed](#)
49. Bilhan H, Mumcu E, Geckili O, et al. The evaluation of the success of immediately placed single implants: a retrospective clinical study. *Implant Dent* 2011;20(3):215-25. [Abstract in PubMed](#)
50. Viswambaram M, Arora V, Tripathi RC, et al. Clinical evaluation of immediate implants using different types of bone augmentation materials. *Med J Armed Forces India* 2014;70(2):154-62. [Abstract in PubMed](#)
51. Cortes AR, Cortes DN, Arita ES. Correction of buccal dehiscence at the time of implant placement without barrier membranes: a retrospective cone beam computed tomographic study. *Int J Oral Maxillofac Implants* 2013;28(6):1564-9. [Abstract in PubMed](#)
52. De Stavola L, Tunkel J. A new approach to maintenance of regenerated autogenous bone volume: delayed relining with xenograft and resorbable membrane. *Int J Oral Maxillofac Implants* 2013;28(4):1062-7. [Abstract in PubMed](#)
53. Restoy-Lozano A, Dominguez-Mompell JL, Infante-Cossio P, et al. Calvarial bone grafting for three-dimensional reconstruction of severe maxillary defects: a case series. *Int J Oral Maxillofac Implants* 2015;30(4):880-90. [Abstract in PubMed](#)
54. De Stavola L, Tunkel J. Results of vertical bone augmentation with autogenous bone block grafts and the tunnel technique: a clinical prospective study of 10 consecutively treated patients. *Int J Periodontics Restorative Dent* 2013;33(5):651-9. [Abstract in PubMed](#)
55. Hessling SA, Wehrhan F, Schmitt CM, et al. Implant-based rehabilitation in oncology patients can be performed with high long-term success. *J Oral Maxillofac Surg* 2015;73(5):889-96. [Abstract in PubMed](#)
56. Pappalardo M, et al., Long-term outcome of patients with or without osseointegrated implants after resection of mandibular ameloblastoma and reconstruction with vascularized bone graft: functional assessment and quality of life. *Journal of Plastic, Reconstructive & Aesthetic Surgery* 2018;E-pub Mar 18, doi: 10.1016/j.jpra.2018.03.008.

To read more Scientific Reviews please see: www.dentsplysirona.com/implants/science