

An all-rounder with three wavelengths

Efficient treatment with a new diode laser

Author: Dr Talat Qadri, Sweden

One dental laser, three diodes, more than 20 indications

Diode lasers have long been established in dentistry. Thanks in part to their broad indication spectrum, they are considered dental "all-rounders." In the following article, Dr. Talat Qadri (Enköping, Sweden), explains why he is convinced of the diode laser technology. As Doctor in Odontology in Laser and Periodontology, he holds his own clinic and is a lecturer at the Karolinska Institute for Laser Dentistry; therefore, he is very familiar with the technology that has been in use since 1990 for treating periodontitis and peri-implantitis, during surgery, for germ reduction in endodontics, as soft laser therapy and even for treating herpes simplex. Furthermore, Dr. Qadri will talk about the advantages of using the new SIROLaser Blue for patients and users.

In my specialisation—periodontology and peri-implantitis—daily adjuvant use of a diode laser has become an essential tool for treating patients in a contemporary manner. Even though applications could be replaced by conventional dental treatments, the use of laser therapy ensures the following can mostly be conducted:

- Faster healing after surgery and extraction.
- Less pain for patients but simultaneously less need for anaesthesia.
- Generally no need for sutures following surgery.
- Swelling and the post-operative intake of analgesics are rare.

Having actively followed the development of this technology for almost 30 years, I have an abundance of experience in the use of dental lasers. Diode lasers have proved particularly successful in dentistry because they cover the widest treatment spectrum and

Figs. 1a & b: The clinical situation and dental X-ray show, amongst others, the remains of the root of tooth 12.

Fig. 2: The clinical situation following extraction of the root remains of tooth 12 prior to treatment with the SIROLaser Blue.

Figs. 3 & 4: The clinical situation after use of the SIROLaser Blue (Fig. 5) with the red diode, wavelength: 660 nm, 8 mm probe/6J Lasing was conducted at 2J buccally and lingually in contact mode, occlusal at a distance of approx. 0.5 cm at 100 mW with an 8 mm probe for 20 seconds on each side.

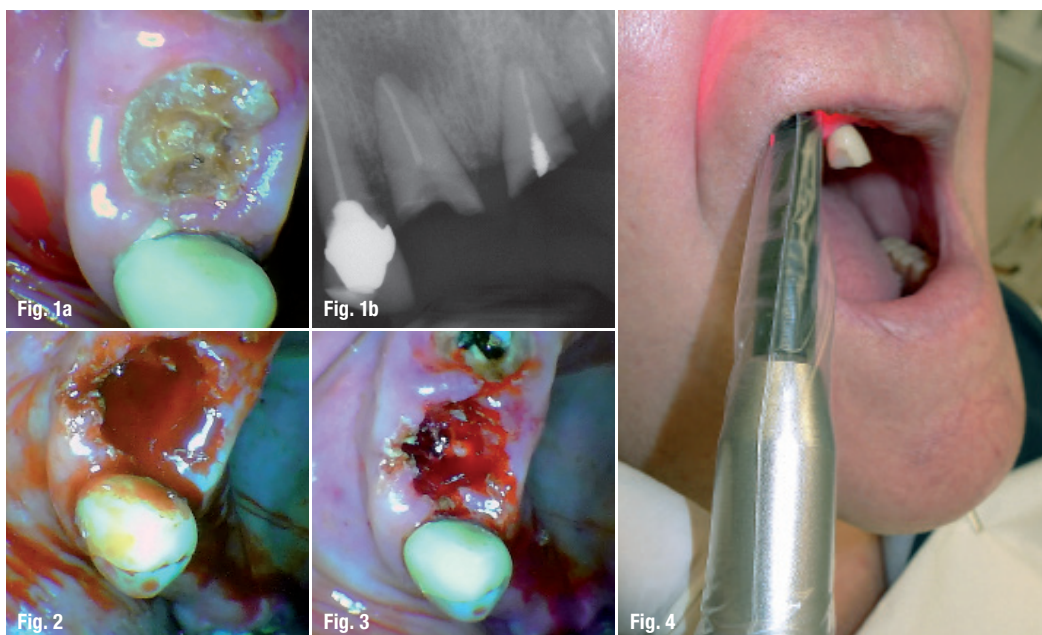

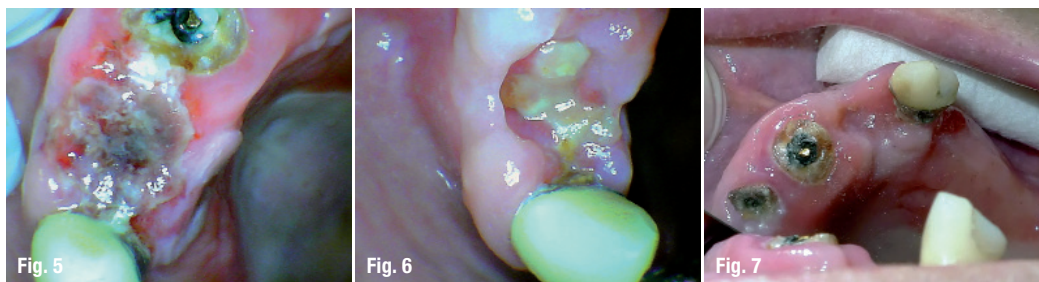


Fig. 5: The clinical situation following LLLT around the extracted tooth 12 after one day.

Fig. 6: The clinical situation of tooth 12 one week after surgery.

Fig. 7: The clinical situation of tooth 12 three weeks after surgery.

have the aforementioned advantages. In the meantime, we now have convincing long-term studies for diode lasers as well as numerous scientific studies that have shown positive results. Diode lasers are suitable for all patients, including those fitted with heart pacemakers (in contrast to electrosurgery). Additionally, patients can avoid being unnecessarily anaesthetised. The lasers are also extremely cost-effective and long lasting.

The advantages of the new three-diode laser

The SIROLaser Blue (made by Dentsply Sirona) is a third-generation laser and the world's first dental laser equipped with a blue (445 nm), infrared (970 nm) and red (660 nm) diode. In my view, combining three wavelengths in a single device that now only weighs a little more than 1 kg makes the new model user friendly. According to the manufacturer, it is suitable for 20 medical indications, and in terms of the treatment provided at my clinic, that includes primarily periodontitis, peri-implantitis, dentine hypersensitivity, herpes infection, endodontics, minimal-invasive laser surgery, the treatment of abscesses, for haemostasis and for gingivectomy. One practical feature is that the device can be programmed individually, although even the factory default settings save time and effort.

In my clinic, we mostly use red laser light (660 nm), as part of soft laser applications like low-level laser therapy (LLLT) and biostimulation. I use the infrared light (980 nm) for reducing germs in periodontology and endodontics. The blue 445 nm diode is used for incisions and advanced laser surgery. Every week I treat about 30 patients for periodontitis or peri-implantitis. Therefore, we prefer using curettage and de-epithelialisation. During surgery, I use the wavelengths 445 nm and 980 nm. To help wounds heal more quickly, I then follow up with the red laser light (660 nm) again.

Safe and precise contact-free incisions

Because blue light is absorbed much better by perfused soft tissue, the new 445 nm blue laser can also make better incisions at lower power than the infrared

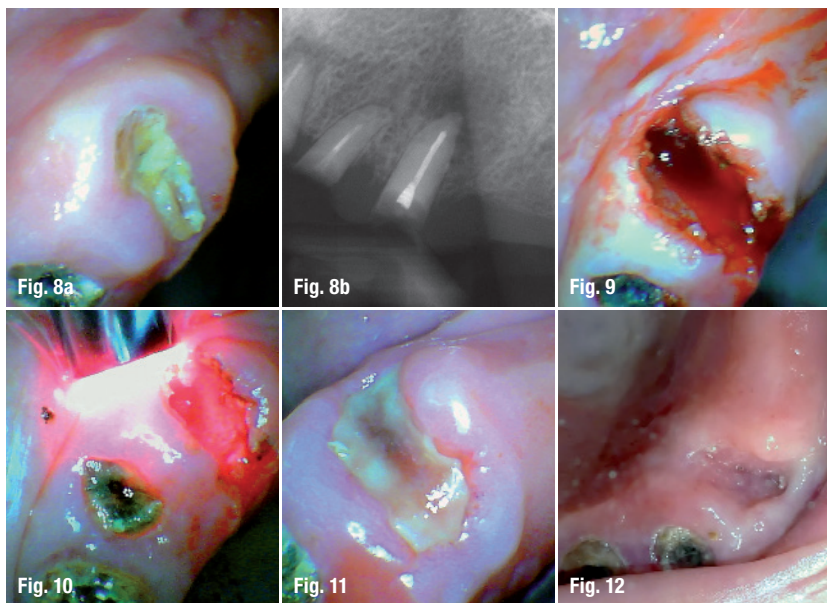
laser light. Non-contact incision is particularly practical because it means no coagulation at the instrument tip, more precise incisions and less bleeding. That makes it ideal for frenulum operations, for example. I also use the blue laser light for faster reliable light-curing of composites. In my opinion, the diode laser provides everything you need for the treatment of soft tissues and much more. A good example is the effective germ reduction in root canals. The diode laser provides more limited treatment opportunities when working with hard tissues such as bones and teeth. However, other types of lasers are available for this purpose.

Remarkable results: red light with low power

The red 660 nm diode is used for what are known as soft-laser applications (LLLT and biostimulation). When the wavelength is absorbed in the mitochondria and cytoplasm, a chemical reaction occurs. Therefore, the biological effect of low-level visible light therapy happens through photochemistry (probably by the photo activation of enzymes). This chemical reaction leads to biostimulation. Abergel et al. (1984) found that the irradiation of fibroblasts in culture at 633 nm stimulated the synthesis of collagen, which helps close the wound and prevent post-operative complications.¹ Furthermore, it was shown that the diode was beneficial in reducing the pain (Walker et al. 1987).² All in all, the positive effects of the red diode have been scientifically proven for 30 years, as recent reviews have shown.^{2,3}

Some studies by Tina Karu, an internationally recognised leader in the science of laser phototherapy, even showed that LLLT improves ATP production as well as DNA + RNA synthesis in the mitochondria.⁴ A study from Franca CM (2009) demonstrated a positive effect of low intensity red laser (660 nm) by preventing an oral mucositis.⁵ Tacon KC (2011) observed a faster wound healing after using the 660 nm diode.⁶

I absolutely agree with that. In my opinion, wounds heal much faster and with fewer complications after using red laser light, and the wound area is cleaner with less scarring. The risk of intimal hyperplasia is reduced and my patients generally no longer require



Figs. 8a & b: The same patient, remains of root of tooth 23 in situ, X-ray of the remains of root of tooth 23.

Fig. 9: Extraction of the remains of the root of tooth 23. Pre-treatment: before removing the remains of the root of tooth 23, the patient was lased with 445 nm laser light (800 mW, 25 Hz, 50 % duty cycle circular) to remove the remaining tissue around the root and prevent greater damage to the surrounding tissue.

Fig. 10: This was followed by lasing using red laser light (LLLT) for biostimulation (Fig. 10).

Fig. 11: The clinical situation one day after surgery.

Fig. 12: The clinical situation two weeks after surgery Figs. 11 and 12 highlight the speed of healing.

painkillers after surgery/extraction. Accustomed oral hygiene practices can be restarted again sooner. The swelling that often follows tooth extraction has also become rare at my clinic.

Red laser light can generally be used in many ways. As early as the 1990s, scientific studies showed it produced good results with dentine hypersensitivity (for current data: Gärtner 2013).⁷ LLLT is also successful for use in conjunction with xerostomia because it stimulates the salivary glands while at the same time promoting their regeneration.

In implantology, using LLLT after surgery causes less swelling, infection and pain and can stimulate wound healing (Heinemann & Braun 2013).⁸ The only side effect that I have observed so far is a possible reddening of the treated area due to the stimulation of blood flow.

Practical case study

For a patient of mine, an elderly man aged 82 (high blood pressure, medication with anticoagulants, diabetes), I conducted LLLT for biostimulation and thus better wound healing following the extraction of teeth 12 and 23. I also used it to avoid possible complications that would constitute even greater stress for his body. The individual steps are as follows:

- Following the extraction of tooth 12, the wound was lased within the framework of LLLT for 60 seconds using the red diode (660 nm) at 100 mW dose 6J with an 8 mm probe at a distance of approximately 2 mm. Specifically, this meant lasing at 2J buccal and lingual in contact mode, occlusal at a distance of approx. 0.5 cm for 20 seconds on each side (Figs. 1-4).
- Figures 5, 6 and 7 show the rapid healing of the wound one day, one week and three weeks after surgery.

- Figure 8 shows the initial situation for the same patient with the remains of the root of tooth 23.
- Here, I conducted the following pre-treatment: Before removing the remains of the root of tooth 23, the patient was lased with 445 nm laser light (800 mW, 25 Hz, 50 % duty cycle circular) to remove the remaining tissue around the root and prevent greater damage to the surrounding tissue (Fig. 9).
- This was followed by lasing using red laser light (LLLT) for biostimulation (Fig. 10).
- Figures 11 (the following day) and 12 (two weeks after surgery) highlight how quickly the wound healed.

The wounds did not need to be sutured. The patient subsequently did not experience any swelling and painkillers did not need to be administered. The older patient reacted positively and was pleased with both the procedure and the outcome of the extractions. He was happy to have been pain-free.

Conclusions for practice

Diode lasers (e.g. SIROLaser Blue, made by Dentsply Sirona) are suitable not only for treating inflammatory periodontal diseases, of which about one-third of today's adults suffer, but laser therapy is also valued by patients and users alike in surgery and restorative dentistry (e.g. endodontics, dentine hypersensitivity or fissure sealing). The new SIROLaser Blue model combines three diodes (blue, red and infrared) for different applications, for instance for precise cutting in non-contact mode during surgical procedures (blue diode at 445 nm). I regularly use the red diode (660 nm) for its biostimulatory effect. It speeds the healing of wounds, reduces postoperative complications such as pain and swelling and can even remove the need to suture wounds in some situations. User-friendly default settings and a compact design facilitate efficient use in dental practice for the patient's benefit.

contact

Dr Talat Qadri
 Fjärdhundragatan 41 B
 74530 Enköping, Sweden
 Tel.: +46 17131261
 info@Kamidental.se

Author details



Literature

