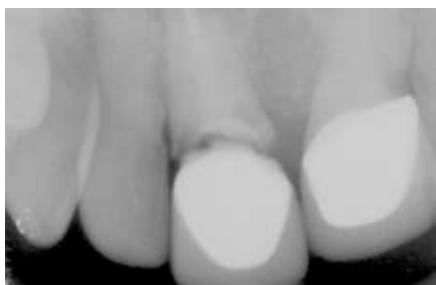
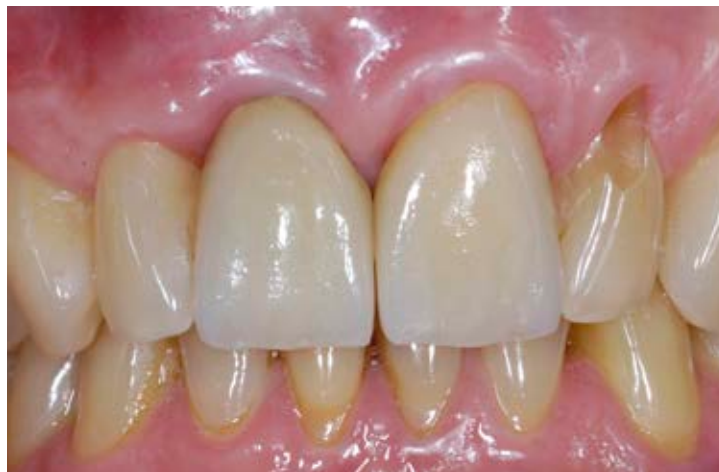


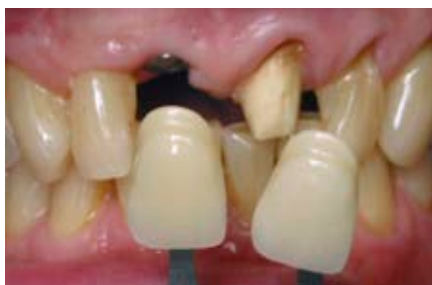**Dr. Julian Osorio, DDS**  
Private Practice Boston, MA, and Exeter, NH, USA  
Faculty, Graduate and Post Graduate Prosthodontics  
Tufts University School of Dental Medicine

## Precise and reliable abutment placement for longterm esthetic results

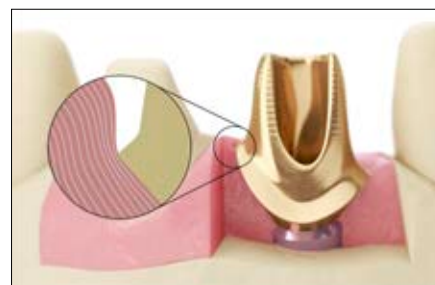
A 65-year-old male patient presented in the dental office with a fractured central incisor below tissue level. He requested an esthetic restoration that would not damage the adjacent tooth 12. Tooth 11 was extracted and the socket healed within 14 weeks. Four months after healing, an OsseoSpeed TX 3.5 S x 11 mm implant was placed. An Atlantis Abutment in gold-shaded titanium and an Atlantis Abutment Insertion Guide were designed and manufactured by Dentsply Sirona Implants. The abutment was placed four months after implant placement. The final restoration with two all-ceramic crowns on teeth 11 and 21 recreated a nice esthetic outcome, performed with a simple and reliable restorative handling procedure.



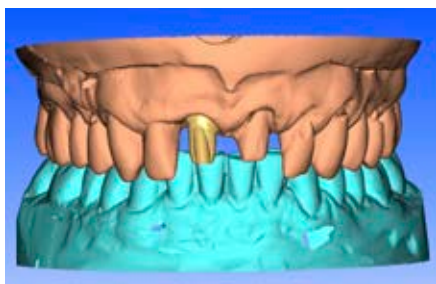
**1.** Radiological pretreatment situation. Horizontal tooth fracture on tooth 11 below tissue level.



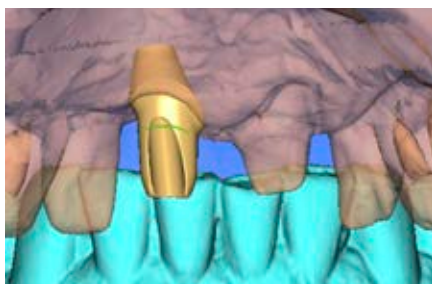
**2.** The tooth was extracted, and after healing, an OsseoSpeed TX 3.5 S x 11 mm implant was placed with a healing abutment. Final impression was taken and shade determined.



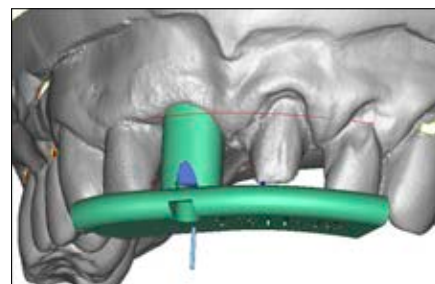
**3.** "Contour tissue" was the preferred emergence width option and selected in Atlantis WebOrder. The restorative margin was defined to be slightly subgingival. The image is used for communication purpose.



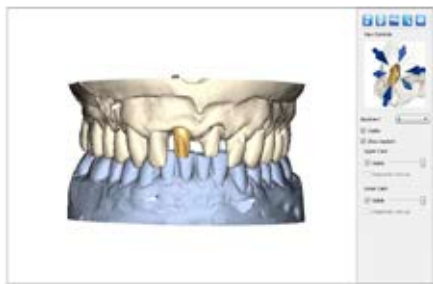**4.** The shape and form of the abutment was created using the proprietary Virtual Atlantis Design (VAD) software technology, which takes the specific edentulous space, surrounding teeth, and soft tissue anatomy into consideration.



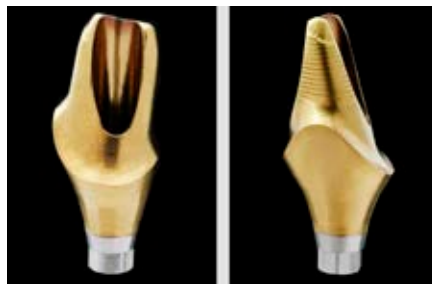**5.** The Atlantis Abutment was designed to support the soft tissue. The position of the margin was placed, allowing for easy removal of excess cement during cementation.



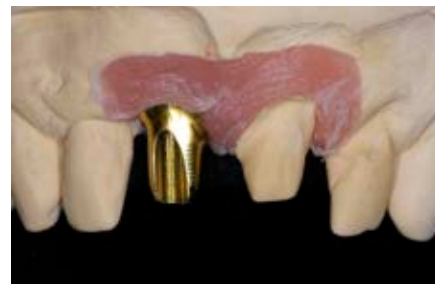**6.** An Atlantis Abutment Insertion Guide was created based on the Atlantis Abutment design file. The insertion guide uses adjacent teeth as an index and it accurately matches the abutment margin.



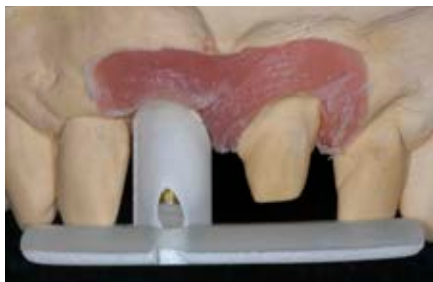**7.** The design of the abutment was reviewed and edited in Atlantis 3D Editor before the Atlantis Abutment and Atlantis Abutment Insertion Guide was approved for manufacturing.



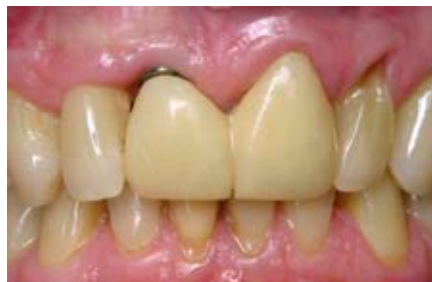**8.** The Atlantis Abutment was designed to meet the patient-specific requirements and customer preferences. Gold-shaded titanium was selected as the material to support an esthetic outcome of the final restoration.



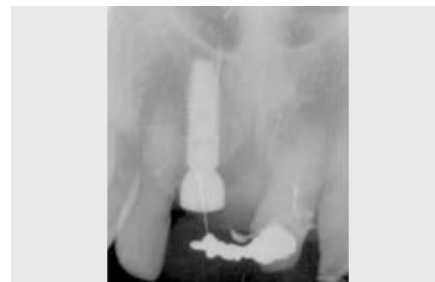**9.** The Atlantis Abutment was delivered to the dental laboratory and tried out on the master model.



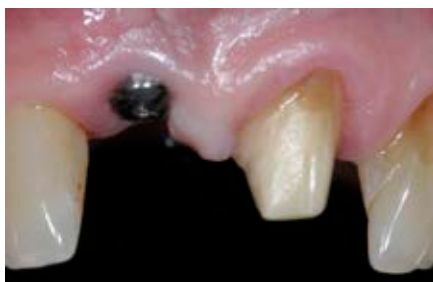**10.** Try-out of the Atlantis Abutment Insertion Guide on the master model. The insertion guide was used to securely hold the Atlantis Abutment at the correct angle and orientation during installation and torquing.



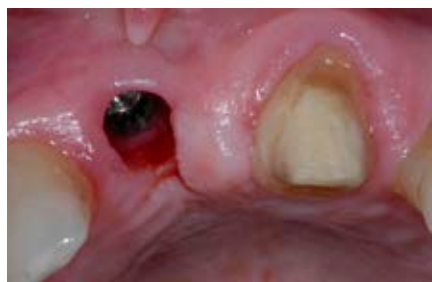**11.** When the patient returned to the clinic for placement of the patient-specific abutment, the metal reinforced acrylic temporary restoration supported on tooth 21 with a cantilever on 11 was removed.



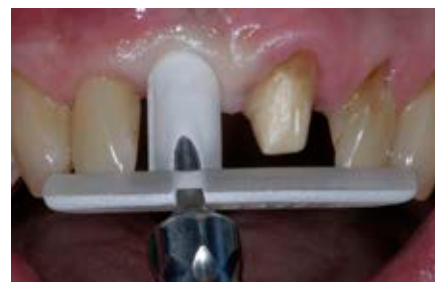**12.** X-ray of the implant and healing abutment as well as the metal reinforced framework.



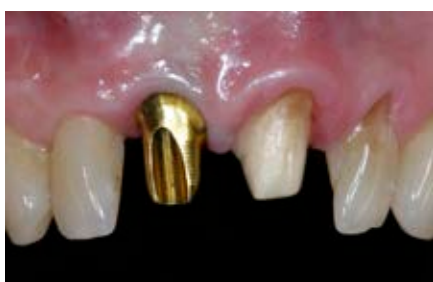**13.** Removal of the temporary restoration revealed healthy marginal gingiva around the healing abutment and the adjacent tooth 21.



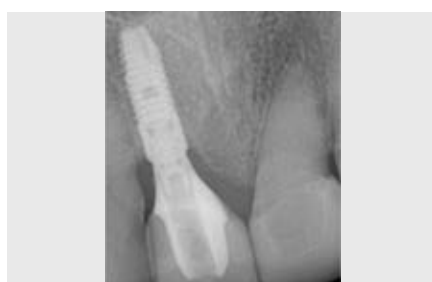**14.** Due to a solid connection and no movement of the abutment, the epithelial layer was affected when removing the healing abutment and a small amount of bleeding was seen.



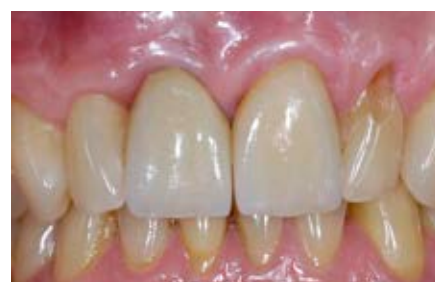**15.** The abutment was placed in the guide before installation to ensure proper seating. The Atlantis abutment screw was tightened with light finger force and finally torqued to 20 Ncm.



**16.** The Atlantis Abutment secured to the implant. The screw access hole was blocked and the case was ready for crown cementation.



**17.** X-ray of the implant – the Atlantis Abutment and the final crown.



**18.** The final patient-specific implant restoration at position 11 and final crown restoration cemented onto prepared tooth 21.