

3D-printed guide for implantology

Case Description

A 62-year-old male presented himself to my practice with a fractured non-restorable tooth #10. He had mild hypertension and elevated cholesterol, but no contra indications to implant therapy.

We decided that the best course of treatment was an extraction and a fixed bridge from #9-11 or single implant at site #10, an abutment and crown, as well as an implant. We obtained a 10×11 field of view CBCT using Axeos and took a digital impression by using Primescan AC. The future prosthetic crown was planned with CEREC SW 5.2 and exported into Sicut 2.0 with the CBCT. This let us plan the implant in the most ideal position, in relation to the bony walls and the future crown. We also planned a 4.2×13 PrimeTaper implant by exporting it out of Sicut 2.0, and into the CEREC chairside software. The surgical guide was planned using Primeprint and Primeprint Guide resin. The designed CEREC Guide 3 was exported for manufacture into inLab CAM Software 22.1. We positioned the guide on the building platform with proper supports in just one click! It took us 40 minutes to print the surgical guide with Primeprint. We placed it into the Primeprint PPU to be washed in isopropanol

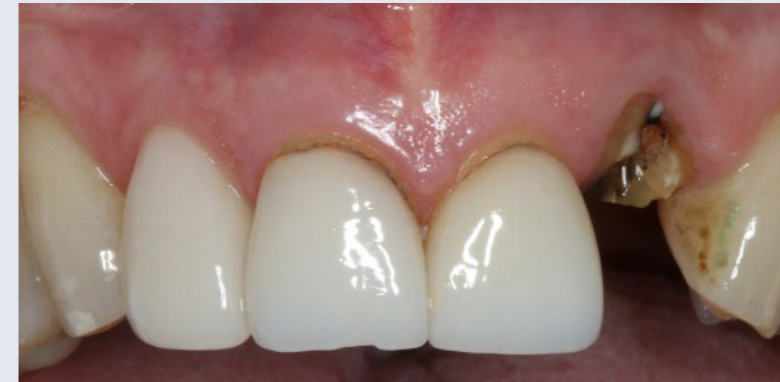and for photopolymerization. We removed the supports from the guide and bonded a narrow diameter (ND) sleeve that was compatible with the PrimeTaper surgical guide. We used the same Primescan AC model to design a temporary 1 wing Maryland bridge. The design was exported to in Lab CAM SW 22.1 and printed on Primeprint using Primeprint Temp A2 resin. It took us 30 minutes to print this bridge and process it in the PPU, so that it was ready for delivery at the time of surgery. On the day we anesthetized the patient with artecaine and extracted his tooth. We took great care to maintain the buccal plate. We positioned the 3D-printed surgical guide and performed the osteotomy through it. The site was irrigated, and we placed a 4.2×13 PrimeTaper implant through the surgical guide. The site was grafted using a mix of Symbios cortico/cancellous to graft the buccal gap, and place sutures. We printed a 1 wing Maryland Bridge ahead of the procedure, using A2 temporary resin and bonded it into place after finishing surgery. Surgery was completed in 20 minutes (including taking photos), and it took us 10 minutes to bond the temporary bridge.

Discussion

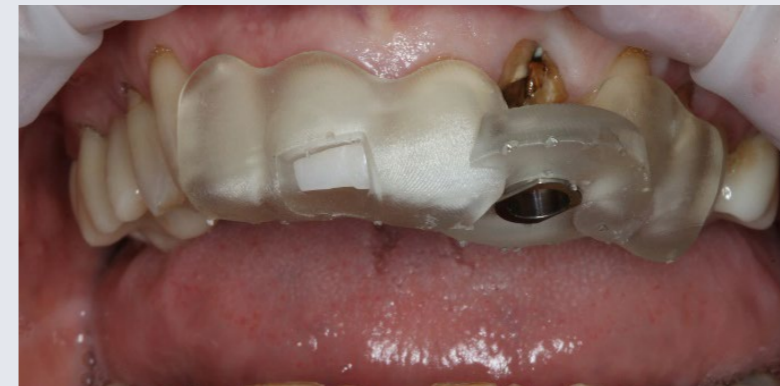When it comes to digital dentistry, Primescan AC and Primeprint are gamechangers. One of Primeprint's biggest advantages is that it can be used for single site or multiple site surgical guides. In this case, the surgical guide allowed for a placement that was seamless, stress-free and done with precision – even the patient was surprised at how quick the treatment was!



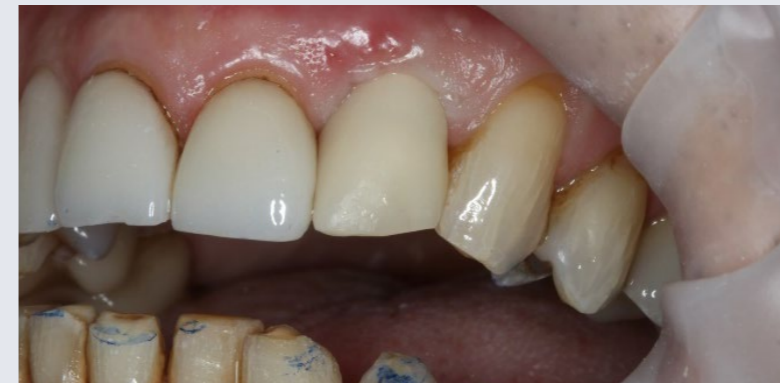Dr. Dan Butterman
Centennial, USA



Before: Initial situation with a fractured non-restorable tooth #10



Usage: Placing the surgical guide with optimal fit



After: Placing the 3D-printed One-wing-Maryland Bridge with Primeprint Temp material as a temporary restoration

Case Description in Pictures

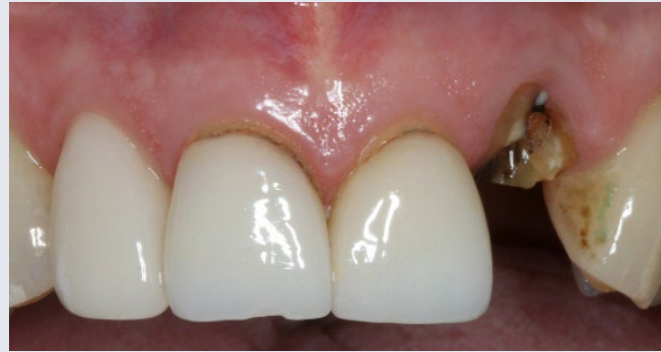

Fig. 1: Initial situation with a fractured non-restorable tooth #10

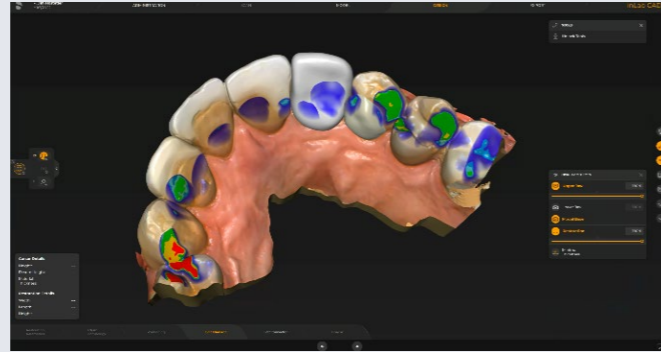


Fig. 2: Digital Model with prosthetic planning in inLab SW 22

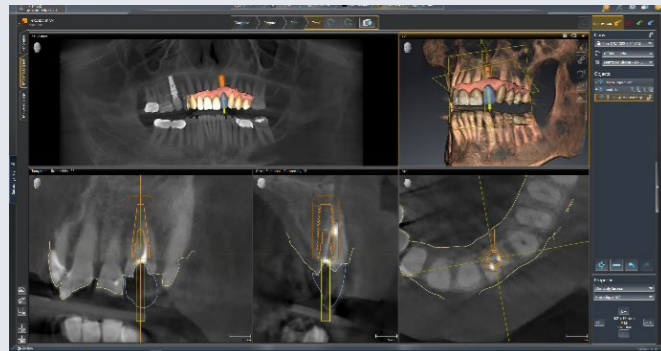


Fig. 3: Treatment planning in SICAT SW 2.0

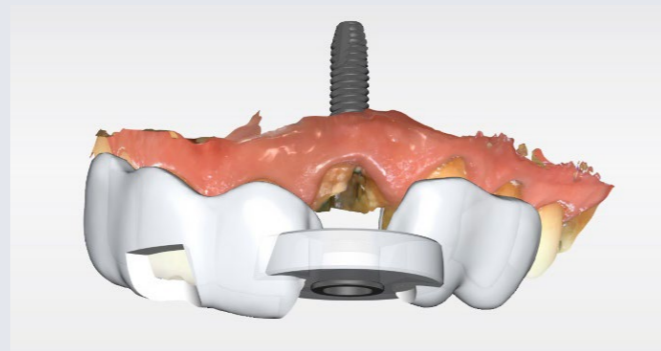


Fig. 4: Planning surgical guide CEREC Guide 3 in CEREC SW 5.2.3

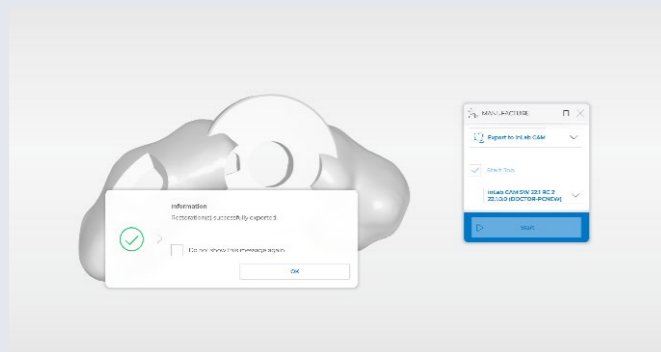


Fig. 5: Export of the file into the inLab CAM SW 22 for printing




Fig. 6: Splint positioned on Primeprint build plate with supports

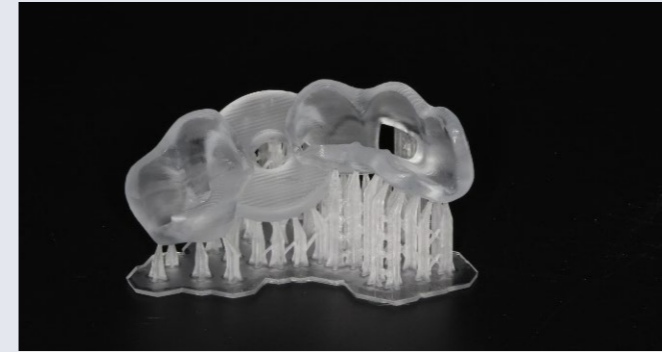

Fig. 7: 3D-printed guide with supports with Primeprint Guide material

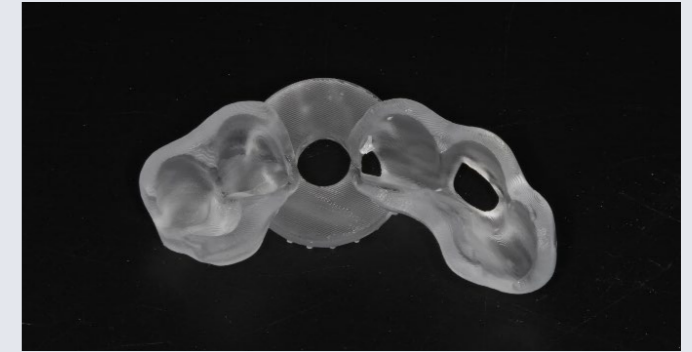


Fig. 8: The final 3D-printed surgical guide

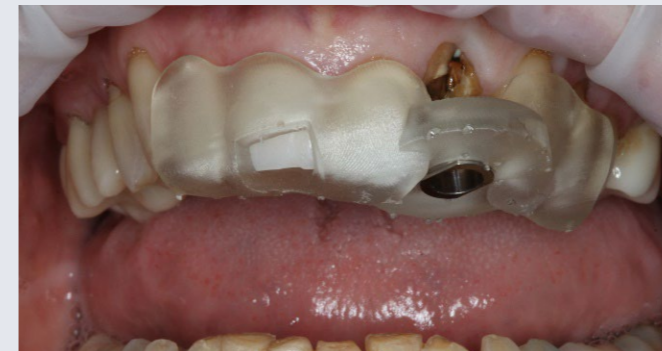

Fig. 9: Placing the surgical guide with optimal fit

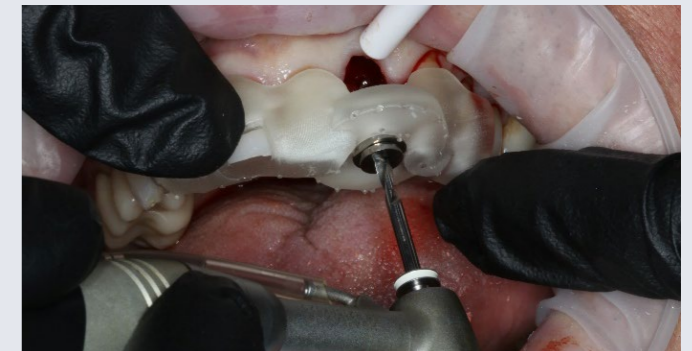

Fig. 10a: Osteotomy performed with guided surgical kit

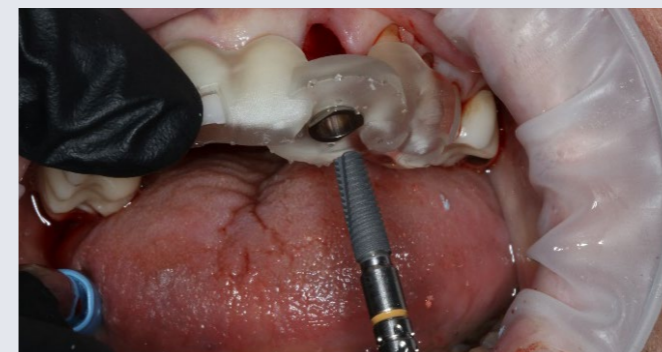

Fig. 10b: 4.2 X 13 PrimeTaper implant placed through the surgical guide

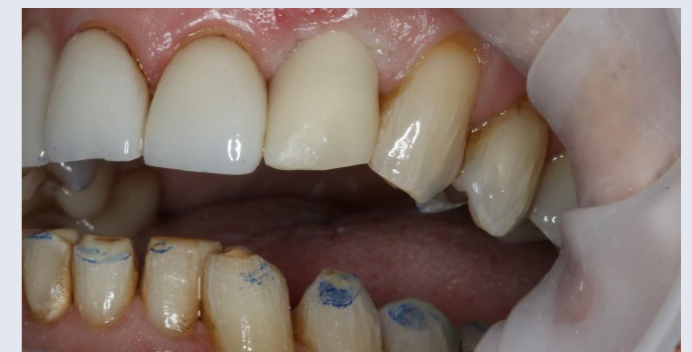

Fig. 11: Placing the 3D-printed One-wing-Maryland Bridge with Primeprint Temp material as a temporary restoration

