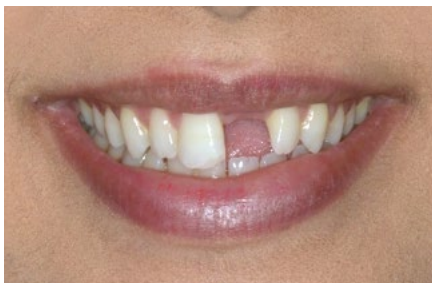
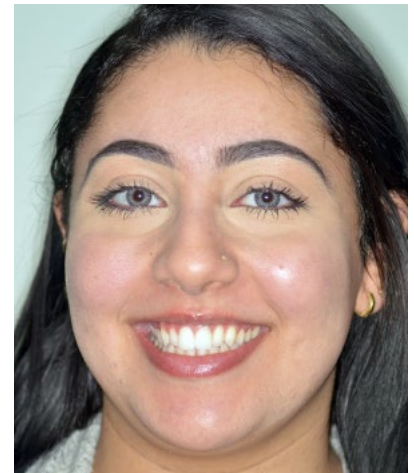


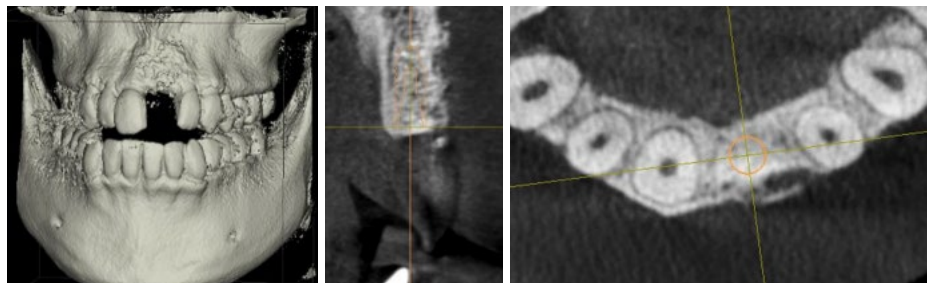
**Sarah Jockin, DDS**  
CERECseminarsLab.com  
Lutz, FL

**Single central maxillary incisor replacement with immediate loading protocol using Astra Tech Implant System® EV and Azento®**

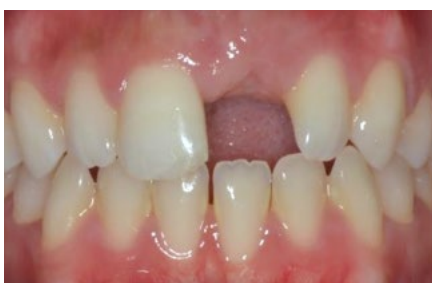A 19-year-old healthy female, who lost her upper incisor three years prior due to a trauma, presented with complaints of a missing upper left central incisor. The tooth was first treated with root canal therapy, but then extracted shortly thereafter. A socket graft procedure was performed by the provider at that time and the patient has been wearing an interim removable partial denture. She is about to leave for college and desires minimally invasive fixed tooth replacement. This case presented the ideal opportunity to use Azento, the complete digital implant solution for single-tooth replacement.



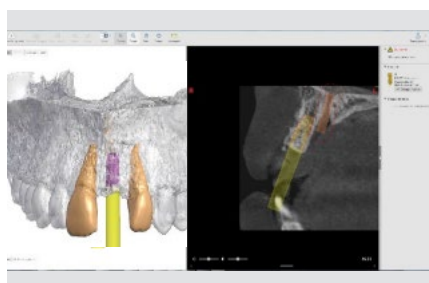
**1.** Pre-operative smile displaying gap. Tooth was lost three years prior due to trauma. A socket graft was placed and an interim removable partial denture fabricated.



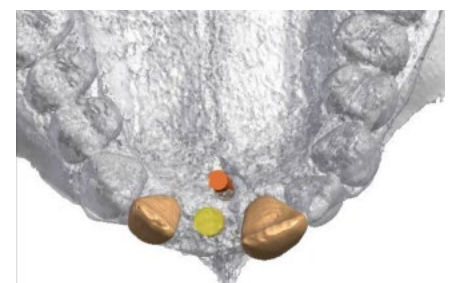
**2 a-c.** CBCT views reveal good maturity and volume of bone graft. It is suspected that a screw-retained prosthesis is feasible. Patient is highly motivated to complete treatment as she plans to leave for college in four months.



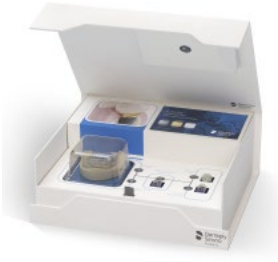**3.** Retracted view of edentulous space displaying soft tissue volume and quality. Patient has thin gingival biotype.



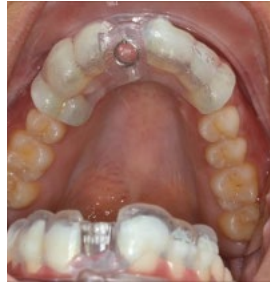**4.** Proposal for implant position in the Azento case viewer in both 2D and 3D.



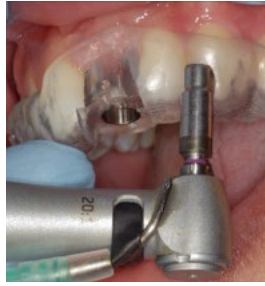**5.** Occlusal view of proposed implant position confirms emergence through the gingulum. Screw-retained prosthetic design is feasible.



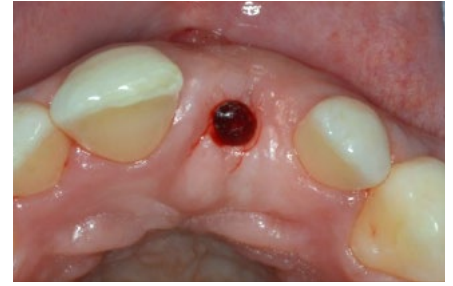**6.** Shown here, the contents of Azento: a patient-specific surgical guide on model, all drills, implant, custom healing abutment and final abutment with temporary crown.



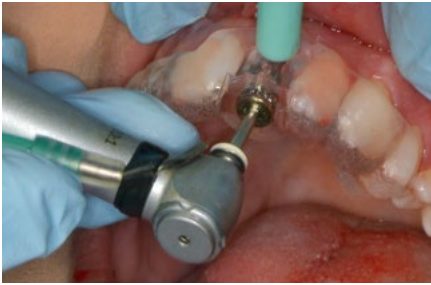**7.** Simplant SAFE Guide seated intraorally. Clear material and inspection window verify proper seating. Retention was present on guide.



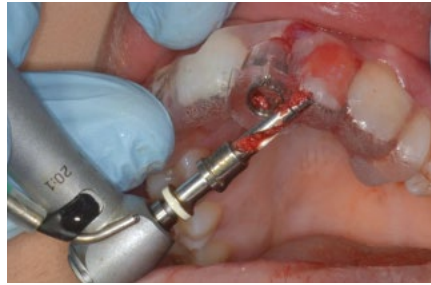**8.** Tissue punch protocol was employed as keratinized gingiva was present and elevation of a mucoperiosteal flap avoided.



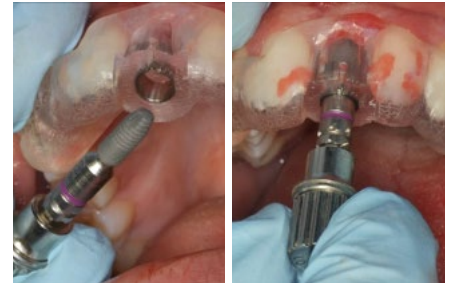
**9.** Presentation of ridge after tissue punch. Note the location of the emergence lingual to incisal edge position. This will allow for screw retained prosthetic protocol.



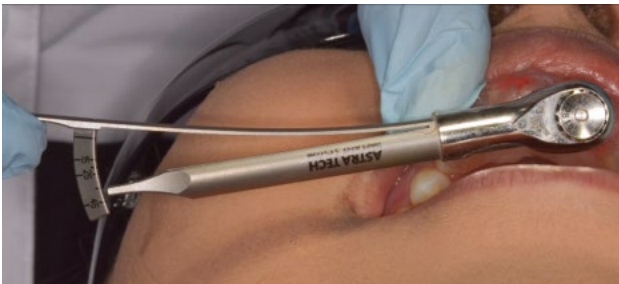**10.** Spongy bone preparation with step drills. Note the keyless workflow with the sleeve-on OsseoSpeed EV system drill.



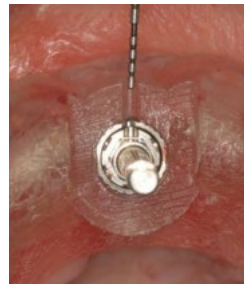**11.** Healthy bone was encountered during osteotomy prep. Tactile feedback resulted in choosing the A-Cortical Drill EV and V-Twist Drill EV.



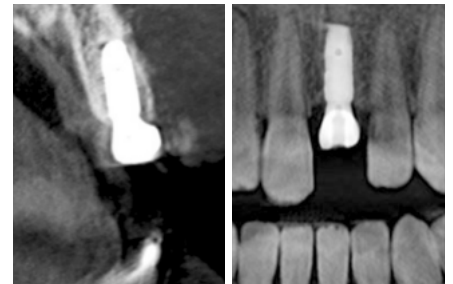**12 a-b.** Fully guided fixture insertion. The implant is seated in an aseptic manner with hand driver and then tightened to final depth with torque wrench.



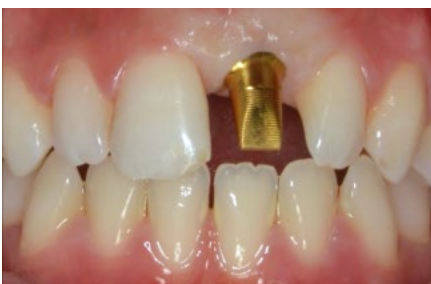**13.** Insertion torque measurement during final seating of implant fixture. Resistance of 40 Ncm was encountered with excellent primary stability. Immediate loading protocol was employed.



**14.** Proper timing of implant enables seating of restorative components



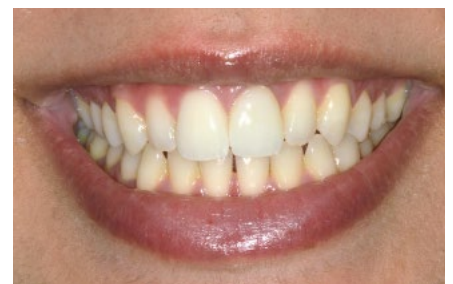**15 a-b.** Verification of correct fixture placement with post-op CBCT scan. A custom healing abutment (shown here) was available as backup.



**16.** The Atlantis Abutment, in gold-shaded titanium, seated in one-position-only and correct timing of fixture verified. The Atlantis Temporary Crown can be delivered cement or screw retained.



**17.** The Atlantis Temporary Crown and abutment are luted extra-orally for cement-free delivery. Occlusion is kept open in centric and excursive positions.



**18.** Tooth #8 veneered, #9 final crown on Atlantis abutment. The patient is very happy with the result.

This case report is published as an inspiration for you as a clinician and not necessarily as a recommendation from Dentsply Sirona.